Research Square

Preprints are preliminary reports that have not undergone peer review.
They should not be considered conclusive, used to inform clinical practice,
or referenced by the media as validated information.

Renal Regenerative Capacity Related to Stem Cell Reserve in Nephrectomized Rats

Songul ARABUL (songul_arabul@hotmail.com)
Akdeniz University Faculty of Medicine, Departments of Pediatric Surgery https://orcid.org/0000-0002-4665-9228
Mustafa MELIKOGLU
1Akdeniz University Faculty of Medicine, Departments of Pediatric Surgery https://orcid.org/0000-0001-9646-3787
Esma KIRIMLIOGLU
Akdeniz University Faculty of Medicine, Departments of Histology and Embryology https://orcid.org/0000-0002-5689-5670
Bezmi Cem BONEVAL
Akdeniz University Faculty of Medicine, Departments of Pediatric Surgery https://orcid.org/0000-0003-3435-9380
Gungor KARAGUZEL
Akdeniz University Faculty of Medicine, Departments of Pediatric Surgery https://orcid.org/0000-0002-7003-0876

Research Article

Keywords: Kidney regeneration, nephrectomy, stem cell, CD90, CD105, Ki-67

Posted Date: March 27th, 2023

DOI: https://doi.org/10.21203/rs.3.rs-2732002/v1

License: This work is licensed under a Creative Commons Attribution 4.0 International License. Read Full License

Abstract

Purpose: On the new era of stem cell therapy, the present experimental study was conducted to investigate renal regenerative capacity related to kidney stem cell reserve in different nephrectomy (Nx) models.

Methods: Three- and eight-week-old rats (n=168) were randomly divided into four groups to include control and three Nx subgroups (1/6 Nx, 1/2 Nx, and 5/6 Nx) (figure 1). On post-Nx days 15, 30 and 60, kidney specimens were obtained to determine renal regenerative capacity. The specimens were examined with immunofluorescence. CD90/CD105 and Ki-67 expressions were determined as stem cell and cellular proliferation markers, respectively.

Results: CD90 and CD105 expressions were stronger in glomeruli, but Ki-67 expressions were present only in tubuli. When all Nx types and post-Nx days were considered, both 3- and 8-week-old rats undergone 5/6 Nx had the highest glomerular CD90 and CD105 double expressions. While the expressions gradually increased toward the day 60 in 3-weeks old rats, 8-week-old rats had almost stable double expressions. The strongest tubular Ki-67 expressions were seen in 5/6 Nx groups of both in 3- and 8-week-old rats. The expressions were strongest on day 15 and then gradually decreased. Ipsilateral 1/6 Nx groups had stronger Ki-67 expression than contralateral ones in both age groups.

Conclusions: Kidneys may pose a regenerative response to tissue/volume loss through its own CD90- and CD105-related stem cell reserve which mainly takes place in glomeruli and seems to have some interactions with Ki-67-related tubular proliferative process. This response supports that kidney stem cells may have a potential to overcome tissue/volume loss-related damage.

Introduction

Renal failure caused by both urologic and nephrological problems leading to progressive and irreversible nephron losses is still a serious cause of childhood morbidity and mortality (1). Our current knowledge supports that none of the available treatments can neither restore kidney function nor stimulate new nephron formation in humans after permanent damage to the renal parenchyma (2, 3). However, with the development of tissue engineering and stem cell applications, cellular mechanisms of the nephron damage and kidney regeneration have begun to be reconsidered.

In contrast to low vertebrates, kidneys of advanced mammals do not have or very restricted regeneration capacity. Although current literature on kidney regeneration is very limited, few studies such as cell culture studies, biogenetical identification of certain transcription factors (Sall1-4 genes, GDNF, Six-2 genes, etc), searching cell surface markers/ immunophenotypes (CD34-, CD45-, CD90 +, CD105 +, HLA-DR), labelling of rare divided cells with 5-bromo-2-deoxyuridine (BrdU) or histone2B-green fluorescent fusion protein (H2B-GFP), etc. support that the kidney may have regeneration capacity (4–9). By using these techniques, potential stem cell reserves in renal glomeruli, tubuli and papillas have been demonstrated.

Many nephrological/urological diseases in childhood lead to renal parenchymal loss, posing a risk for renal failure (1, 10). However, it is unclear that how kidneys do response such volume/tissue loss. The aim of this experimental study was to investigate the effects of kidney volume/tissue loss which was performed through different nephrectomy (Nx) techniques, on stem cell-associated regenerative capacity of kidneys in rats.

Materials And Methods

Animals and Groups

Totally 168 Wistar albino male rats were used in our study (84 3-week-old pups and 84 8-week-old young adult rats).

The animals were divided into two main groups as control and Nx groups. Each main group included two subgroups regarding ages of the rats. Additional subgroups were designed to determine the relationship between type of the Nx and time elapsed after the Nx. Therefore, Nx groups were further divided into 3 subgroups as 1/6 Nx, 1/2 Nx and 5/6 Nx; and early-term (15th day), mid-term (30th day) and late-term (60th day) effects of Nx were studied in each subgroup. The subgroups of the controls contained 10 rats while the subgroups of the nephrectomized rats were arranged to include 6 rats (Table I).

Table 1
Main characteristics of control and nephrectomy (Nx) groups (certain specific subgroups were formed according to age, applied Nx technique and sacrification time).

CONTROL GROUPS (n = 60)		NEPHRECTOMY (Nx) GROUPS (n = 108)					
3-week-old rats (n = 30)	8-week-old rats (n = 30)	3-week-old rats (n = 54)			8-week-old rats (n = 54)		
		1/6 Nx (n = 18)	1/2 Nx (n = 18)	5/6 Nx (n = 18)	1/6 Nx (n = 18)	1/2 Nx (n = 18)	5/6 Nx (n = 18)
Sacrification on day 15 (n = 10)	Sacrification on day 15 (n = 10)	Sacrification on day 15 (n = 6)	Sacrification on day 15 (n = 6)	Sacrification on day 15 (n = 6)	Sacrification on day 15 (n = 6)	Sacrification on day 15 (n = 6)	Sacrification on day 15 (n = 6)
Sacrification on day 30 (n = 10)	Sacrification on day 30 (n = 10)	Sacrification on day 30 (n = 6)	Sacrification on day 30 (n = 6)	Sacrification on day 30 (n = 6)	Sacrification on day 30 (n = 6)	Sacrification on day 30 (n = 6)	Sacrification on day 30 (n = 6)
Sacrification on day 60 (n = 10)	Sacrification on day 60 (n = 10)	Sacrification on day 60 (n = 6)	Sacrification on day 60 (n = 6)	Sacrification on day 60 (n = 6)	Sacrification on day 60 (n = 6)	Sacrification on day 60 (n = 6)	Sacrification on day 60 (n = 6)

Anesthesia and Surgical Procedures

Analgesia/anesthesia was maintained by carprofen (Rimadyl®, 5 mg/kg, sc), ketamine (Ketasol®, 50 mg/kg, ip) and xylazine (Kepro®, 10 mg/kg, ip). In control groups, the kidneys were explored but no intervention was done to their vessels. In partial Nx groups, as described previously in the literature, the ligation (infarct) models that include tying and dividing of the associated renal arteries were used and shown in Fig. 1 (11, 12). All surgical procedures were performed using an operating microscope (Carl Zeiss®, Meditec AG).

1/6 Nephrectomy (1/6 Nx): Ligation was performed only in one of the ventral (caudal) polar branches of the renal artery feeding the right kidney.

1/2 Nephrectomy (1/2 Nx): All vessels supplying the right kidney were ligated and the kidney was totally excised.

5/6 Nephrectomy (5/6 Nx)L Both the ventral (caudal) and dorsal (cranial) polar branches of the left renal artery were ligated. Then, right Nx was performed.

At the end of the surgery, abdominal wall was closed in two layers (first layer: periton, muscle and fascia together; second layer: skin only). Water and feeding were allowed 3 hours after the surgery.

On sacrification days, all rats were undergone re-laparotomy under anesthesia. After sacrification by exsanguination, both kidneys were removed. The kidney specimens were fixed in 4% paraformaldehyde, washed in PBS (phosphate buffered saline), kept in a 20/100 sucrose solution, embedded into a cryomatrix (OCT; Sakura Finetek USA Inc.), and stored in liquid nitrogen until examination time. On examination day, 5 µm thick cryosections were taken with a cryomicrotome and immunofluorescence staining was performed immediately.

Histopathological Examination

Stem cell reserve and cellular proliferative response of kidneys were examined using certain fluorescence dyes (CD90, CD105 and Ki-67 antibodies) to elicit renal regenerative capacity. While CD90 and CD105 were used as markers of stem cell reserve, Ki-67 was used as marker of cellular proliferative response. Microscopic findings categorized simply as "negative" or "positive"

immunoreactivity/expression. Further comparisons of Nx groups for positivity against controls were graded as strong, stronger and strongest. All tissue sections were blindly examined by our histology team (one junior and one senior histologists) without knowing which section belongs to which group. In addition, both histologists were simultaneously evaluated all slides using a teaching ocular of the microscope. So, they categorized each rat's kidney specimens with consensus.

Immunofluorescence Staining with CD90 and CD105. Tissue samples were evaluated by double immunofluorescence staining method using antibodies. After the sections were drawn with hydrophobic pencil, they were washed 3 times with PBS for 5 minutes. The sections were then incubated with CD90 (Bioss bs-4609R) and CD105 (Invitrogen # MA1-80651) primary antibodies, without UV blocking and washing. Again, PBS was washed 3 times for 5 minutes, the anti-rabbit was incubated with the mixture prepared from AlexaFlour 488 secondary antibody (1/400, Invitrogen) and anti-mouse Texas Red (1/600, Invitrogen). Finally, samples washed 3 times with 5 minutes PBS were closed with DAPI and examined by fluorescence microscope.

Immunofluorescence Staining with Ki-67. To determine the cellular proliferative response, samples were stained with Ki-67 antibody. To do this, similar processes to CD90/CD105 immunofluorescence staining method were applied by using Ki-67 primary antibody (Invitrogen # PA5-19462).

Results

Overall mortality of Nx groups was 7.4% (8/108). No rat died in control groups. The rats which were died during experiment were replaced with new ones and the study could be completed as planned.

Histopathological Findings

All control groups had positive CD90, CD105 and Ki-67 expressions. While CD90 and CD105 expressions were stronger in glomeruli then tubuli and interstitium, Ki-67 expressions were present only in tubuli. The data including detailed comparisons of CD90, CD105 and Ki-67 expressions according to sacrification days (i.e. vertical comparisons) are explained in the following text. Whereas comparisons of the expressions according to Nx types (i.e. horizontal comparisons) are explained in the related figure legends.

CD90 and CD105 expressions in 3-week-old rats (Fig. 2). All 3-week-old rats including controls had CD90 and CD105 expressions mainly in glomeruli, less in tubuli and interstitium.

In 1/6 Nx group, contralateral kidneys showed strong glomerular CD90 expression, which was gradually increased from 15th day to 60th day. İpsilateral kidneys have also similar CD90 expression with less prominent on day 15. When compared with the 15th and 30th days, both ipsilateral and contralateral kidneys had the strongest and double (CD90 and CD105) expressions in glomeruli and interstitial cells on day 60.

In 1/2 Nx group, glomerular CD90 and tubular double (CD90 and CD105) expressions were stronger on day 30 than those of on days 15 and 60.

In 5/6 Nx group, glomerular CD90 and CD105 double expressions were gradually increased from day 15 to day 60. Tubular CD90 and interstitial double expressions were the strongest on day 60.

CD90 and CD105 expressions in 8-week-old rats (Fig. 3). Similar to 3-week-old rats, all 8-week-old rats including controls had CD90 and CD105 expressions mainly in glomeruli, less in tubuli and interstitium.

In 1/6 Nx group on days 15 and 30, there were strong CD90 expressions in glomeruli of ipsilateral kidneys. CD90 and CD105 double expressions were the strongest in glomeruli and interstitium on day 60. There was also stronger interstitial CD90 expression on day 60 than in other days. Contralateral kidneys had similar expressions to ipsilateral ones except presence of only CD90 expression on day 60.

In 1/2 Nx group, CD90 and 105 double expressions in glomeruli were stronger on days 15 and 30 than those of day 60. The strongest CD90, CD105 and double expressions were found in tubuli on day 30.

In 5/6 Nx group, there were strong CD90 and CD105 expressions in all days, but CD90 and CD105 double expressions were the strongest in glomeruli on day 30. While CD105 expressions in tubuli on days 15, 30 and 60 were comparable, CD90 expression was stronger on day 15.

Ki-67 expression in 3-week-old rats (Fig. 2). All 3-week-old rats including controls had tubular Ki-67 expression with no expression in glomeruli and interstitium.

In 1/6 Nx group, Ki-67 expressions in ipsilateral kidneys were stronger than in contralateral kidneys on days 15, 30 and 60. The strongest ipsilateral Ki-67 expression was determined on day 30. Contralateral Ki-67 expressions were stronger on days 30 and 60.

In 1/2 Nx group, Ki-67 expressions on days 15 and 30 were stronger than those of on day 60.

In 5/6 Nx group, there were strong Ki-67 expressions on days 15, 30 and 60. The strongest Ki-67 expression was determined on day 15 and then gradually decreased.

Ki-67 expression in 8-week-old rats (Fig. 3). Similar to 3-week-old rats, all 8-week-old rats including controls had tubular Ki-67 expression with no expression in glomeruli and interstitium.

In 1/6 Nx group, ipsilateral Ki-67 expression was stronger than in contralateral expressions on days 15, 30 and 60. Ipsilateral and contralateral Ki-67 expressions were stronger on days 15 and 30.

In 1/2 Nx group, there were strong Ki-67 expressions in all days with the strongest one on day 30.

In 5/6 Nx group, there were strong Ki-67 expressions in all days. The expression was strongest on day 15 and then gradually decreased as seen in 3-week-old rats.

All control and Nx groups had no glomerular Ki-67 expressions on days 15, 30 and 60.

Discussion

To date, many studies have been done to show whether a damaged kidney can regenerate in mammalian animal models, but they have been either unsuccessful or partially successful (4, 13). Kim et al. (14) reported that, in partially nephrectomized rats, renal tissue regeneration occurred 3 weeks after blood transfusion of fetal cells isolated from metanephrone at different weeks of gestation (14.5–20.5 weeks). Although new nephron formation has not been shown in mammals, it has been determined in lower vertebral bodies. Elger et al. (15) showed that partial Nx induces renal growth by accelerating nephrogenesis in *Leucoraja erinacea* fish as a study supporting kidney regeneration. In their study, a neonephrogenic zone, contains stem cell like cells that provides new nephron formation has been shown. This recovery is possible with a rapid proliferative response to repair itself after acute injury. However, it is not clear which stem cell reserve caused to such a response in the model mentioned.

Mammalian experimental models, aiming to examine regenerative capacity of the kidney, were generally designed to show the presence of stem cells in cortex and medulla as response of it to ischemia-reperfusion injury (16, 17). Whereas, in the present study, we adapted the previously described residual kidney model to define stem cell-related regenerative response of kidney against to volume loss. To date, no study has been reported to investigate regenerative potential of kidneys in different age groups by using different Nx techniques. We suggest that our experimental design can be used for further studies to investigate regenerative capacity of kidneys in multidirectional manner because it includes both minor and major kidney volume losses with a low mortality rate and enables specific evaluations which allow comparisons of ipsilateral and contralateral kidney regeneration processes. Furthermore such a design allowed us to obtain early/mid/late-term results of the experiment. However our study has some methodological limitations. First, since our study was primarily designed to explore regenerative response of kidneys against its own acute tissue/volume losses, it cannot give precise information about kidney regeneration following subacute or chronic renal parenchymal damages. Second, because our study included two types of nephrectomies (excisional

and vascular ligation/infarct models), such methodological difference may affect pathogenetical processes and regenerative responses.

Some studies suggest that tissue regeneration happens through division of differentiated cells (18, 19), while others reports that tubular epithelium acts as precursors of stem cells and functions in this way (18, 20). As cell surface markers of stem cells, CD90 (Thy-1) and CD105 (endoglin) have been studied to determine stem cell-related reserve in kidneys or other organs/tissues (5, 6). Bruno and Camussi (21) found that human glomeruli deprived of the Bowman's capsule contain a population of CD133 (-) plus CD146 (+) cells that coexpress the typical mesenchymal stem cells markers including also CD105. Response of differentiated tubular cells to the damaged kidney was suggested as proliferative, but neither slow nor fast cyclic stem cells were found in the classical stem cell cycle by continious application of a thymidine anolog for 7 days (22). Benjamin et al. (23) showed that there was no contribution of extratubular stem cells to renal repair after ischemic kidney injury. Kidney stem cell reserve which were shown by CD90 and CD105 double expression in the present study mainly takes place in glomeruli after 5/6 Nx and gradually increases from early period (day 15) to late one (day 60). These findings support that since the stem cell reserve associated with CD90 and CD105 is limited in the glomeruli, for complete nephron regeneration, there should be other stem cell reserves especially for the tubular/interstitial area. In addition, because the double expression is generally stronger in ipsilateral kidney and becomes stronger as volume loss increases, it can be suggested that CD90 and CD105-related stem cell reserve shows positive correlation with the side and severity of the damage.

Ki-67 is expressed during all phases of the cell cycle but not in quiescent G_0 cells. The Ki-67 antibody has been used repeatedly to assess cell proliferation in different types of tissue, organ or tumors to correlate its expression with the prognosis. It was reported that mammalian kidney regeneration may occur by surviving tubular epithelium after ischemic renal injury (23). Vogetseder et al. (22) have showed that tubular proliferation in the kidney takes place by proliferation of differentiated cells without any change in stem cells. In partial nephrectomized rats, Fine (24) showed occurrence of an adaptive hypertrophic growth in the kidney tissue that remained stable after the postoperative 7-10th day. These reports can be compared with our findings, which include the gradual reduction of Ki-67-related tubular proliferative/regenerative response from early period (day 15) to late one (day 60) after 5/6 Nx. This excessive proliferative response in tubuli is thought to result from its metabolically greater activity than the other nephron segments (25, 26). Generally, the expression was stronger in ipsilateral kidney and gets stronger as volume loss increases. On the other hand, although there was no new data to support their suggestion, Siderova et al. (27) showed proliferation of glomeruli after 1/2 Nx in rabbits in early postnatal period. Their findings do not match with ours, which include that the proliferative/regeneretive response is only in the tubules. Such studies with different results support that there are still many unanswered questions regarding stem cell-related kidney regeneration, despite significant advances on definition/identification of epithelial and mesenchymal stem cells in renal parenchyma.

Conclusion

Our study showed that rat kidney might pose a regenerative response to tissue/volume loss through its own CD90- and CD105-related stem cell reserve which mainly takes place in glomeruli and seems to have some interactions with Ki-67-related tubular proliferative/regenerative process. Additionally, occurrence of above-mentioned response stronger in ipsilateral side rather than contralateral one, as shown in 1/6 Nx group may indicate local/injury-specific activation of regenerative capacity. All those emphasize that stem cell reserve and proliferative response of the kidney may have a critical role for determination of regenerative capacity which is necessary to overcome tissue/volume loss-related kidney damages. Because our study ensures initial data about the subject, further studies are warranted to identify the exact role of kidney stem cells on renal regenerative process.

Declarations

Funding

This work was supported by The Scientific Research Projects Coordination Unit of Akdeniz University (Project No: TTU-2016-1555). We thank all staffs of the unit for their help and cooperation during the project.

Competing interests

The authors have no direct or indirect commercial financial incentive associated with publishing the manuscript, have no conflicts of interest associated with this publication. All material in this assignment is our own work and does not involve plagiarism.

Ethics Approval

This study was performed in line with the principles of the Declaration of Helsinki. This study was performed in Experimental Animals Laboratory of our institution with the permission of the Local Ethics Committee and EU Directive 2010/63/EU for animal experiments has been followed.

Authors' contribution

Songul ARABUL: Project development, Data collection and management, Manuscript writing and editing, Critical revision

Mustafa MELIKOGLU: Project conception and design, Critical revision

Esma KIRIMLIOGLU: Data analysis, Drafting of the manuscript

Cem BONEVAL: Drafting of the manuscript

Gungor KARAGUZEL: Project conception and design, Drafting of the manuscript, Critical revision

References

1. Jha V, Garcia- Garcia G, Iseki K, Li Z, Nacker S, Platter B, et al. Chronic kidney disease, global dimension and perspectives. Lancet 2013;382:260-72. https://doi.org/10.1016/S0140-6736(13)60687-x.
2. Yu YL, Shao YK, Ding YQ, Lin KZ, Chen B, Zhang HZ, et al. Decellularized kidney scaffold- mediated renal regeneration. Biomaterials 2014;35:6822-8. https://doi.org/10.1016/j.biomaterials.2014.04.074.
3. National Research Council (US) and Institute of Medicine (US) Committee on the Biological and Biomedical Applications of Stem Cell Research. Stem Cells and the Future of Regenerative Medicine, National Academy Press, Washington 2005;5(800): 624-42. QH587.S726 2001.
4. Franquesaa M, Flaquerb M, Cruzadob JM, Grinyo JM. Kidney regeneration and repair after transplantation. Curr Opin Organ Transplant 2013;18:191-6. https://doi.org/10.1097/MOT.0b013e32835f0771.
5. Barry FP, Boynton RE, Haynesworth S, Murphy JM, Zaia J. The monoclonal antibody SH-2, raised against human mesenchymal stem cells, recognizes an epitope on endoglin (CD105). Biochem Biophys Res Commun 1999;265:134–9. https://doi.org/10.1006/bbrc.1999.1620.
6. Keating A. Mesenchymal stromal cells. Current Opinion in Hematology 2006;13:419-25. https://doi.org/10.1097/01.moh.0000245697.54887.6f.
7. Oliver JA, Maarouf O, Cheema FH, Martens TP, Al-Awqati Q. The renal papilla is a niche for adult kidney stem cells. J Clin Invest 2004;114:795–804. https://doi.org/10.1172/JCI20921.
8. Maeshima A, Yamashita S, Nojima Y. Identification of renal progenitor like tubular cells that participate in the regeneration processes of the kidney. J Am Soc Nephrol 2003;14:3138–46. https://doi.org/10.1097/01.asn.0000098685.43700.28.
9. Nishinakamura R. Stem cells in the embryonic kidney. Kidney Int 2008;73:913-7.https://doi.org/10.1038/sj.ki.5002784.
10. Dozier KC, Yeung LY, Miranda MA Jr, Miraflor EJ, Strumwasser AM, Victorino GP. Death or dialysis? The risk of dialysis-dependent chronic renal failure after trauma nephrectomy. Am Surg. 2013;79:96-100. https://doi.org/10.1053/j.ackd.2016.01.014.
11. Kren S, Hostetter TH. The course of the remnant kidney model in mice. Kidney International 1999;56:333–7. https://doi.org/10.1046/j.1523-1755.1999.00527.x.

12. Al Banchaabouchi M, Marescau B, D'Hooge R, Van Marck E, Van Daela A, Levilain O, et al. Biochemical and histopathological changes in nephrectomized mice. Metabolism 1998;47:355–61. https://doi.org/10.1016/s0026-0495(98)90271-2.
13. Scott R, Sandeep G. Kidney regeneration and the role of stem cells. Organogenesis 2011;7:135-9. https://doi.org/10.4161/org.7.2.16285.
14. Kim SS, Gwak SJ, Han J, Park HJ, Park MH, Song KW, et al. Kidney tissue reconstruction by fetal kidney cell transplantation: effect of gestation stage of fetal kidney cells. Stem Cells 2007;25:1393-401. https://doi.org/10.1634/stemcells.2006-0183.
15. Elger M, Hentschel H, Litteral J, Wellner M, Kirsch T, Luft FC et al. Nephrogenesis is induced by partial nephrectomy in the elasmobranch Leucoraja erinacea. J Am Soc Nephrol 2003;14:1506-18. https://doi.org/10.1097/01.
16. Bussolati B, Tetta C, Camussi G. The contribution of adult stem cells to renal repair. Am J Nephrol 2008;28:813–822. https://doi.org/10.1159/000137681.
17. Liu H, Wu R, Jia RP, Zhong B, Zhu JG, Yu P, et al. Ischemic preconditioning increases endothelial progenitor cell number to attenuate partial nephrectomy induced ischemia / reperfusion injury. Plos One 2013;8:e55389. https://doi.org/10.1371/journal.pone.0055389.
18. Bonventre JV. Dedifferentiation and proliferation of surviving epithelial cells in acute renal failure. J Am Soc Nephrol 2003;14:55–61. https://doi.org/10.1097/01.asn.0000067652.51441.21.
19. Houghton DC, Hartnett M, Campbell-Boswell M, Porter G, Bennett W. A light and electron microscopic analysis of gentamicin nephrotoxicity in rats. Am J Pathol 1976;82:589–612. pmc2032419.
20. [20] Dekel B, Zangi L, Shezen E, Reich-Zeliger S, Eventov-Friedman S, Katchman H, et al. Isolation and characterization of nontubular sca-1_linmultipotent stem/progenitor cells from adult mouse kidney. J Am Soc. Nephrol 2006;17:3300–14. https://doi.org/10.3389/fmed.2018.00250
21. Bruno S, Camussi G. Isolation and characterization of stem cells in human glomeruli. Methods Mol Biol 2012;879:367–80. https://doi.org /10.1007/978-1-61779-815-3_22.
22. Vogetseder A, Picard N, Gaspert A, Walch M, Kaissling B, Hir ML. Proliferation capacity of the renal proximal tubule involves the bulk of differentiated epithelial cells. Am J Physiol Cell Physiol 2008;294:22–8. https://doi.org/10.1152/ajpcell.00227.2007.
23. Benjamin D, Humphreys M, Todd V, Akio K, Joshua WM, Savuth S, et al. Intrinsic Epithelial Cells Repair the Kidney after Injury. Cell Stem Cell 2008;2:284–91. https://doi.org/10.1016/j.stem.2008.01.014.
24. Fine L. The biology of renal hypertrophy. Kidney International 1986;29:619–34. https://doi.org/10.1038/ki.1986.45.
25. Ichimura T, Hung CC, Yang SA, Stevens JL, Bonventre JV. Kidney injury molecule-1: a tissue and urinary biomarker for nephrotoxicant induced renal injury. Am J Physiol Renal Physiol 2004;286:552–63. https://doi.org/10.1152/ajprenal.00285.2002.
26. Sabolic I. Common mechanisms in nephropathy induced by toxic metals. Nephron Physiol 2006;104:107–14. https://doi.org/10.1159/000095539.
27. Sidorova V. The postnatal growth and restoration of internal organs in vertebrates. Lakeland, TN: PSG Publishing Company Inc, 1978.

Figures

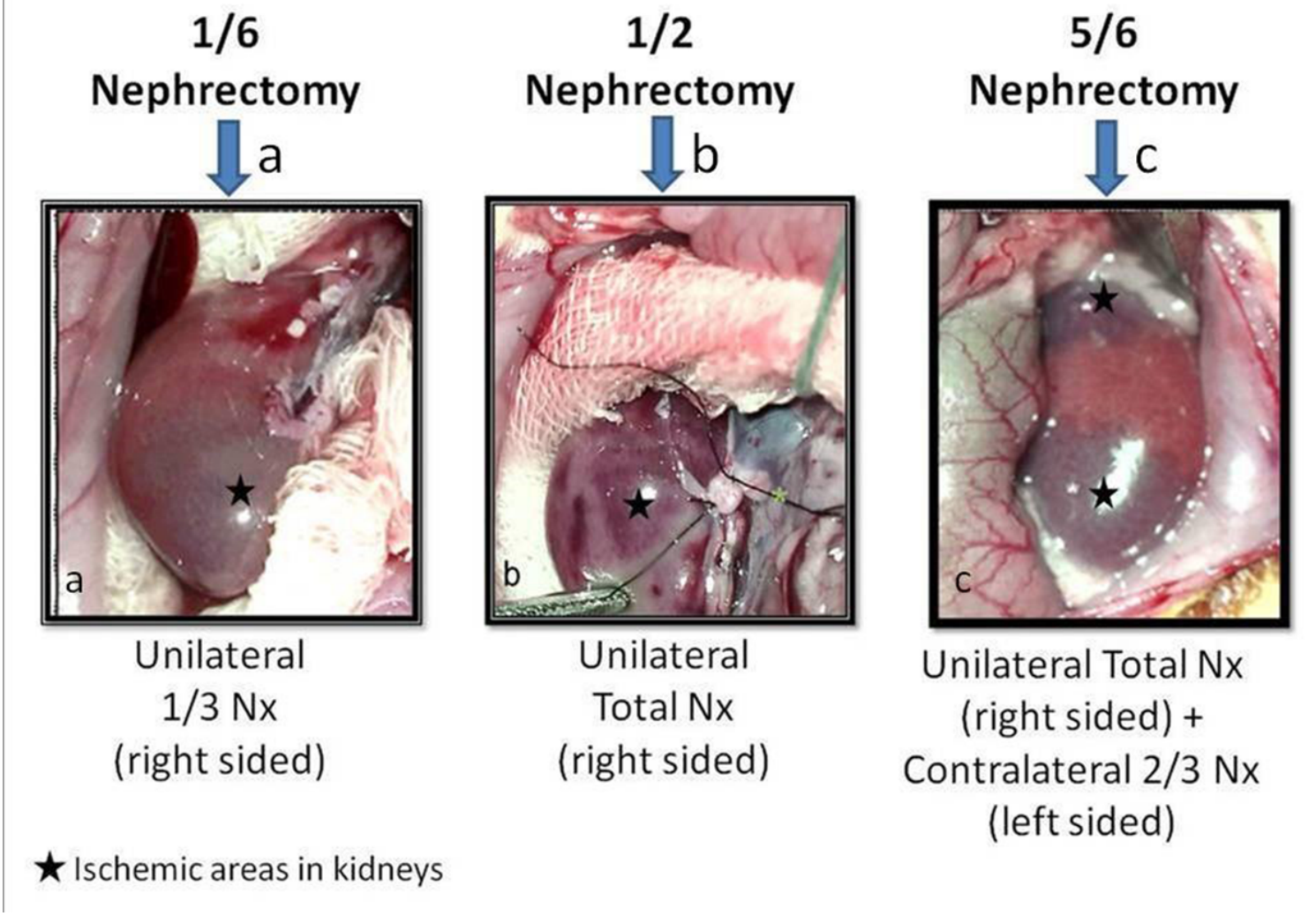

Figure 1

Intraoperative photographs showing three different types of nephrectomies (unilateral total Nx has not been shown in 5/6 Nx group).

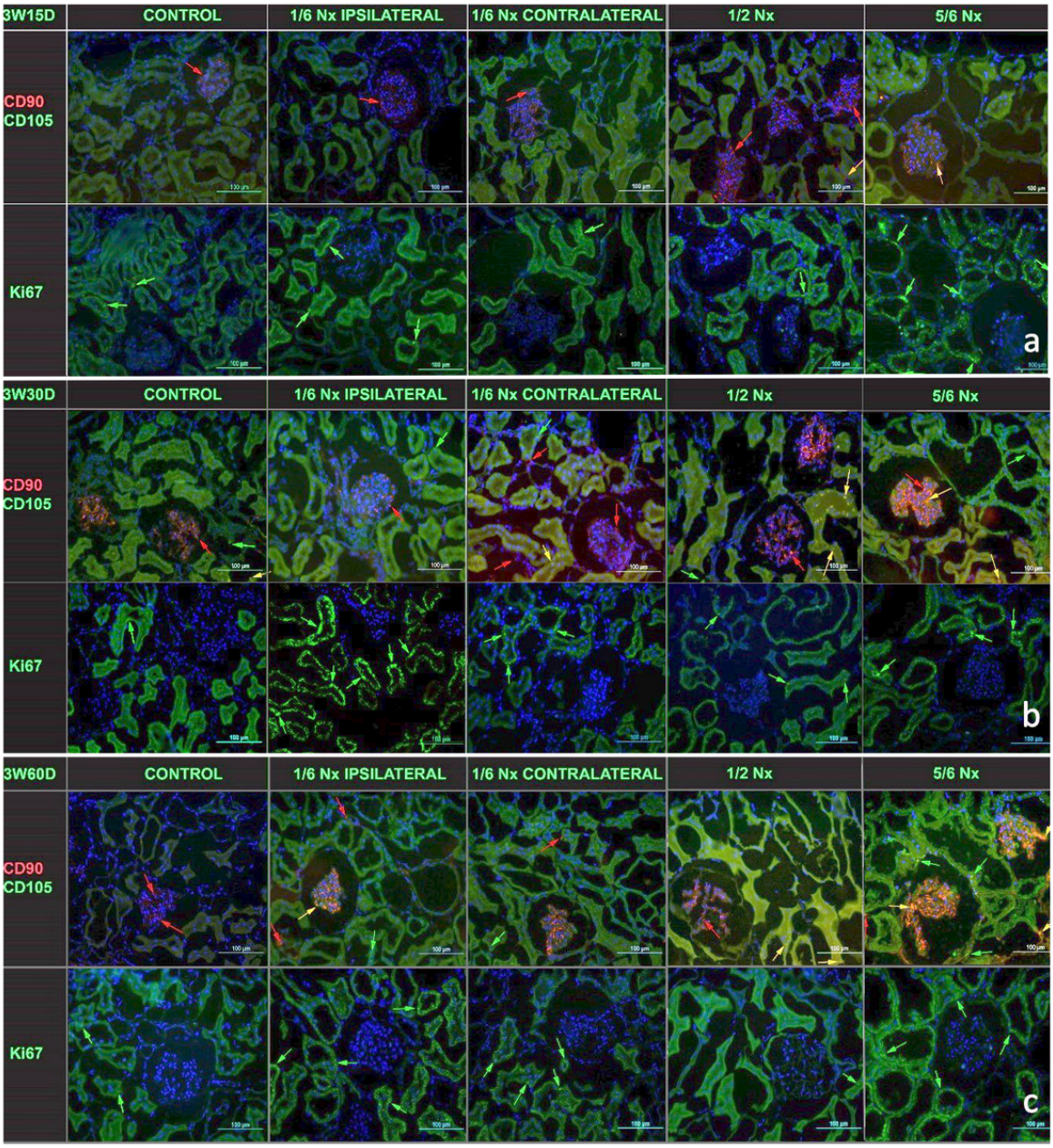

Figure 2

CD90, CD105 and Ki-67 expressions in 3-week-old rats. On day 15 (3W15D) as shown in Figure 1a, 5/6 Nx group had stronger glomerular CD90 expression (red arrows) when compared with other Nx groups. Glomerular CD90 and CD105 double expressions (yellow arrows) are the strongest in 5/6 Nx group. Ki-67 expression (green arrows) was observed only in tubuli and it is stronger in 5/6 Nx group than in other Nx groups. On day 30 (3W30D) as shown in Figure 1b, while there are CD90 expressions (red arrows) in both glomeruli and interstitium, CD105 expression (green arrows) is observed only in tubuli. When all groups are considered, CD90 and CD105 double expressions (yellow arrows) are the strongest in glomeruli of 5/6 Nx group. Ki-67 expression (green arrows) is observed only in tubuli. The expression is stronger in 5/6 Nx group and the strongest in 1/6 Nx (ipsilateral) group. On day 60 (3W60D) as shown in Figure 1c, CD90 (red arrows) and CD105 (green arrows) expressions are the strongest in glomeruli and tubuli, respectively. All Nx groups have strong CD90 and CD105 double expressions (yellow arrows) in glomeruli with the strongest one in 5/6 Nx group. Ki-67 expression (green arrows) is observed only in tubuli. 1/6 Nx (ipsilateral) and 5/6 Nx groups show stronger tubular Ki-67 expressions than in other Nx groups.

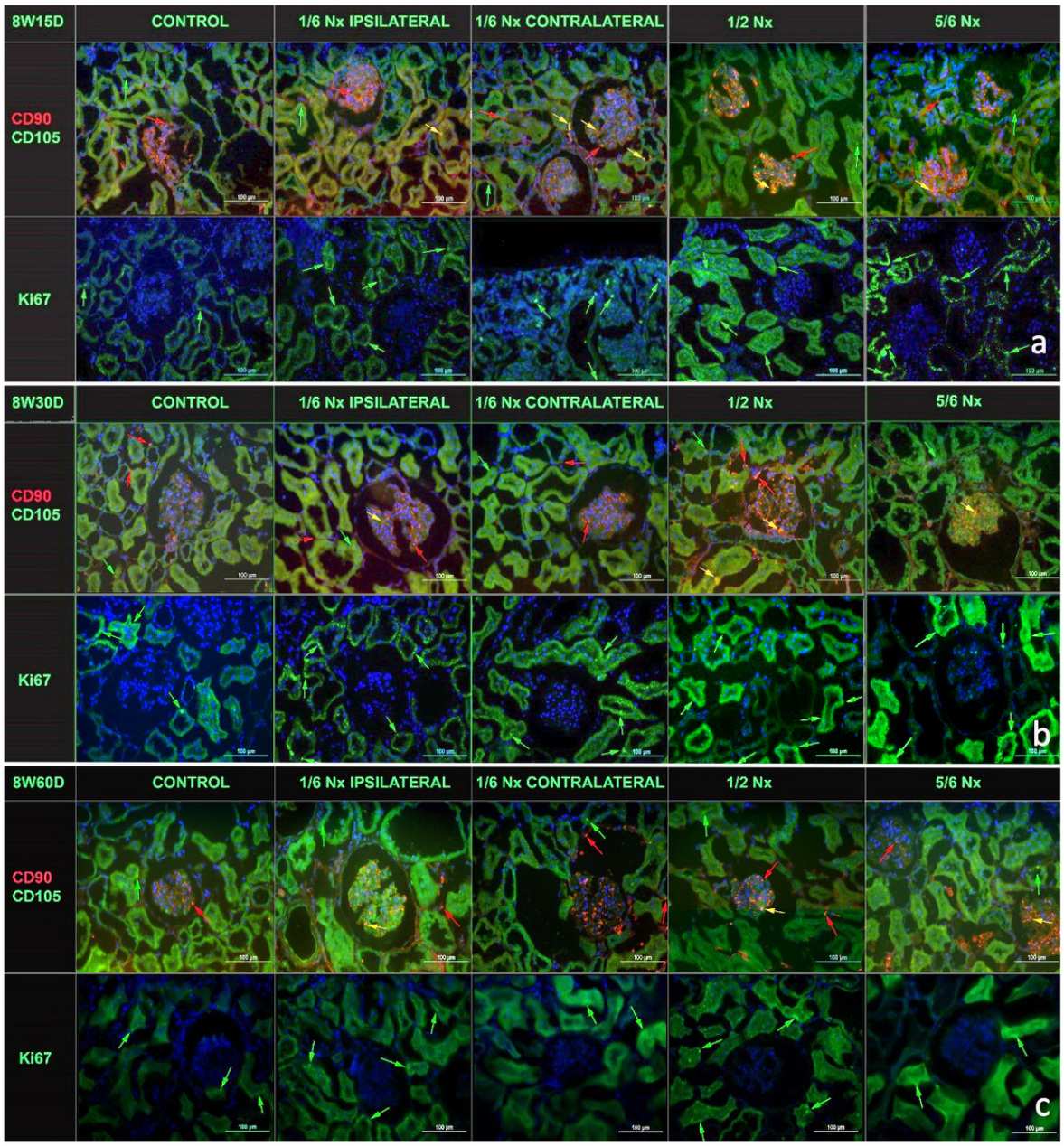

Figure 3

CD90, CD105 and Ki-67 expressions in 8-week-old rats. On day 15 (8W15D) as shown in Figure 2a, while CD90 (red arrows) is strongly expressed in glomeruli, CD105 (green arrows) is expressed in tubules. CD90 expressions (red arrows) in Nx groups are comparable with controls. Tubular CD90 and CD105 double expressions (yellow arrows) are stronger in 1/6 Nx group (ipsilateral), whereas glomerular double expressions are stronger in 5/6 Nx and 1/2 Nx groups. All Nx groups have stronger tubular Ki-67 expression (green arrows) than those of controls, with the strongest one in 5/6 Nx group. On 30 (8W30D) as shown in Figure 2b, While CD90 expression (red arrows) is observed in glomeruli and interstitium, CD105 expression (green arrows) is strongly expressed in tubuli. Glomerular CD90 and CD105 double expressions (yellow arrows) in 5/6 Nx group are stronger than in other Nx groups but tubular expression is stronger in 1/2 Nx group. Although tubular Ki-67 expressions (green arrows) in Nx groups are stronger than in controls, all Nx groups have similar Ki-67 expressions. On day 60 (8W60D) as shown in Figure 2c, while CD90 expression (red arrows) was stronger in glomeruli and interstitium, CD105 expression (green arrows) is stronger in tubuli. Glomerular CD90 and CD105 double expressions (yellow arrows) are stronger in 1/6 Nx (ipsilateral), 1/2 Nx and 5/6 Nx groups. Tubular Ki-67 expressions (green arrows) in Nx groups are stronger than in controls but all Nx groups have similar Ki-67 expressions