Renal Failure

ISSN: 0886-022X (Print) 1525-6049 (Online) Journal homepage: https://www.tandfonline.com/loi/irnf20

Acute renal failure due to uterine prolapse: a case report

Vural Taner Yılmaz, Ali Berkant Avcı, Ali Feyzullah Şahin, Hasan Bozkurt & Faruk Doğan

To cite this article: Vural Taner Yılmaz, Ali Berkant Avcı, Ali Feyzullah Şahin, Hasan Bozkurt & Faruk Doğan (2013) Acute renal failure due to uterine prolapse: a case report, Renal Failure, 35:6, 879-884, DOI: 10.3109/0886022X.2013.794705

To link to this article: https://doi.org/10.3109/0886022X.2013.794705

Published online: 28 May 2013.

Submit your article to this journal

Article views: 1026

View related articles

Citing articles: 1 View citing articles

Full Terms & Conditions of access and use can be found at
https://www.tandfonline.com/action/journalInformation?journalCode=irnf20

RENAL FAILURE

http://informahealthcare.com/rnf
ISSN: 0886-022X (print), 1525-6049 (electronic)

Ren Fail, 2013; 35(6): 879–884
© 2013 Informa Healthcare USA, Inc. DOI: 10.3109/0886022X.2013.794705

informa
healthcare

CASE REPORT

Acute renal failure due to uterine prolapse: a case report

Vural Taner Yılmaz[1], Ali Berkant Avcı[2], Ali Feyzullah Şahin[3], Hasan Bozkurt[4], and Faruk Doğan[3]

[1]Department of Internal Medicine, Division of Nephrology, Sivas Numune Hospital, Sivas, Turkey, [2]Department of Internal Medicine, Division of Rheumatology, Akdeniz University Medical School, Antalya, Turkey, [3]Department of Urology and [4]Department of Nuclear Medicine, Sivas Numune Hospital, Sivas, Turkey

Abstract

Herein, we present a successfully treated case with acute renal failure due to ureteral obstruction caused by total uterine prolapsed. A 55-year-old female patient presented to our hospital with the complaints of protrusion of the uterus for the last 3 months, pollakiuria, nocturia, decreased urine volume, and swelling of her body for the last week, and as well as impaired general status with shortness of breath for the last several days. Her physical examination revealed a blood pressure of 140/90 mmHg, pulse rate of 80 beats/min, body temperature of 37.8 °C, as well as uterine prolapse with infection and erosion on the surface of the uterus, crepitating rales in the basal segments of both lungs, and pretibial edema. Results of laboratory analyses were as follows: BUN = 70 mg/dL, Cr = 6.5 mg/dL, CRP = 8.7 mg/dL, and leukocyte = 12,000/mm^3. Blood gas analysis revealed a pH of 7.35 and bicarbonate level of 14 mmol/L. Data obtained from ultrasonography, DTPA scintigraphy, and abdominal CT, which were performed assuming that the patient had post-renal renal failure due to the compression by uterus, supported this assumption. Bilateral nephrostomy catheters were inserted and appropriate fluid-electrolyte therapy for volume status and antibiotherapy were commenced. Renal functions returned to normal levels on the 4th day of therapy and her complaints disappeared. The patient underwent total abdominal hysterectomy and was monitored in terms of renal functions and diuresis. The present case was presented due to its importance for being a quite rare case who dramatically responded to accurate intervention performed in time.

Keywords

Acute renal failure, nephrostomy, post-renal renal failure, ureteral obstruction, uterine prolapse

History

Received 5 February 2013
Revised 31 March 2013
Accepted 8 April 2013
Published online 28 May 2013

Introduction

Urological problems are one of the potential causes of acute renal failure. Problems causing obstruction in the urinary system are considered under the topic of post-renal renal failure. Problems that cause obstruction throughout the ureteral trace (mass pressure, urinary stone-related obstructions, strictures, surgical complications, stenosis or compression of ureteropelvic and ureterovesical junctions, tumor invasions, etc.), urine bladder tumors, and urethral obstructions consequently leads to post-renal renal failure. Acute renal failure due to obstruction after ureteral or urethral compression caused by uterine prolapse is a quite rarely encountered pathology among obstructive uropathies.[1,2] Damage caused by post-renal failure would be less with early and accurate approach to the problem and accordingly the improvement period will be shorter.

In a patient with extremely enlarged kidneys because of polycystic renal disease, total uterine prolapse was developed due to the compression of the kidneys on uterus and renal failure was improved after pushing the uterus manually into its place.[3] This condition is quite rare among the causes of post-renal renal failure. Thus, gynecological examination should certainly be performed in female patients with polycystic renal disease and with rapidly worsened renal functions. Unless total uterine prolapse is timely responded, acute renal failure, which is developed due to hydroureteronephrosis, might turn into chronic renal failure in time.[4–7] Such cases should be treated promptly to prevent the onset of permanent renal failure. Other causes of obstructive uropathies include urinary system injuries after obstetric, gynecologic and abdominal surgeries.[8] In such cases, reconstructive and corrective surgical procedures should be performed and renal damage should be prevented. The other rare form of urinary obstructions is non-dilated obstructive uropathies. They account for less than 5% of overall obstructive uropathies. Generally, the reason of non-dilated obstructive uropathies is retroperitoneal tumors and rarely uric acid stones.[9,10] Similar to the other pathologies, the approach to non-dilated obstructive uropathies should be prompt and appropriate in order to prevent renal damage. Decompression procedures (Foley catheter, ureteral stent, and percutaneous nephrostomy catheter) provide quite effective and definite outcomes.[11]

Address correspondence to Vural Taner Yılmaz, Department of Internal Medicine, Division of Nephrology, Sivas Numune Hospital, Sivas, Turkey. Tel.: 0 532 401 7079; E-mail: vuraltaneryl@yahoo.com.tr

Copyright Informa Healthcare 2013
Not for Sale/Commercial Distribution
Author-published version available for download, personal use and display on personal website. Not for redistribution, sale or commercial use. Copyright policy at Google Scholar

Herein, we presented a rare case with acute renal failure due to total uterine prolapse, who rapidly improved after inserting bilateral nephrostomy catheter.

Case report

A 55-year-old female patient (height:162 cm, weight:85 kg) had partially prolapsed uterus approximately for the last 3 months; whereas, completely prolapsed for the last month. She had been evaluated by gynecology and obstetrics department at an external center and given topical treatment. She complained about decreased urine volume, pollakiuria, nocturia, dyspnea, and swelling of the body for the last week. She presented to our hospital due to impaired general status. On her physical examination, general status was moderate, blood pressure (BP) was 140/90 mmHg, pulse rate (PR) was 80 beats/min, and body temperature was 37.8 °C. Moreover, crepitating rales in the basal segments of both lungs, bilateral extensive sibilant rhonchi in the lungs, prolonged expiration, occasional coarse rales, ++/++ pretibial edema, and totally prolapsed uterus (with infection and erosion on its surface) were detected. Laboratory results were as follows: BUN = 71 mg/dL, Cr = 6.5 mg/dL, Na = 141 mEq/L, K = 5.4 mEq/L, CRP = 8.7 mg/dL, and leukocyte = 12,000/mm^3. Blood gas analysis revealed a pH of 7.35 and a bicarbonate level of 14 mmol/L. The patient was hospitalized for further analysis and treatment. She had no concomitant disease except for schizophrenia and bronchial asthma. On her ultrasonographic examination; localization, parenchyma echogenicity, and thickness of the kidneys were normal; there was neither solid nor cystic lesion but minimal or moderate pelvocaliectasis in both kidneys (more prominent in the right). Abdominal tomography (sections 5 mm in thickness) revealed that both kidneys were normal in size as well as in parenchyma echogenicity and thickness, including no solid or cystic lesion, and that there was no extrarenal pathology. Dynamic renal scintigraphy with diuretic (DTPA), in which GFR measurement was performed via 40 min dynamic, static images and camera method through the posterior by selecting regions of interest of each kidneys following IV injection of 6 mCi Tc-99 m DTPA, showed a higher basal activity than expected due to low clearance. Perfusion and concentration functions were decreased in both kidneys, being more remarkable in the right. Hypoactive area was observed in the medial aspect of the right kidney during concentration phase, probably due to dilated pelvicaliceal structures. Nonetheless, no parenchymal thinning was observed. No remarkable excretion was observed in any of the kidneys in the excretion phase. Contribution to overall renal function was calculated to be 46% for the right kidney and 54% for the left kidney. GFR value measured by the camera method was interpreted as 36.5 mL/min (normalized GFR was 30.6 mL/min) (Figure 1a and b). With the suspicion of ureteral obstruction and post-renal acute renal failure development due to the compression of prolapsed uterus, bilateral nephrostomy catheters were inserted under ultrasonography guidance. After obtaining blood and urine cultures and IV fluid replacement with close monitoring of diuresis, empirical antibiotherapy, and bronchodilator therapy were commenced. Renal functions were monitored daily. The patient, who displayed polyuria during follow-up period, received IV 0.9% NaCl replacement at appropriate dose and under close monitoring. Renal functions returned to normal levels (BUN was decreased to 19 mg/dL from 71 mg/dL, serum Cr was decreased to 1 mg/dL from 6.5 mg/dL) within 4 days (Table 1). No growth was observed in blood and urine cultures. Palliative treatment was continued. Her general status improved and all other complaints disappeared. Antegrade pyelography revealed no transition of opaque substance from pelvis to ureter of the right kidney and from ureter of the left kidney to the bladder (Figure 2). Control DTPA scintigraphy revealed that perfusion, concentration, and excretion functions of both kidneys were significantly improved (almost normal) and that there was a passage from the right ureter to the bladder but the activity was low (Figure 3a and b). Based on these results, it was thought that the patient developed renal failure due to ureteral compression by prolapsed uterus and improved with appropriate monitoring and treatment. The patient was consulted with the gynecology and obstetrics clinic and the patient underwent total hysterectomy. Subsequently, urine drainage was observed throughout the Foley catheter and no drainage was detected throughout nephrostomy catheter. Nephrostomy catheter was clamped; no problem was observed during follow-up in terms of diuresis and renal functions (BUN = 16 mg/dL, Cr = 0.8 mg/dL). On intravenous pyelography, it was observed that opaque substance normally passed from each ureter to the urine bladder and filled the bladder (Figure 4). Nephrostomy catheters were removed; the patient monitored with stable renal functions, normal diuresis, and improved overall clinical picture.

Discussion

The present case, which developed bilateral ureteral obstruction and acute renal failure due to uterine prolapse and was treated in a short time with nephrostomy catheter and fluid replacement, was considered interesting and reported due to its being a quite rare case, as well as to demonstrate that obstructive nephropathies can be dramatically improved when treated in time and appropriately.

Urologic pathologies can cause both acute and chronic renal diseases. Although the frequency varies among age groups, common etiological factors include prostate hyperplasia, pathologies that cause ureteral obstruction, and malignancies in the advanced age groups, and vesicoureteral reflux, bladder dysfunction (including neurogenic bladder), and ureteropelvic junction obstructions in the childhood lead to renal disease. Comparing with other causes of renal failure, urological causes give dramatic response to timely and appropriate therapy. Although they are rare, urinary prolapses are usually encountered in the advanced age groups. Among overall prolapses, uterine prolapse usually leads to obstruction due to ureteral compression. Bladder is pushed downward by uterus compression, intraureteral pressure is increased due to tension, positional changes occur, lumen becomes narrow because of mucosal edema, and partial or total obstructions may develop. Uterus may lead to renal disease, even rare, by causing ureteral compression. In the present case, total uterine prolapse developed. Imaging methods, particularly antegrade

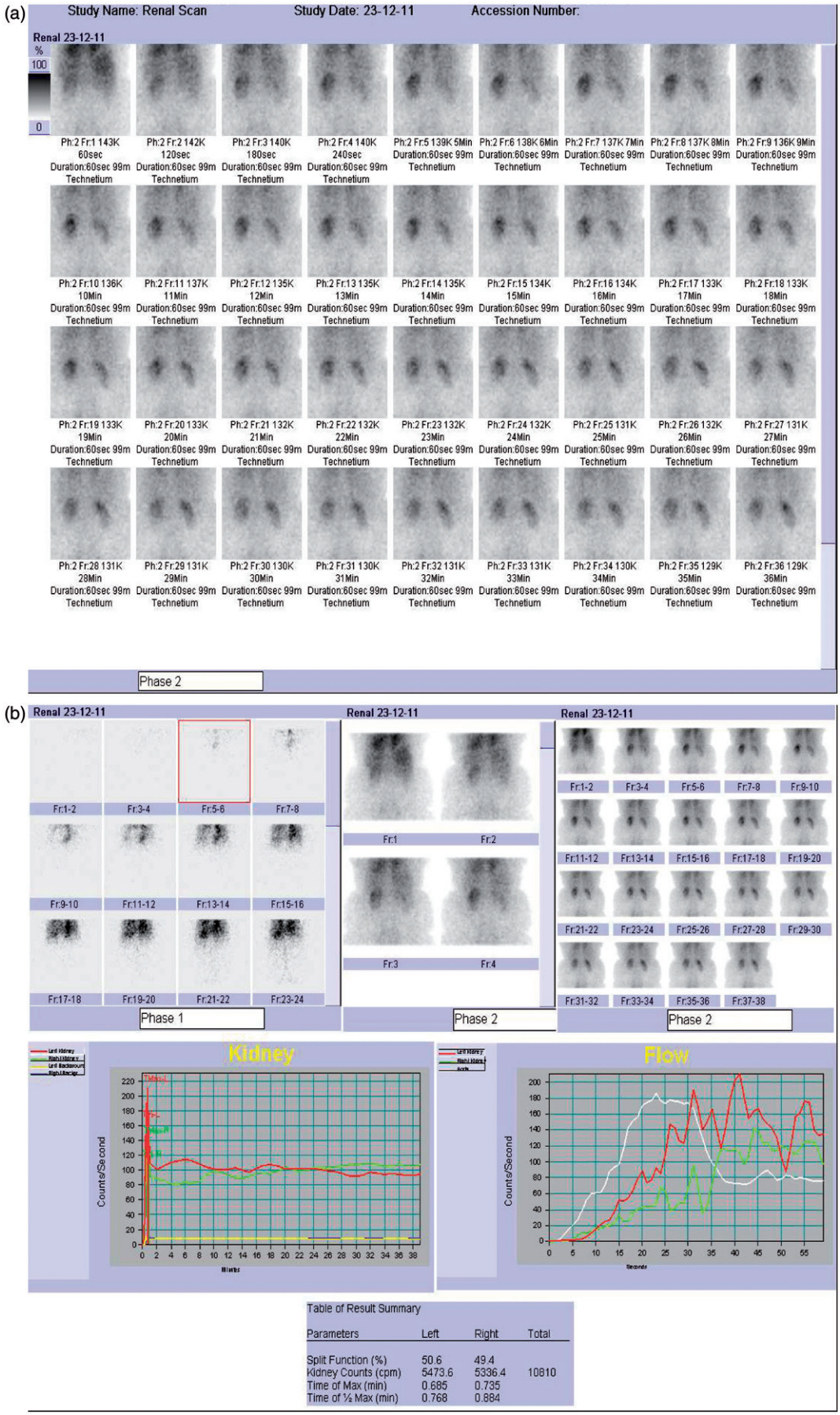

Figure 1. (a) DTPA (excretory phase): No remarkable excretion was observed in any of the kidneys. (b) DTPA (renogram phase): Perfusion and concentration functions were decreased in both kidneys, being more remarkable in the right. Nonetheless, no paranchymal thinning was observed.

Table 1. BUN, Cr, Na, and K serum levels and fluid intake (I) and urine output (O) before and after nephrostomy.

Parameter	23.12.2011	24.12.2011	25.12.2011	26.12.2011	27.12.2011	28.12.2011
BUN (mg/dL)	71	91	82	56	35	19
Cr (mg/dL)	6.5	5.9	5.1	2.8	1.7	1
Na (mEq/L)	141	139	145	146	148	146
K (mEq/L)	5.4	5.1	4.7	4.1	3.8	3.9
I/O	1500/400	4200/4500	4740/4040	7100/6240	5100/4700	4200/3800

BUN: blood urea nitrogen, Cr: creatinine, Na: sodium, K: potassium.



Figure 2. Antegrade pyelography revealed no transition of opaque substance from pelvis to ureter of the right kidney and from ureter of the left kidney to the bladder before hysterectomy.

pyelography, revealed signs of obstruction in the right ureteropelvic and left ureterovesical junctions. Opaque substance failed to pass under the above-mentioned levels indicating ureteral obstruction at these levels. This was supported by DTPA scintigraphy as well. The fact that renal functions returned to the normal levels in a short time after nephrostomy, indicated that obstructive nephropathies were dramatically improved with timely diagnosis and treatment.

Detailed etiological screening and exposing all likely causes are of great importance for prognosis in the cases that present with renal failure. Probability of multifactorial etiology should be kept in mind. In the present case, all etiological factors, which are likely to cause renal failure, were excluded depending on questioning of the present case, as well as on biochemical analyses and imaging methods. The reason was thought to be obstructive nephropathy caused by uterine prolapse, and the renal functions, which returned to the normal levels in a short time with treatment, confirmed this hypothesis. Ultrasonography revealing pelvocaliectasis that was more remarkable in the right, abdominal tomography revealing right pelvocaliectasis, DTPA scintigraphy revealing bilaterally decreased overall renal functions that were more remarkable in the right, and opaque substance's failing to pass down under the right ureteropelvic junction on the antegrade pyelography indicated that the obstruction was more prominent in the right side and was at the level of ureteropelvic junction. Likewise, absence of passage of opaque substance down under the left ureterovesical junction indicated that the obstruction was at this level. These results demonstrate that ureteral compression caused by uterine prolapse may occur at different levels of severity. Improved overall pathological signs on intravenous pyelography performed after hysterectomy also corroborated our thesis. Nevertheless, the present case is of great importance showing that patients with uterine prolapse should be examined for renal influence.

Increased intratubular pressure in obstructive uropathies affects glomerular functions and leads to renal failure by impairing concentration and particularly excretion functions of the kidney. In the beginning, DTPA scintigraphy of the present patient case demonstrated signs of chronic renal failure, whereas normal renal functions were observed after treatment. This finding is important in terms of showing that obstructive pathologies should be considered in elderly and uterine prolapse should be considered in women, who have signs of chronic damage on DTPA. Genital prolapses should also be considered in women with acute renal failure of unknown etiology, particularly in multiparous women, women with history for big baby and multi pregnancy and those with urinary incontinence, and they should be rapidly evaluated in this respect.

Decompression methods are quite beneficial and lifesaving in the treatment of obstructive nephropathies. Foley catheter was not inserted in the present case because of uterine prolapse and potential risks for complications and percutaneous nephrostomy catheter was inserted by considering that the obstruction might be at upper levels. Consequently, overall pathological signs were improved after this procedure and this result indicated that decompression is such an effective method in obstructive pathologies.[9] Without a doubt, definite solution is the removal of the cause. In the present case as well, first the renal functions was improved with palliative therapy and then definite solution was provided by hysterectomy. One of the important problems in such cases is post-obstructive diuresis and polyuria phase of acute renal failure. During this phase, fluid replacement therapy and diuresis should be monitored very closely and one should be on alert for dehydration or hypervolemia.

In conclusion, the present case, who developed acute renal failure due to bilateral ureteral compression at different levels caused by uterine prolapse and was treated successfully with

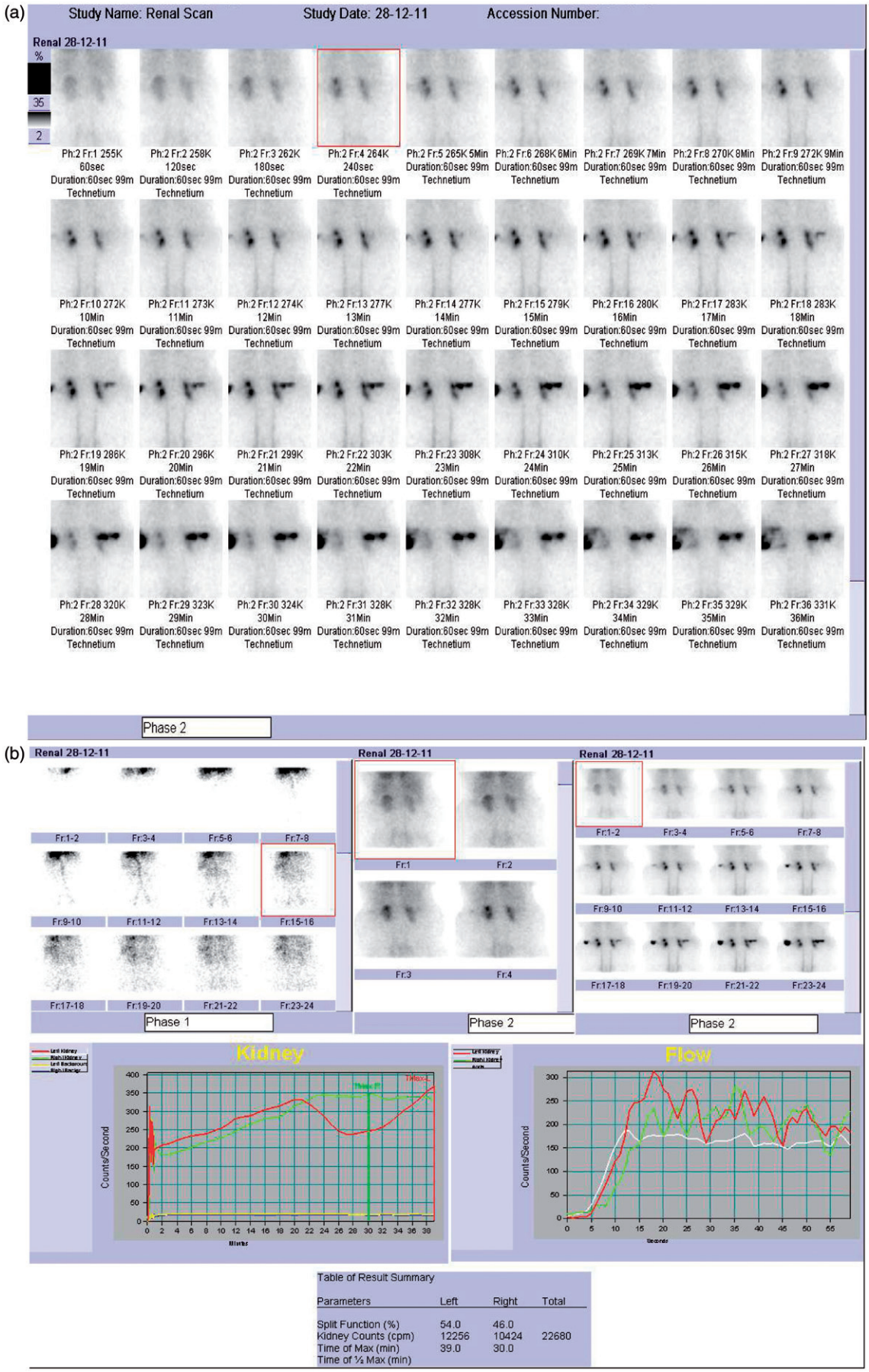

Figure 3. (a) DTPA (excretory phase, after normalization of renal function tests); significant improvement of excretion functions in both kidneys (almost normal) and that there was a passage from the right ureter to the bladder but the activity was low. (b) DTPA (renogram phase, after normalization of renal function tests); perfusion, concentration, and excretion functions of both kidneys were significantly improved (almost normal) and that there was a passage from the right ureter to the bladder but the activity was low.



Figure 4. On intravenous pyelography, it was observed that opaque substance normally passed from each ureter to the urine bladder and filled the bladder (nephrostomy catheter was clamped).

decompression method (percutaneous nephrostomy), was presented both to attract attention to this subject and to show the importance of timely intervention.

Declaration of interest

The authors report no declaration of interest.

References

1. Guérin C, Héritier P, Sabatier JC, Berthoux F. Renal insufficiency and severe genital prolapse: 2 cases. *J Gynecol Obstet Biol Reprod (Paris).* 1988;17(4):507–510.
2. Vírseda-Chamorro M, Gómez-Rodríguez A, Salinas-Casado J, Esteban-Fuertes M, López AM. Study of the influence of pelvic prolapse in the lower urinary tract micturition phase in the female. *Actas Urol Esp.* 2012;36(9):532–538.
3. Alexander JL, Rustom R, Bone JM. Acute renal failure from complete uterine prolapse: role of polycystic kidney disease. *Clin Nephrol.* 2003;60(2):143–145.
4. Peces R, Canora J, Venegas JL. Chronic renal failure secondary to uterine prolapse. *Nefrologia.* 2005;25(2):191–194.
5. Arriba de la Fuente G, Pérez Baviera MJ, García Martín F, et al. Acute renal failure of obstructive etiology caused by uterine prolapse. *Actas Urol Esp.* 1991;15(1):82–85.
6. Bae EJ, Kang Y, Seo JW, et al. Obstructive uropathy by total uterine prolapse leading to end-stage renal disease. *Ren Fail.* 2012; 34(6):807–809.
7. Yanik FF, Akpolat T, Koçak I. Acute renal failure – an unusual consequence of uterine prolapse. *Nephrol Dial Transplant.* 1998; 13(10):2648–2650.
8. Dovlatian AA. Reconstructive-reparative operations in injuries of the urinary tract in obstetrical, gynecologic and abdominal surgery. *Urologiia.* 2002;Nov–Dec(6):19–26.
9. Charasse C, Camus C, Darnault P, et al. Acute nondilated anuric obstructive nephropathy on echography: difficult diagnosis in the intensive care unit. *Intensive Care Med.* 1991;17(7):387–391.
10. Somerville CA, Chmiel R, Niall JF, Murphy BF. Non-dilated urinary tract obstruction. *Med J Aust.* 1992;156(10):721–723.
11. Onuigbo MA, Lawrence K, Onuigbo NT. Non-dilated obstructive uropathy – an unrecognized cause of acute renal failure in hospitalized US patients: three case reports seen over 6 months in a northwestern Wisconsin nephrology practice. *Ren Fail.* 2010; 32(10):1226–1229.