DOI: 10.14744/etd.2021.86143

Manuscript Type: Case Report

Title: The Unusual Nerve Compression Seconder to the Intramuscular Lipoma: A Case Report

Running Title: The intramuscular lipoma: A case report

Authors: Eren ÖĞÜT[1*], Fatoş Belgin YILDIRIM[2], Umut ÖZSOY[2], Aydın YILDIRIM[3]

Institutions: [1]Department of Anatomy, School of Medicine, Bahcesehir University, Istanbul, Turkey
[2]Department of Anatomy, School of Medicine, Akdeniz University, Antalya, Turkey
[3]Department of Orthopaedics and Traumatology, Manavgat Private Medical Center, Antalya, Turkey

Address for Correspondence: Eren ÖĞÜT. Department of Anatomy, Bahçeşehir University, Faculty of Medicine, 34734 İstanbul, Turkey

E-mail: eren.ogut@med.bau.edu.tr

Cite this article as: Öğüt E, Yıldırım FB, Özsoy U, Yıldırım A. The Unusual Nerve Compression Seconder to the Intramuscular Lipoma: A Case Report. Erciyes Med J 2021; DOI: 10.14744/etd.2021.86143.

UNCORRECTED

This article has been accepted for publication and undergone full peer review but has not been through the copyediting, typesetting, pagination and proofreading process, which may lead to differences between this version and the Version of Record. Please cite this article as: Öğüt E, Yıldırım FB, Özsoy U, Yıldırım A. The Unusual Nerve Compression Seconder to the Intramuscular Lipoma: A Case Report. Erciyes Med J 2021; DOI: 10.14744/etd.2021.86143.
©Copyright 2021 by Erciyes University Faculty of Medicine - Available online at: www.erciyesmedj.com

Abstract

Background: This report presents the case of a 68-year-old male patient with a three-month history of progressive weakness of the left hand with symptoms of pain and dysesthesias radiating to the dorsal aspect of the forearm.

Case: Complete compression of the radial nerve and partial entrapment of the ulnar nerve secondary to the intermuscular lipoma were detected. Electromyography (EMG) findings revealed prolonged motor and sensory latency of the radial nerve and reduced sensory conduction velocity (SCV) in the distribution of the ulnar nerve. The pathological findings revealed nuclear atypia, and there was no increased mitosis, hyperchromasia, pleomorphism, and multinucleation of fat cells. The patient underwent total surgical excision of the intermuscular lipoma with anterior surgical approach. The optimal functional improvement was reached in hand extension at one year follow-up.

Conclusion: The clinicians should consider the entrapment of adjacent peripheral nerves by an intermuscular lipoma and its clinical and pathological manifestations.

Keywords: Intermuscular lipoma, radial nerve, ulnar nerve, neuropathy, entrapment

UNCOR

Introduction

Lipomas are the most frequent benign mesenchymal adipose tissue tumors under the enclosing fascia (1). However, a minority of lipomas may be in deeper locations, including the intramuscular, intermuscular, intrathoracic and retroperitoneal regions (1). Intermuscular lipomas can involve both tissues deep inside the muscle and tissue between the muscles and their frequency among all benign adipocytic tumors are 0.3–1.9%. Pain is a late and rare

This article has been accepted for publication and undergone full peer review but has not been through the copyediting, typesetting, pagination and proofreading process, which may lead to differences between this version and the Version of Record. Please cite this article as: Öğüt E, Yıldırım FB, Özsoy U, Yıldırım A. The Unusual Nerve Compression Seconder to the Intramuscular Lipoma: A Case Report. Erciyes Med J 2021; DOI: 10.14744/etd.2021.86143.

©Copyright 2021 by Erciyes University Faculty of Medicine - Available online at: www.erciyesmedj.com

symptom, usually seen in deep-seated lipomas, and is most likely due to compression of the adjacent soft tissues, entrapment of the adjacent peripheral nerves or neurological deficits due to nerve impingement (1). The compressive syndromes of the peripheral nerves can be difficult to diagnose, affecting the patient's outcome. Therefore, differential diagnosis of nerve entrapments via intermuscular lipoma prevents the misdiagnosis of idiopathic compressions and incorrect surgical approaches (2). Peripheric nerve entrapment by intermuscular lipoma in the forearm shows radial nerve compression due to its anatomic relationship with the proximal radius (3). Intermuscular lipomas of the forearm and elbow joint are rare conditions, and only a few cases have been reported in the literature (2, 4). In this study, we present a case with signs of complete compression of the radial nerve and partial entrapment of the ulnar nerve due to a deep-seated intermuscular lipoma in the left forearm.

Case Report

A 68-year-old male patient was admitted to an orthopedics clinic with a three-month history of a progressive weakness of the left hand with symptoms of pain and dysesthesias radiating to the dorsal aspect of the forearm. The patient could not extend his fingers and metacarpophalangeal joints, and the grip strength of his left hand was reduced. The pre-operative evaluation included a detailed neurological exam, electromyography (EMG) / nerve conduction velocity (NCV) (2 and 4 Channel Electromyograph, EMS Biomedical, Austria) and pathology (H&E). The clinical examination revealed a deeply embedded soft tissue mass in the left forearm. Electrodiagnostic tests included radial sensory nerve conduction (SNC), radial motor nerve conduction (MNC), ulnar SNC, ulnar MNC and needle electromyography (EMG) of related muscles. The needle EMG examination included insertion sites for radial nerve and ulnar nerve innervated muscles both at the wrist and at the elbow in order to localize the lesion. Radial MNC was recorded from the extensor muscles of the forearm. The stimulation points were the proximal forearm, the groove between the biceps and brachioradialis muscles in the elbow, and the radial sulcus. The SNC of the superficial branch of the radial nerve was recorded between the extensor pollicis longus and extensor pollicis brevis muscles. The Ulnar MNC and SNC were performed by recording from C8–T1 innervated muscles. The response

This article has been accepted for publication and undergone full peer review but has not been through the copyediting, typesetting, pagination and proofreading process, which may lead to differences between this version and the Version of Record. Please cite this article as: Öğüt E, Yıldırım FB, Özsoy U, Yıldırım A. The Unusual Nerve Compression Seconder to the Intramuscular Lipoma: A Case Report. Erciyes Med J 2021; DOI: 10.14744/etd.2021.86143.
©Copyright 2021 by Erciyes University Faculty of Medicine - Available online at: www.erciyesmedj.com

UNCORRECTED

amplitudes of the left radial nerve were reduced MNC (elbow) (latency 4.64 ms, amplitude 3.44 mV, area 7.85 mVms), and the amplitude could not be obtained from SNC. The response amplitudes of the left ulnar nerve were reduced MNC (wrist) (latency 2.92 ms, amplitude 14.05mV, area 24.83 mVms, distance 6 mm, interval 2.92 ms), (elbow) (latency 7.2 ms, amplitude 14.11 mV, area 25.09 mVms, distance 26 mm, interval 4.28 ms, 6.1 m/s NCV) and decreasing velocity of sensory nerves was observed in SNC (wrist) (latency 3 ms, amplitude 75.30 mV, area 18.73 mVms, distance 12 mm, interval 3 ms, 4 m/s NCV). The pathological findings were consistent with a diagnosis of intermuscular lipoma of the forearm with a lobulated, well-circumscribed, large, solid, soft round mass (dimensions: 4.5 x 3 x 2 cm) of yellowish adipose tissue. The nuclei of the intermuscular lipoma were flattened and peripherally localized. The non-capsulated intermuscular lipoma was detected and no macroscopic evidence of fat necrosis or hemorrhage was noted. The pathological findings revealed nuclear atypia, and there was no increased mitosis, hyperchromasia, and pleomorphism of fat cells. After the EMG/NCV and pathological confirmation, surgical resection was performed. The anterior surgical approach was conducted through the flexor compartment of the forearm and an incision was made between the brachioradialis and brachialis muscles in order to identify the distribution of the radial nerve. After dividing the fascia, the intermuscular lipoma was visible, located between the brachialis and brachioradialis muscles. After the surgical resection of the lipoma from adjacent soft tissues, including nerve decompression, the patient had a complete return of neurological function over three months, with no evidence of recurrence, and has returned to his former activities.

Discussion

The intermuscular lipoma is a rare condition for adjacent peripheral nerve compression, but it has been known to affect the branches of the radial nerve (5). Allagui M *et al.* (5) reported that an intermuscular lipoma led to the paralysis of the related muscles due to entrapment of branches of the radial nerve. Fletcher et al. (6) found 83% of intermuscular lipomas were of the infiltrative type, and 17% were of the well-defined type. Furthermore, 38% of the infiltrative subtype were located in the trunk, 20% in the head and neck, 18% in the upper limb, and 10% in the lower limbs. However, 87.5% of the well-circumscribed type were located in the trunk

This article has been accepted for publication and undergone full peer review but has not been through the copyediting, typesetting, pagination and proofreading process, which may lead to differences between this version and the Version of Record. Please cite this article as: Öğüt E, Yıldırım FB, Özsoy U, Yıldırım A. The Unusual Nerve Compression Seconder to the Intramuscular Lipoma: A Case Report. Erciyes Med J 2021; DOI: 10.14744/etd.2021.86143.
©Copyright 2021 by Erciyes University Faculty of Medicine - Available online at: www.erciyesmedj.com

and 12.5% in the head region (6). Leffert *et al.* (7) stated that the most frequent reason for excision of the tumor was the existence of enlargement with a soft, resilient and non-tender mass and with no appearance of inflammation of the surrounding tissues (7). Yamamoto et al. (8) reported a case of compression of a deep branch of the radial nerve secondary to the lipoma in an asymptomatic patient where the pathological findings revealed a fibrous and adipose mass with nerve fibers passing within the mass. However, the present case exhibited an encapsulated intermuscular lipoma with the deep branch of the radial nerve adherent to the outer capsular wall with partial degeneration of the ulnar nerve where the pathological findings revealed nuclear atypia. There was no increased mitosis and multinucleation of fat cells. The location of intermuscular lipoma and its relationship with the peripheral nerves intensified the patient's conditions and made surgical excision difficult (9). Therefore, entrapment of the radial nerve's deep branch due to intermuscular lipoma requires early diagnosis and a proper surgical approach for an optimal outcome. The optimal surgical approach can vary depending on the lipoma's anatomical relation and the distribution of the adjacent peripheral nerves (10). Patel AP et al. reported that the anterior approach is the most frequent, and it is shown to have better outcomes (10). Therefore, the anterior surgical approach was performed through the forearm's flexor compartment between the brachioradialis and brachialis muscles in order to achieve optimal recovery and save the branches of the adjacent peripheral nerves. The compression of radial nerve and ulnar nerve by an intermuscular lipoma of the forearm should be kept in mind when a patient has a history of progressive weakness or sensory changes in an upper extremity.

Conclusion

At a one year postoperative follow up, the patient had the full range of motion and no numbness on the posterolateral aspect of the forearm with good grip power. Therefore, clinicians should consider the entrapment of adjacent peripheral nerves by an intermuscular lipoma and should be kept in mind the recurrence, infiltration, deep localization and its clinical and pathological manifestations.

This article has been accepted for publication and undergone full peer review but has not been through the copyediting, typesetting, pagination and proofreading process, which may lead to differences between this version and the Version of Record. Please cite this article as: Öğüt E, Yıldırım FB, Özsoy U, Yıldırım A. The Unusual Nerve Compression Seconder to the Intramuscular Lipoma: A Case Report. Erciyes Med J 2021; DOI: 10.14744/etd.2021.86143.
©Copyright 2021 by Erciyes University Faculty of Medicine - Available online at: www.erciyesmedj.com

References

1. McTighe S, Chernev I. Intramuscular lipoma: a review of the literature. Orthopedic reviews. 2014;6(4):5618.
2. de Barros LM, de Oliveira AJM, Santos AS, Lima FL, Valente RS. Peripheral nerve entrapments-rare causes of a common condition: case series. Autopsy & case reports. 2020;10(2):e2020153.
3. Bieber EJ, Moore JR, Weiland AJ. Lipomas compressing the radial nerve at the elbow. J Hand Surg Am. 1986;11(4):533-5.
4. Papakostas T, Tsovilis AE, Pakos EE. Intramuscular Lipoma of the Thenar: A Rare Case. Arch Bone Jt Surg. 2016;4(1):80-2.
5. Allagui M, Maghrebi S, Touati B, Koubaa M, Hadhri R, Hamdi MF, et al. Posterior interosseous nerve syndrome due to intramuscular lipoma. European Orthopaedics and Traumatology. 2013;5(1):75-9.
6. Fletcher CD, Martin-Bates E. Intramuscular and intermuscular lipoma: neglected diagnoses. Histopathology. 1988;12(3):275-87.
7. Leffert RD. Lipomas of the upper extremity. The Journal of bone and joint surgery American volume. 1972;54(6):1262-6.
8. Yamamoto D, Yamauchi D, Tsuchiya H. Intraneural lipoma of the posterior interosseous nerve. Journal of Hand Surgery (European Volume). 2016;41(8):882-3.
9. Murray PM. Soft tissue sarcoma of the upper extremity. Hand clinics. 2004;20(3):325-33.
10. Patel AP, Aoun SG, Al Tamimi M. Intraneural Posterior Interosseous Nerve Lipoma with Complete Paralysis: Case Report and Review of the Literature. Cureus. 2018;10(5):e2689.

UNCORRECTED

This article has been accepted for publication and undergone full peer review but has not been through the copyediting, typesetting, pagination and proofreading process, which may lead to differences between this version and the Version of Record. Please cite this article as: Öğüt E, Yıldırım FB, Özsoy U, Yıldırım A. The Unusual Nerve Compression Seconder to the Intramuscular Lipoma: A Case Report. Erciyes Med J 2021; DOI: 10.14744/etd.2021.86143.

©Copyright 2021 by Erciyes University Faculty of Medicine - Available online at: www.erciyesmedj.com

Figure Legends

Figure 1 a. Preoperative image of the intermuscular lipoma. An intraoperative image exhibiting the radial nerve within the intermuscular lipoma. The compressed radial nerve lies near the tip of the retractor (RN: the radial nerve, IL: intermuscular lipoma). The surgical section after lipoma excision: the arrows indicate the radial nerve, posterior interosseal nerve (PIN), and muscular branches at the level of the compression. The dissection of the lipoma revealed that the radial nerve and its branches were constricted by intermuscular lipoma **b.** Postoperative image of the intermuscular lipoma. The nerves were carefully released, and an intermuscular lipoma was removed. The radial nerve and its deep branches were preserved without damage (RN: the radial nerve, PIN: posterior interosseal nerve, MB: muscular branch).

Figure 2. The photomicrograph showing the pathological appearance of the intermuscular lipoma with hematoxilen and eosine *represents blood capillary (H&E)×400, scale bar = 5 µm. The round yellowish adipose tissue which is non-capsulated and has no macroscopic evidence of fat necrosis or hemorrhage is noted (black arrows). Nuclear atypia was revealed, and there was no increased mitosis, hyperchromasia, pleomorphism and multinucleation of fat cells. The cytoplasmic vacuoles were relatively uniform.

UNCORRECTED

This article has been accepted for publication and undergone full peer review but has not been through the copyediting, typesetting, pagination and proofreading process, which may lead to differences between this version and the Version of Record. Please cite this article as: Öğüt E, Yıldırım FB, Özsoy U, Yıldırım A. The Unusual Nerve Compression Seconder to the Intramuscular Lipoma: A Case Report. Erciyes Med J 2021; DOI: 10.14744/etd.2021.86143.
©Copyright 2021 by Erciyes University Faculty of Medicine - Available online at: www.erciyesmedj.com

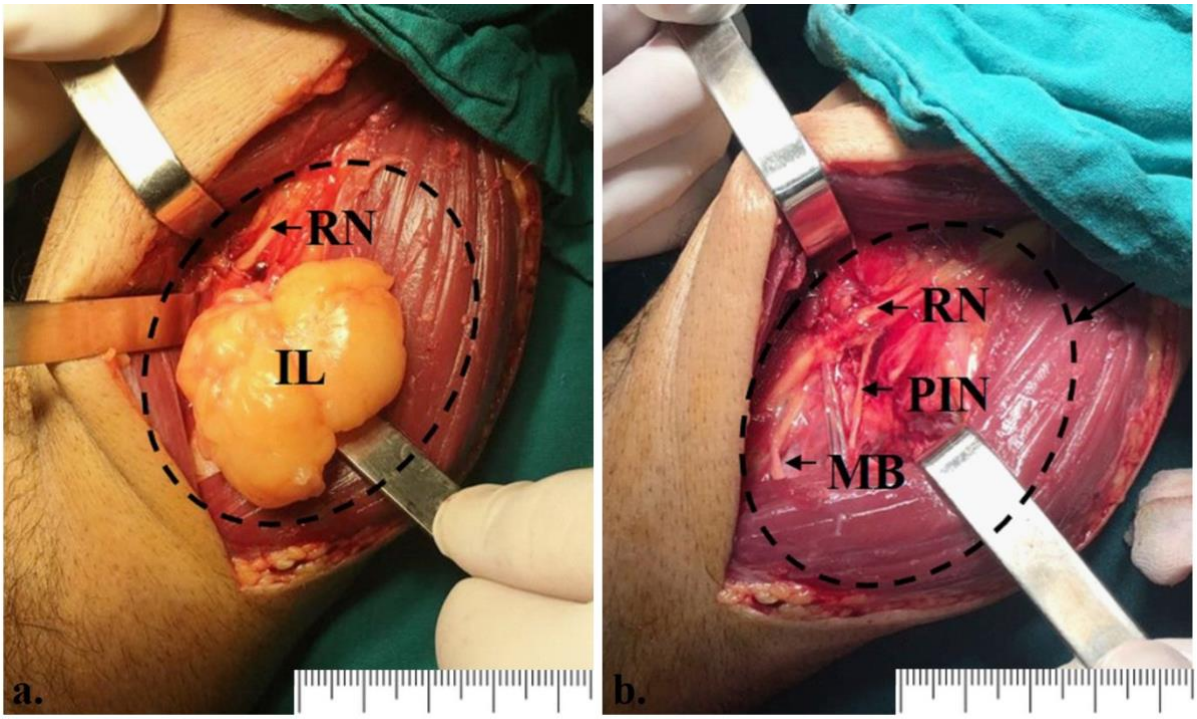

UNCORRECTED

This article has been accepted for publication and undergone full peer review but has not been through the copyediting, typesetting, pagination and proofreading process, which may lead to differences between this version and the Version of Record. Please cite this article as: Öğüt E, Yıldırım FB, Özsoy U, Yıldırım A. The Unusual Nerve Compression Seconder to the Intramuscular Lipoma: A Case Report. Erciyes Med J 2021; DOI: 10.14744/etd.2021.86143.

©Copyright 2021 by Erciyes University Faculty of Medicine - Available online at: www.erciyesmedj.com

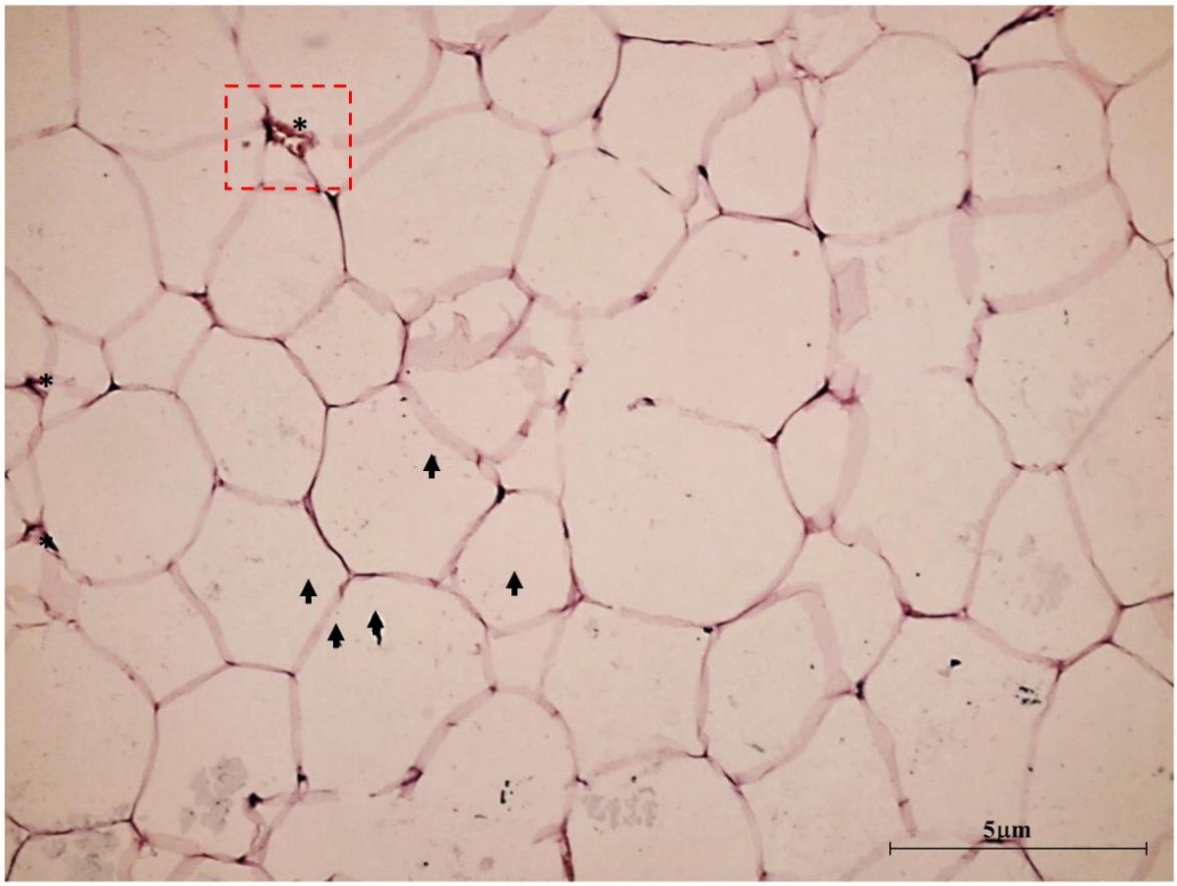

UNCO

This article has been accepted for publication and undergone full peer review but has not been through the copyediting, typesetting, pagination and proofreading process, which may lead to differences between this version and the Version of Record. Please cite this article as: Öğüt E, Yıldırım FB, Özsoy U, Yıldırım A. The Unusual Nerve Compression Seconder to the Intramuscular Lipoma: A Case Report. Erciyes Med J 2021; DOI: 10.14744/etd.2021.86143.

©Copyright 2021 by Erciyes University Faculty of Medicine - Available online at: www.erciyesmedj.com