Gray-Scale, Colour and Power Doppler Sonography of Scrotal Disorders in Dogs

A. BUMİN[1]*, M. KAYA[2], Ü. KAYA[1], M.KİBAR[3] and Z. ALKAN[1]

[1]*Department of Surgery, Faculty of Veterinary Medicine, Ankara University, 06110, Diskapi-Ankara, Turkey.*
[2] *Department of Surgery, Faculty of Veterinary Medicine, Atatürk University, 25100, Il_ca- Erzurum, Turkey.*
[3] *Department of Surgery, Faculty of Veterinary Medicine, Erciyes University, 38090, Kayseri, Turkey.*

* *Corresponding author: E-mail: alibumin@gmail.com, bumin@veterinary.ankara.edu.tr*

RÉSUMÉ

L'objectif de cette étude est d'évaluer l'utilisation pratique des résultats d'examens par ultrasonography en echelle de gris, l'ultasonographie Doppler couleur et la power Doppler ultrasonographie, ches des chiens présentés en consultation pour des problèmes d'hypertrophie scrotale.
Trente quatre chiens d'âge et de race variés, avec une hypertrophie scrotale, ont constitué le matériel d'étude. Suivant à l'anamnesis des cas, de l'ultrasonographie, de l'ultrasonographie Doppler en couleur et de la power ultrasonographie Doppler ont été utilisées pour examiner les structures extra-testiculaires et intra-testiculaires. Ces examens ont démontré la présence d'une orchite bilatérale dans 16 cas, d'une orchite unilatérale dans 6, de kystes intra-testiculaire dans 2, de hernie scrotale dans 1, d'oedème scrotal extratesticulaire dû à des blessures ou des morsure dans 4, du cryptorchidisme congénital dans 1, de tumeur dans 2 cas, et d'une epididymite dans 2 cas. En conclusion, l'examen ultrasonographique exécuté avec une sonde de haute résolution a permis de faire le diagnostic différentiel, tandis que l'ultrasonographie Doppler en couleur qui est une méthode non invasive, et la power ultrasonographie Doppler ont été permis d'arriver au diagnostic de certitude, en se basant sur l'évaluation de la vascularisation et du fleau sanguin en périphérie des lésions.

Mots-clés : Chien, Doppler, Scrotum, ultrasonographie, testicule.

SUMMARY

Utilisation de l'ultrasonographie en échelle de gris et Doppler couleur dans le diagnostic des pathologies du scrotum chez le chien

This study was aimed at the practical use of findings obtained from gray-scale ultrasonography, colour Doppler ultrasonography and power Doppler ultrasonography in dogs referred to the clinics with complaints of scrotal swelling.
Thirty four dogs of various breed and age, displaying scrotal swelling, constituted the study material. Subsequent to anamnesis of the cases, ultrasonography, colour Doppler ultrasonography and power Doppler ultrasonography of the extratesticular and intratesticular structures were performed in accordance with relevant techniques.
This study demonstrated the presence of bilateral orchitis in 16 cases, unilateral orchitis in 6, intratesticular cysts in 2, hernia scrotalis in 1, extratesticular scrotal oedema due to trauma and bite wounds in 4, congenital cryptorchidism in 1, tumor in 2, and epididymitis in 2 cases.
In conclusion, ultrasonographical examination performed with a high resolution probe was considered to contribute to differential diagnosis, whereas colour Doppler ultrasonography as a non-invasive imaging method, and power Doppler ultrasonography were determined to yield exact diagnosis, based on the evaluation of vascularisation and blood flow in the periphery of the lesion, in the diagnosis of scrotal disorders in dogs.

Keywords: Dog, Power Doppler, Colour Doppler ultrasonography scrotum, Testis, Ultrasonography.

Introduction

Scrotal disorders emanate from exogenous and endogenous causes, and follow either an acute or chronic course [3, 12, 19]. In acute cases, the testes and the periphery of the testes are swollen, and palpation demonstrates heat and pain. Animals continuously keep their legs open due to pain, and the gait is observed to be arrested [3, 12].

Similar to humans, scrotal disorders in dogs are diagnosed by means of various diagnostic methods including clinical examination, ultrasonography, Doppler ultrasonography, scintigraphy, computed tomography and magnetic resonance [2, 4, 9, 13, 17]. Amongst the indicated techniques, gray-scale ultrasonographical examination is used on a routine basis in veterinary medicine, as well as human medicine [4, 6, 8, 17]. Classical ultrasonography is used for the differential diagnosis of palpable and non-palpable testicular changes, epididymal, scrotal and testicular disorders, and the detection of undescended testes. Being an easily applicable and low-cost method that does not involve ionizing radiation, gray-scale ultrasonography is a widely preferred highly sensitive imaging modality [4, 8, 11, 13, 21].

Recently, colour Doppler ultrasonographical examination has become a significant imaging modality preferred for the vascular evaluation of various organs [1, 5, 8, 12, 20]. Colour Doppler ultrasonography enables the imaging of extratesticular, capsular, intratesticular and epididymal blood flow, and thereby the detection of pathological changes in the testicles. Researchers have reported Doppler ultrasonography to bear particular significance amongst clinical diagnostic methods, owing to the generation of potential information on the functions of organs as well as their morphology. Therefore its use in the diagnosis and differential diagnosis of scrotal disorders is gradually increasing [4, 8, 12, 13, 21].

This study was aimed at the practical use of results obtained from findings pertaining to two-dimensional gray-scale and newer colour Doppler and power Doppler ultrasonographical examination performed after clinical examina-

tion in dogs that were referred to the clinics with complaints of scrotal swelling.

Materials and methods

Thirty four dogs of various breed and age that were referred to our clinics with complaints of scrotal swelling, constituted the study material.

An Esaote-AU5 model (ESAOTE BIOMEDICA; Via Siffredi 58; 16 153 Genova, Italy) real time colour Doppler ultrasound device with 7–10 Mhz multifrequency probe was used for ultrasonographical examination. Images obtained during examinations were recorded by means of a black and white Mitsubishi P-91 printer, and a colour Mitsubishi CP – 710 printer.

Following anamnesis the dogs were subjected to general clinical examination. Subsequently, evaluation of the scrotum, testes, epididymis, and pampiniform plexus was performed by means of palpation.

Subsequent to these examinations, the dogs were maintained in dorsal position without being sedated for gray-scale ultrasonographical and colour Doppler ultrasonographical examination. Prior to examination, scrotal hair was removed with an electrical shaving machine. After being cleansed with alcohol, ultrasonography gel was applied to the scrotum. During gray-scale ultrasonographical and colour Doppler ultrasonographical examination, the standoff pad was not used. Obtained images were recorded. In classical ultrasonographical examination, the echogenicity and homogeneity of intratesticular and extratesticular scrotal structures and in addition, the processus vaginalis and scrotal surface were evaluated. In all cases, the measurements for colour Doppler ultrasonography were initiated by locating the marginal artery found within the testicular membrane, and the resistive index (RI) and pulsality index (PI) values were assessed based on spectral flow samples obtained from duplex Doppler examinations performed in regions coded with red and blue. These values were automatically calculated by means of the measurement software loaded on the ultrasound device. Furthermore, the general perfusion of the testicular paranchyme was evaluated in all cases, by means of the selection of the power Doppler mode of the device.

Findings

The percentages of scrotal disorders comprising the cases evaluated in this study are shown in Table l. In clinical examination, the animals were generally observed to keep their legs apart due to pain. Heat and pain were demonstrated upon palpation only orchitis cases.

The uniform echogenous structure of the testes was altered in 5 of the 16 cases diagnosed with bilateral orchitis, due to the completion of the acute phase. The 11 cases that were in the acute phase were determined to display heterogenous structure characterised with diffuse hypoechoic and partially hyperechogenous zones. Moreover, an evident enlargement was detected in the testes. Due to inflammation, fluid accumulation displaying slightly anechoic appearance was determined in extratesticular position, in the processus vaginalis. In all cases, the testes were observed to be enlarged and almost rounded. Abscess formation was encountered in none of these cases that had been diagnosed with bilateral orchitis. Colour Doppler examination revealed evident colour resulting from the increase in vascularisation in blue and red codes. This colour observed in the testes, suggested the existence of evident testicular hyperaemia. Spectral examination performed as part of duplex Doppler examination revealed uniphasic systolic and diastolic blood flow (figure 1). In spectral Doppler analyses, mean RI values were detected as 0.62 for the right testes, and 0.58 for the left testes. The mean PI values for the right and left testes were determined to be 1.58 and 1.45, respectively. Power Doppler examination demonstrated pronounced perfusion due to increase in vascularisation (figure 2).

	Percentages of Cases
Bilateral Orchitis	47.05
Unilateral Orchitis	17.64
Intratesticular Cysts	5.88
H. scrotalis	2.94
Scrotal Oedema	11.76
Cryptorchidism	2.94
Tumor	5.88
Epididiymitis	5.88

TABLE l. Percentages of Clinically Diagnosed Disorders Following Testicular Ultrasonography in Dogs.

Anamnesis given by the owners of the 6 dogs displaying unilateral scrotal swelling revealed the swellings to have started to develop 1 week to 20 days ago, the animals to suffer pain and to keep the rear limb with the swelling apart from the body, and to display difficulty in movement. Clinical examination performed during movement, further demonstrated the animals to keep their leg with the swelling apart from the body, due to pain. Comparison of the two testes by means of palpation revealed heat and pain on the side on which the swelling was located. Ultrasonographical examination in the 6 cases with unilateral orchitis demonstrated heterogeneity characterised with more hypoechoic and hyperechogenous zones in the inflamed testis, in comparison to the other. Furthermore, pronounced enlargement was observed in the size of these testes. Extratesticular fluid accumulation was detected in 2 of the 6 cases with unilateral orchitis, and this area appeared as an anechoic small band in ultrasonographical examination. Colour Doppler examination demonstrated more evident colourisation in blue and red codes in the testis with orchitis. This colourisation suggested more vascularisation in the testis that was diagnosed with orchitis. Duplex Doppler ultrasonographical examination demonstrated uniphasic systolic and diastolic blood flow. In spectral doppler examination, mean RI values were determined to be 0.59 and 0.47 for testes with orchitis and the other testes of the dogs, respectively. Mean PI values for testes with unilateral orchitis and other testes not displaying any clinical or ultrasonographical pathology

were measured as 1.64 and 1.43, respectively. Power Doppler examination revealed more pronounced perfusion in the testes with unilateral orchitis, in comparison to the other testes.

In two of the examined cases, a cyst with dimensions of 0.8 x 0.7 cm and 0.5 x 0.7 cm was determined to exist in the intratesticular paranchyme. The cysts appeared to be regular, thin-walled and anechoic. Distal acoustic enhancement was evident deep of the cysts. The mean RI and PI values of the testes with cysts were determined to be 0.51 and 1.52, respectively. On the other hand, the mean RI and PI values pertaining to the other testes of the same dogs that did not display any cystic structure were determined to be 0.44 and 1.49, respectively. Power Doppler examination demonstrated normal perfusion.

In one of the cases, the intestines were determined to be herniated within the scrotal sac, hernia scrotalis. Ultrasonography demonstrated intestinal movements and intestinal lobes in which fluid and gas had accumulated. In this particular case, the longitudinal and horizontal cross sections of testicular parenchymal tissue were observed to display normal homogenous parenchymal echotexture and ovoid structure, and hyperechoic mediastinum testis was imaged in the centre. A limited amount of fluid was determined in the scrotal sac on the herniated side. Normal perfusion was detected with both colour Doppler examination and power Doppler examination. Measurements based on spectral waveforms revealed RI and PI values to be 0.57 and 1.51, respectively.

Amongst the 4 cases displaying scrotal oedema, the cause was determined to be a bite wound in one case, and trauma in another, according to anamnesis. In the remaining 2 cases, the cause was unknown. In these cases, ultrasonography demonstrated an evident fluid accumulation within the processus vaginalis, displaying anechoic appearance. In the indicated cases, no particular finding was determined except for normal ultrasonographical findings in the testicular parenchymal tissue and epididymis. Since spectral waveforms were not obtained due to the severe pain the animals suffered, the measurement of RI and PI values could not be performed. Power Doppler examination of the testes revealed normal parenchymal perfusion.

Congenital cryptorchidism was detected in one case. However the scrotum was determined to enlarge only recently, according to anamnesis. Upon ultrasonographical examination, the testis located within the scrotum was determined to lose its normal parenchymal structure, with heterogeneous hypoechoic non-capsulated regions. Power Doppler and colour Doppler ultrasonography revealed a higher level of vascularisation in this testis, when compared to normal parenchymal tissue. Since orderly spectral flow samples were not been able to be obtained, RI and PI values could not be evaluated.

In the 2 cases diagnosed with testicular tumors, ultrasonography revealed the presence of homogenous and non-homogenous structures within the testicular paranchyme. However these tumors were not able to be classified ultrasonographically. Histopathological examination was performed in these castrated cases for classification. According to the results of the histopathological examination of these cases, intratubular seminoma was diagnosed in one case, and diffuse seminoma was diagnosed in the other. Mean RI and PI values were found to be 0.68 and 1.67, respectively, according to the spectral examination performed in colour Doppler examination (figure 3). The power Doppler examination of these cases demonstrated increased perfusion, in comparison to other testicular paranchymal structures, due to increased vascularisation in the periphery of the lesions.

In the 2 cases with epididymitis, pain was clinically evident. Ultrasonographical examination of these cases revealed hypoechoic enlargement in the epididymis. However, no pathology was observed in the testicular parenchyma. Pronounced perfusion of the epididymis was detected in the power Doppler examination of these cases (figure 4). However since spectral Doppler signals were not been able to be received during colour Doppler examination, RI and PI evaluation could not be made.

Discussion

Scrotal disorders arise from endogenous and exogenous causes [3, 12, 19, 22]. Amongst the cases examined in this study, the causes of scrotal disorders were determined to be exogenous, namely bite wounds and trauma, in 2 cases, and endogenous in the remaining cases. The structure of the tunica albuginea, located above the testicular paranchyme, is hard. Therefore enlargement of the testes and surrounding tissue in acute cases causes severe pain. This has been reported to result in the clinical observance of an arrested gait in animals, by trying to keep their legs apart, and also when standing, a similar effort to keep their legs apart from the body [3, 12, 14]. The cases in which orchitis, hernia scrotalis and scrotal oedema was diagnosed, similarly displayed swelling upon inspection of the testes and surrounding tissues, and in almost all cases, arrested gait and when standing, an effort to keep the legs apart from the body was observed. Palpation revealed increase in heat and evident pain.

Differential diagnosis is reported to be significant in scrotal disorders with respect to the selection of the treatment method and the prognosis of the disorder [6, 7, 16, 18, 22]. Various disorders including hernia scrotalis, testicular torsion, unilateral or bilateral orchitis, epididymitis, epididymal tumors, testicular tumors, varicocoele, cryptorchidism, sperm granulomas, and ectopic testes are reported to develop in the scrotum [3, 6, 7, 16, 18, 22].

In this study, unilateral orchitis was diagnosed in 6, bilateral orchitis in 16, intratesticular paranchymal cysts in 2, hernia scrotalis in 1, scrotal oedema due to trauma and bite wound in 4, congenital cryptorchidism in 1, tumors in 2, and epididymitis in 2 cases. As can be understood from the variety of disorders that were diagnosed, scrotal disorders indeed vary. Therefore it is critical to be able to differentiate among possible causes of pathology.Scrotal ultrasonography is a significant diagnostic method for the evaluation of scrotal

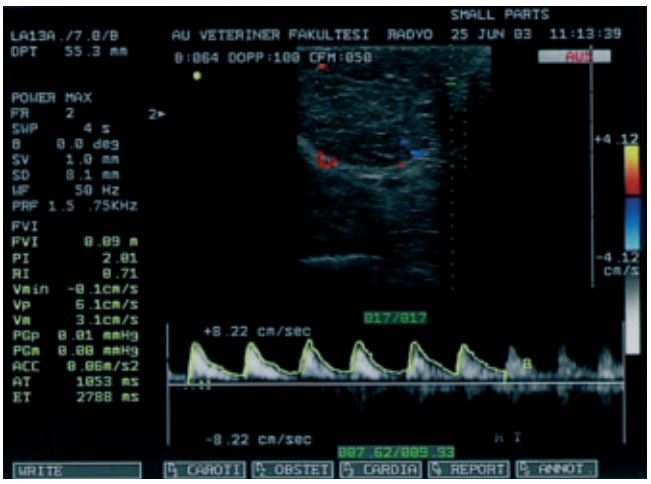

Figure 1. View of spectral wave form for orchitis, was diagnosed by duplex Color Doppler



Figure 3. Views of heterogeneity on testis and spectral wave form for diffuse seminoma, was diagnosed by duplex Color Doppler evaluation.



Figure 2. View of Power Doppler evaluation for orchitis.

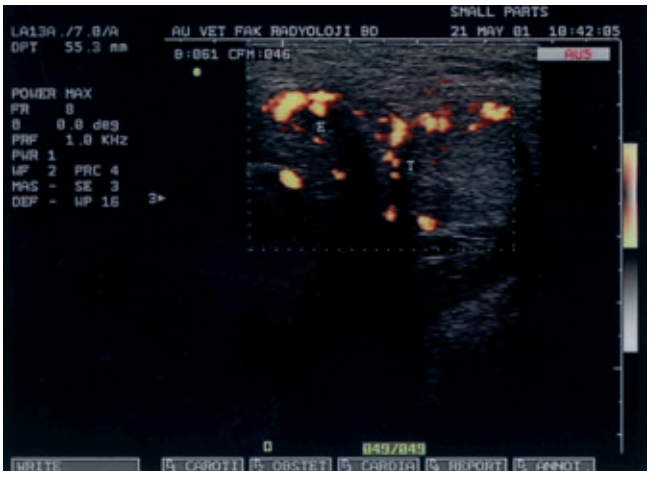

Figure 4. View of Power Doppler evaluation for epididymitis (E; Epididymis, T; Testis).

disorders. It contributes to the distinction of extratesticular and intratesticular disorders. The anatomy of the organ and the changes that develop in the organs are reported to be defined by means of ultrasonography [3, 4, 12, 13, 17, 20]. In this study, extratesticular lesions were determined in a total of 5 cases, including hernia scrotalis in one, extratesticular oedema in 2, and epididymitis in 2 cases; whereas intratesticular lesions were determined in the other cases.

In cases of orchitis, the testes are determined to be painful, and evident enlargement is observed upon ultrasonography. Heterogenous appearance displaying diffuse hypoechoic appearance, and in certain cases hyperechogenous appearance due to cell infiltration, in ultrasonography is reported to be observed in the parenchymal tissue [3, 4, 6-8, , 19, 22]. Significant findings can be obtained in the testes by means of colour Doppler ultrasonography. The sensitivity of findings obtained in cases of orchitis by means of colour Doppler ultrasonographical examination is citation for this should be included.

Moreover, even in cases in which no lesion has been determined ultrasonographically, RI and PI values of spectral waveforms obtained during colour Doppler examination are reported to provide significant information, and enable quantitative measurement [3]. Colour Doppler ultrasonographical examination revealed an increase in the blood flow of testes with orchitis. However this blood flow was in the form of monophasic blood flow with low velocity. Examination demonstrated an evident increase in colourisation observed in red and blue codes, due to increased vascularisation. Power Doppler examination is reported to be more sensitive for detection of blood flow, owing to the determination of low-velocity blood flow. Furthermore, the Doppler angle is indicated not to be significant in power Doppler examinations [3]. Colour Doppler ultrasonographical examination is reported to be non-invasive and to play a major role in the demonstration of testicular blood flow [10, 11,19, 23].

Gray-scale ultrasonographical examination demonstrated testicular parenchymal appearance of heterogenous echotexture comprising diffuse hypoechoic and partial hyperechogenic zones in cases characterised with bilateral and unilateral orchitis. Pronounced enlargement of the testes was imaged. In 6 of the cases diagnosed with bilateral orchitis, similar to the reports of researchers, fluid accumulation in the scrotum was easily determined to display slightly anechoic

appearance in ultrasonography. However since similar images may be obtained in neoplasms, this fact should be taken into consideration during ultrasonographical examination. Similar to the cases in human medicine, since the RI and PI values measured at spectral Doppler waveforms obtained in colour Doppler examination were not able to be standardised, evaluations were made based on only mean RI and PI values. Accordingly, mean RI values were determined to be 0.62 and 0.58 for the right testis and the left testis, respectively. On the other hand, mean PI values were measured as 1.58 and 1.45 for the right testis and the left testis, respectively. Similarly the mean RI and PI values were determined to be 0.59 and 1.43, respectively, in cases with unilateral orchitis. In cases diagnosed with unilateral orchitis, the mean RI and PI values pertaining to the normal testis were measured as 0.47 and 1.43, respectively. As can be understood from these results, the evaluation of the spectral blood flow obtained upon colour Doppler examination revealed an evident resistance to develop in the blood flow in the veins of testes with orchitis, and therefore an increase in RI and PI values to occur, which in result, enables a quantitative evaluation to be made in cases of orchitis.

Cysts are reported to may develop in the testes and beneath the tunica albuginea, which may later on form abscesses and cause the development of tumors. Cysts are reported be determined as homogenous anechoic structures displaying easily distinguished thin walls and acoustic enhancement deep to the lesion, in ultrasonography [4, 7, 17, 22].

Intratesticular cysts were determined in 2 of the cases examined in this study. These cysts were clearly determined to be anechoic structures with regular thin walls, in ultrasonography. No pathology related to the vascularisation or blood flow of these testes was encountered in power Doppler or colour Doppler ultrasonography. The diagnosis was confirmed by means of aspiration of the cystic content with an aspiration needle during ultrasonographical examination, and the structures were concluded to be cysts.

In cases of hernia scrotalis, the herniated organ was determined to enter either the omentum or the tunica vaginalis communis of the intestines, and the testis located within the enlarged scrotum was demonstrated to be normal. Anamnesis and findings of clinical examination are reported to be sufficient for the definition of scrotal hernias. However hernias are indicated to be classified by means of ultrasonographical examination [1, 3, 9, 18]. In case of the herniation of the intestines, intestinal lobes filled with air or fluid, and intestinal movements are indicated to be imaged by means of ultrasonography. Areas of hypechoic appearance are observed in the herniation of the omentum [1, 3, 4,18].

In this study, hernia scrotalis was determined ultrasonographically in only one case that displayed enlargement of the scrotum. The organ that had herniated in the proccesus vaginalis was determined to be the intestines. The organ was confirmed to be the intestines, based on the detection of the intestinal lobes filled with fluid, and the intestinal movements. In this particular case, both testes were demonstrated to have normal homogeneous paranchymal tissue in ultrasonographical examination, and a limited amount of fluid with anechoic appearance was detected to have accumulated in the proccesus vaginalis. Veins of blue and red colour and with normal appearance were determined. RI and PI values were measured as 0.57 and 1.51, respectively, and the testicular perfusion and blood flow were demonstrated to be normal in power Doppler and colour Doppler ultrasonography.

Researchers have reported oedema to develop extratesticularly, as a post-traumatic reaction in the scrotum, and laceration and haemorrhage to be observed in the tunica albuginea [4, 12, 20, 22]. Pain renders the performance of physical examination difficult. Scrotal and intratesticular haematomas are easily diagnosed in the early phase by means of ultrasonography. Lesions are generally hyperechoic in the early phase, and are observed as septated structures in the late phase, due to the formation of blood clots. Capsular blood flow in the testes can be demonstrated by means of colour Doppler ultrasonography and power Doppler ultrasonography [3, 20]. Scrotal swelling due to a bite wound and trauma was observed in two of the examined studies. The tunica albuginea was determined to be hyperechogenous in one case and normal in the other. In both cases, fluid accumulation due to oedema was observed within the scrotal sac. No finding indicative of haemorrhage was determined in any of the cases. Colour Doppler and power Doppler ultrasonography demonstrated blood flow in the capsular region. However RI and PI values were not been able to be measured in the animals due to severe pain.

Tumor development has been reported to may occur in the normal testes of dogs diagnosed with cryptorchidism, and these tumors are indicated to be mostly of the sertoli cell type [6, 7].

Anamnesis pointed out to the presence of congenital cryptorchidism, yet enlargement of the scrotum only recently. Ultrasonographical examination revealed loss of the normal parenchymal structure in the testis located within the scrotum, and the presence of non-capsulated regions of heterogenous appearance, determined to be more hypoechoic than normal testicular parenchymal tissue, in the testis. Vascularisation was detected to be at a higher level in this testis, in comparison to normal paranchymal tissue, upon power Doppler and colour Doppler ultrasonography. The histopathological examination of this testis was not been able to be performed due to the objection of the owner of the animal to biopsy and castration.

Three types of testicular tumors, namely, interstitial cells, sertoli cell and seminomas are common. Interstitial tumours are either small, or they merge to form large nodules. These are in the form of weakly echogenic non-capsulated structures. Sertoli tumors that cause excessive enlargement of the testes are related to feminisation syndromes, and cause excessive enlargement of the testis in which they are located, whereas they lead to atrophy of the other testis. Seminomas develop as large, solitary and unilateral lesions. Internal necrosis and haemorrhage is observed in such cases. Large lesions have mixed or complex parenchymal structure, and are generally located in the mediastinum of the testes. Although testicular tumors can be easily defined by means of

ultrasonography, no information is obtained on the type of the tumor. For this purpose, histopathological examination is required. Cases diagnosed with tumors generally display an increase in vascularisation. Evident increase in blood flow is observed particularly in the veins in the periphery of the neoplasm [6, 7]. Distinction of the tumors that have developed cannot be made according to vascularisation [6, 7, 21]. Following histopathological examination and upon gray-scale ultrasonography, intratubular seminoma and diffuse seminoma were diagnosed in two cases. Ultrasonographical examination of these cases revealed homogenous, non-homogenous structures within the testicular paranchyme. The mean RI and PI values in cases diagnosed with tumors were measured as 0.68 and 1.67, respectively. Pronounced perfusion was determined in the testes upon colour and power Doppler examination.

Ultrasonography has been reported to demonstrate enlargement of the epididymis, and the presence of non-homogenous hypoechoic zones when compared to the testes [21]. While some researchers have reported to been able to perform spectral Doppler measurement in colour Doppler examination, some other researchers have reported not to been able to perform such measurements. Pronounced hyperaemia has been reported to be observed in power Doppler ultrasonography [3, 14, 19, 20].

Epididymitis was encountered in only 2 of the 34 cases examined in this study. Clinical examination of these two cases revealed evident pain. On the other hand, although ultrasonographical examination demonstrated hypoechoic enlargement in epididymitis, no pathology was determined in the testicular paranchyme of these cases. Power Doppler examination of these cases revealed epididymitis to be associated with pronounced perfusion. However, similar to the reports of certain researchers, since spectral Doppler signals were not been able to be obtained during colour Doppler examination, RI and PI values were not able to be evaluated.

In conclusion, the observation of a wide variety of scrotal disorders in dogs requires accurate differential diagnosis to be made. Probes with high resolution and frequency must be used in the ultrasonographical examination of the scrotum. Extratesticular and intratesticular scrotal disorders are easily distinguished by means of ultrasonography. Colour Doppler ultrasonography which is a new imaging modality, was concluded to be a non-invasive diagnostic method that provides significant information for the determination of scrotal diseases. The combined use of colour Doppler ultrasonography and ultrasonography provides information on the morphology of the organ, whereas colour ultrasonography simultaneously enables the qualitative measurement of the blood flow, based on the determination of the spectrum of the blood flow. However further studies are required to be conducted in this field. Therefore the findings of this study are considered to constitute reference for future studies, and the conduction of further studies has been concluded to be a requirement.

References

1.– ARO C., ENRIQUEZ G., FITE M., TORAN N., PIRO C., PIQUERAS J., LUCAYA J.: Gray-scale and color doppler sonography of scrotal disorders in children. *Radiographics.* 2005, **25,** 1197-1214.

2.– BAKER L.A., SIGMAN D., MATHEWS RANJIV I., BENSON J., DOCIMO S.G.: An analysis of clinical outcomes using color doppler testicular ultrasound for testicular torsion. *Pediatrics.* 2000, **105**, 604-607.

3.– DOGRA V.S., GOTTLIEB R.H., OKA M., RUBENS D.J.: Sonograph of scrotum. *Radiology.* 2003, **227**, 18-36.

4.– DEMUREN OA., ADEBAYO SB., AL-THAGAFI MY.: Grey-scale and Doppler ultrasound of normal testes and extratesticular structures a pictorial review. *West. Afr. J. Med.* 2001, **20**, 7-12.

5.– DUBINSKY TJ., CHEN P., MAKLAD N.: Color-flow and power doppler imaging of the testes. *World J Urol*. 1998, **16**, 35-40.

6.– EILTS BE., PECHMAN RD., HEDLUND CS., KREEGER JM.: Use of ultrasonography to diagnose Sertoli cell neoplasia and cryptorchidism in a dog. *J Am Vet Med Assoc*. 1998, **192**, 533-534.

7.– ENGLAND GC.: Ultrasonographic diagnosis of non-palpable Sertoli cell tumours in infertile dogs. *J. Small. Anim. Pract.* 1995, **36**, 476-80.

8.– FARRIOL VG., COMELLA XP., AGROMAYOR EG., CREIXAMS XS., MARTINEZ DE LA TORRE IB.: Gray-scale and power doppler sonographic appearances of acute inflammatory diseases of the scrotum. *J. Clin.Ultrasound.* 2000,**28,** 67-72.

9.– GORECKA-SZYLD, B.: Evaluation of the value of color doppler ultrasound investigations in diagnosisof the most frequently occurring diseases of the scrotal pouch. *Ann. Acad. Med. Stetin*. 1999, **45**, 227-337.

10.– HECHT S., K_NG R., T_DWELL AS., GORMAN SC.: Ultrasound diagnosis: intra-abdominal torsion of a non-neoplastic testicle in a cryptorchid dog.*Vet Radiol Ultrasound.* 2004, **45**, 58-61.

11.– GUMBSCH P., GABLER C., HOLZMANN A.: Color-coded duplex sonografy of the testes of dogs. *The Vet. Rec,* 2002, **151**, 140-144.

12.– HENDRIKX AJ., DANG CL., VROEGINDEWEIJ D., KORTE JH.: B-mode and colour-flow duplex ultrasonography: a useful adjunct in diagnosing scrotal diseases? *Br. J. Urol.* 1997, **79**, 58-65.

13.– HORSTMAN WG.: Scrotal imaging. *Urol. Clin.of Nort. Am*. 1997, **24**, 653-671.

14.– HRICAK H., LUE T., FILLY RA., ALPERS CE., ZEINEH SJ., TANAGHO EA.: Experimental study of the sonographic diagnosis of testicular torsion. *J Ultrasound Med.* 1983, **2,** 349-356.

15.– .HUDSON-DIXON CM., LONG BW., COX LA.: Power Doppler imaging: principles and applications. *Radiol.Technol.*1999, **70,** 5-43.

16.– JOHNSTON GR., FEENEY DA., JOHNSTON SD., O'BRIN, TD.: Ultrasonographic features of testicular neoplasia in dogs: 16 cases (1980-1988). *J.Am.Vet. Med.Assoc* 1991, **98,** 779-784.

17.– LAVOIPIERRE AM.: Ultrasound of the prostate and testicles. *World J. Surg.* 2000, **24**, 98-207.

18.– MITCHENER, KL., TOAL, RL., HELD, JP., DORN AS.: Use of ultrasonographic and nuclear imaging to diagnose scrotal hernia in a dog. *J. Am. Vet. Med. Assoc.* 1990, **196**, 1834-1835.

19.– OBER C.P., SPAULDING K., BREITSCHWERDT E.B., MALARKEY D.E., HEGARTY B.C.: Orchitis in two dogs w_th Rocky Mounta_n spotted fever. *Vet. Rad. & Ultra.* 2004, **45**, 458-465.

20.– PAVLICA P., BAROZZI L . : Imaging of the scrotum. *Eur. Radio.* 2001, **11,** 220-228.

21.– POZOR M.A., McDONNELL S.M. : Color doppler ultrasound evaluation of testicular blood flow in stallions. *Theriogenology.* 2004, **61**, 799-810.

22.– SCHOEB TR., MORTON R.: Scrotal and testical changes in canine brucellosis: a case report. *J. Am. Vet. Med. Assoc.* 1978, **172**, 598-600.

23.– TARHAN F., ERBAY ME., ERDOGAN E., OZGUL A,: KUYUMCUOGLU U.: Effects of unilateral testicular torsion on the blood flow of contralateraltestis-an xperimental study on dogs. *Scand J Urol Nephrol.* 2000, **34,** 229-32.