Irish Journal of Medical Science (1971 -)
https://doi.org/10.1007/s11845-024-03614-8

CASE BASED REVIEWS

An extremely rare case of hypoglycemia with a novel mutation and review of the literature: fructose-1,6 bisphosphatase deficiency in an adult man

Hakan Doğruel[1] · Mustafa Aydemir[2] · Nusret Yılmaz[2] · Ramazan Sarı[2]

Received: 22 December 2023 / Accepted: 16 January 2024
© The Author(s), under exclusive licence to Royal Academy of Medicine in Ireland 2024

Abstract
Hypoglycemia is an uncommon clinical problem among non-diabetic patients. It requires systematic evaluation to determine the etiology. It may be related to critical illness, hepatic insufficiency, renal insufficiency, cardiac insufficiency, drugs, alcohol, cortisol insufficiency, growth hormone insufficiency, insulinoma, gastric bypass surgery, and paraneoplastic (insulin-like growth factor-2–related) immune-mediated or inherited metabolic disorders. We aimed to summarize the literature and present a case who suffered from hypoglycemia throughout his life and was diagnosed with fructose-1, 6 bisphosphatase deficiency in adulthood to attract attention to the rare causes of hypoglycemia in adulthood.

Keywords Fructose 1,6 bisphosphatase · Gluconeogenesis · Hypoglycemia · Metabolic disorder

Introduction

Hypoglycemia is an uncommon clinical problem among non-diabetic patients. It can occur in the postprandial state or fasting period [1]. The clinical signs of hypoglycemia can be defined under two main headings; the adrenergic symptoms linked to autonomic response (palpitation, tremor, sweating, etc.) and the neuroglycopenic symptoms owing to low cerebral glucose concentration (confusion, seizures, visual and behavioral disorders, or coma) [1, 2]. Although the hypoglycemia threshold is defined as a glucose level less than 55 gr/dL, the hypoglycemic disorder should not be propounded only based on a low glucose level unless it is less than 40 mg/dL. The initial evaluation should address ascertaining Whipple's triad [2, 3]. The patients in whom Whipple's triad is documented should be evaluated in detail [1–3]. Whipple's triad consists of symptoms consistent with hypoglycemia, the presence of low plasma glucose concentration, and relief of symptoms after raising the plasma glucose concentration [2, 3].

Hypoglycemia in non-diabetic adults requires systematic evaluation to determine the etiology. It may be related to critical illness, hepatic insufficiency, renal insufficiency, cardiac insufficiency, drugs, alcohol, cortisol insufficiency, growth hormone insufficiency, insulinoma, gastric bypass surgery, and paraneoplastic (insulin-like growth factor-2–related), immune-mediated or inherited metabolic disorders [1, 2]. Determining the timing of the symptoms is crucial before planning diagnostic tests for the etiology. While the mixed-meal test is preferred in the case of postprandial hypoglycemia, a prolonged fasting test is performed in fasting hypoglycemia. The critical blood sample obtained during a hypoglycemic episode is crucial for differential diagnosis [1, 4, 5]. The critical sample is tested on the standard approach for glucose, insulin, c-peptide, β-hydroxybutyrate, and circulating oral hypoglycemic agents (sulfonylurea, meglitinide). Moreover, the glycemic response to glucagon should also be evaluated [2, 3].

In this article, we presented a case who suffered from hypoglycemia throughout his life and was diagnosed with fructose 1, 6-bisphosphatase (FBPase) deficiency in adulthood. We also summarized the current literature and diagnostic approach algorithm. Hereby, we aimed to attract attention to rare causes of hypoglycemia.

✉ Nusret Yılmaz
nusretyilmaz@akdeniz.edu.tr

[1] Endocrinology and Metabolism, Antalya City Hospital, Antalya 07080, Turkey

[2] Division of Endocrinology and Metabolism, Department of Internal Medicine, Faculty of Medicine, Akdeniz University, Antalya 07070, Turkey

Published online: 25 January 2024

Case

A 24-year-old man was admitted to our outpatient clinic with symptoms consistent with hypoglycemia during the fasting period. He suffers from cold sweating, palpitation, and aggressive behaviors during prolonged fasting. All of these symptoms improve with feeding. The symptoms were present since childhood. He was admitted to the hospital many times during his childhood. There were no complaints such as weight gain or weight loss (body weight 75 kg, height 180 cm, body mass index 23.1 kg/m^2). He was looking healthy and there was no pathological finding in his physical examination. Hepatomegaly and splenomegaly were not detected in abdominal ultrasound imaging.

After evaluating his hormonal and metabolic profile with basal measurements (Table 1), he was admitted to the hospital for a prolonged fasting test (Table 2). A hypoglycemic episode occurred at the 16th hour of the prolonged fasting test. The critical sample was obtained and 1 mg glucagon was administered intravenously. The glycemic response to glucagon was blunt (Table 2). The plasma glucose level was raised by intravenous dextrose infusion and the symptoms were improved. Insulin and c-peptide levels were suppressed during the hypoglycemic episode (glucose 26 mg/dL, insulin < 0.4 uU/mL, c-peptide 0.07 ng/mL).

Non-insulin mediated ketotic hypoglycemia with metabolic acidosis and increased lactate level was detected in the critical sample (Table 2). Urinary glycerol 3-phosphate level was also increased. The results were consistent with gluconeogenesis defects. The deficiencies of pyruvate carboxylase (PC) and phosphoenolpyruvate carboxykinase (PEPCK) are associated with severe progressive neurodegenerative disorder that is usually fatal. Diagnosis of glycogen storage disease type 1 (GSD-1) is also unlikely because the other manifestations of the disease (hepatomegaly, muscular findings, etc.) were absent [1, 5]. Glycogen storage disease (GSD) type 0, liver (liver glycogen synthetase deficiency), a disorder of glycogen synthesis, is another cause of ketotic hypoglycemia. But lactate level is normal during fasting and increased postprandially in GSD type 0 [6]. Under the present circumstances, the most

Table 1 Basal laboratory tests

Test	Result (normal range)
Glucose (mg/dL)	89 (74–106)
Creatinine (mg/dL)	0.84 (0.7–1.2)
ALT (U/L)	17 (< 41)
AST (U/L)	15 (< 40)
Uric acid (mg/dL)	7.4 (3.4–7)
Creatinin kinase, total (U/L)	178 (20–200)
Bicarbonate (mmol/L)	26.1 (22–29)
Ammonia (µg/dL)	46.5 (27–102)
Lactate (mmol/L)	2.3 (0.5–2.2)
Triglyceride (mg/dL)	100 (< 150)
LDL (mg/dL)	120 (< 100)
HDL (mg/dL)	53 (35–55)
Total cholesterol (mg/dL)	182 (< 200)
TSH (µIU/mL)	2.04 (0.27–4.2)
free T_4 (ng/dL)	1.53 (0.93–1.71)
ACTH (pg/mL)	40.5 (7.2–63.3)
Cortisol (µg/dL)	17.5 (4.82–19.5)
GH (ng/mL)	0.4 (< 3)
IGF-1 (ng/mL)	216 (83.6–259)
Testosterone, total (ng/mL)	6.24 (2.49–8.36)

ALT alanine transaminase, *AST* aspartate aminotransferase, *LDL* low-density lipoprotein, *HDL* high-density lipoprotein, *TSH* thyroid-stimulating hormone, *T_4* thyroxine, *ACTH* adrenocorticotropic hormone, *GH* growth hormone, *IGF-1* insulin-like growth factor-1

Table 2 Prolonged fasting test (critical sample)

Test	Result (normal range)
Glucose (mg/dL)	26 (74–106)
Insulin (µU/mL)	< 0.4 (2.6–24.9)
c-Peptide (ng/mL)	0.07 (1.1–4.4)
pH	7.27 (7.35–7.45)
Bicarbonate (mmol/L)	18.8 (22–29)
Ketone (urine)	3 + (negative)
Ketone (capillary) (mmol/L)	1.2 (< 0.6)
Lactate (mmol/L)	8.9 (0.5–2.2)
Uric acid (mg/dL)	8.7 (3.4–7)
Ammonia (µg/dL)	23.1 (27–102)
Creatine kinase, total (U/L)	191 (20–200)
Alanine, plasma (µmol/L)	360 (200–579)
Citrulline, plasma (µmol/L)	21.3 (17–46)
Urine organic acids (mmol/mol cre)	-
Lactic acid	437 (33–285)
3-Hydroxybutyric acid	304 (0.1–11.1)
Glycerol 3-phosphate	0.15 (0.01–0.1)
2-Methyl 3-hydroxy butyric acid	3.69 (3.2–26.6)
Tiglylglycine	0.01 (0.01–0.1)
Response to glucagon administration	
Time (min)	Glucose (mg/dL)
0	26 (74–106)
10	24 (74–106)
20	32 (74–106)

likely diagnosis was FBPase deficiency. This enzyme has strategic importance in gluconeogenesis. Interestingly, there are cases with a favorable clinical course besides severe progressive cases [5, 7, 8]

Genetic analysis of FBPase gene mutation was performed (DNA was isolated with the magnetic bead method (MagPurix-Zinexts, Taiwan)). PCR amplification was done in-house designed primers. Amplicons were checked by 2% agarose gel electrophoresis. Sequencing was done by the next-generation sequencing method by a Miseq-Illumina equipment (Illumina, San Diego, CA, USA) by following manufacturers' instructions. Data were evaluated by IGV 2.3 (Broad Institute) software. Sequencing of all coding sequences and exon–intron boundaries was performed, and *FBP1* gene (NM_000507.3) analysis revealed a c.830G > C (p.R277T) (p.Arg277Thr) homozygous variant. This is a novel variant that has not been reported previously. This variant is present in the dbSNP database (rs1263437440). This variant is placed in the protein's metal ion binding "Magnesium 3" region. This is a hotspot for mutations in the conserved region. Pathogenic computational predictions were detected with BayesDel_addAF, DEOGEN2, EIGEN, FATHMM-MKL, LIST-S2, M-CAP, MVP, Mutation Assessor, Mutation Taster, and SIFT while 2 benign predictions from DANN and Primate AI software. That is why we classified it as pathogenic due to the American College of Medical Genetics (ACMG) criteria.

The exact diagnosis of fructose 1,6-bisphosphatase deficiency was done with the revealed genetic mutation. We advised avoiding fasting, consuming frequent meals, and restriction of fructose, sucrose, sorbitol, and glycerol. He did not experience hypoglycemia under these recommendations.

Discussion

FBPase deficiency is an autosomal recessive metabolic disorder, characterized by episodic attacks of ketotic hypoglycemia and lactic acidosis. The estimated prevalence is between 1/350,000 and 1/900,000. Approximately 150 cases have been reported in the literature [5]. Some of fructose 1–6 bisphosphatase deficiency cases presented in the literature are summarized on Table 3. Although FBPase deficiency is mostly diagnosed during the neonatal period, infancy, or early childhood, very few patients are firstly diagnosed in adulthood [5, 9, 10]. An acute crisis may be lethal, especially in neonates and infants [5]. Fasting, fever, infection, vomiting, or ingestion of a large amount of fructose may trigger an episode. It is known that fasting tolerance generally improves with age [5, 10]. The inter-crisis periods are generally asymptomatic with normal growth [1, 5]. Our patient was a healthy-looking individual, with normal neurocognitive and physiological functions. He is a recently graduated computer engineer.

The diagnosis of FBPase deficiency is a rare condition in adults. Few cases of this condition have been reported in the literature as being diagnosed in adulthood. Fawdry et al. reported the case of a 30-year-old male who was admitted to the emergency room with symptomatic hypoglycemia. His glucose level was 36 mg/dL. The patient had a 2-day history of mild, intermittent abdominal pain and food cravings that were not responsive to simple carbohydrates, dairy products, and fruits. The laboratory evaluation showed severe lactic acidosis (lactate 18 mmol/L, pH 6.9), hyperkalemia, and transaminase elevation. There was no acute kidney injury or infection. During the 18th hour of a supervised fasting test, the patient developed non-insulin-mediated ketotic hypoglycemia with lactic acidosis, which led to a clinical diagnosis of FBPase deficiency. The diagnosis was confirmed through genetic analysis and a decrease in enzyme activity in white blood cells in their case [20]. Krishnamurthy et al. briefly reported a woman previously misdiagnosed as a "glycogen storage disease" and presented with recurrent hypoglycemia and lactic acidosis during the second trimester of her first pregnancy. The exact diagnosis of FBPase deficiency was made by genetic testing. This patient had three pregnancies under dietary management [7]. Non-insulin-mediated ketotic hypoglycemia with lactic acidosis, which emerged under certain conditions, was the main clinical picture in our case and the others.

Some circumstances raise the suspicion of inherited metabolic disorder in the presence of hypoglycemia (Table 4) [1, 4]. In addition to the standard prolonged fasting test procedure, the recommended tests to run on the critical sample in case of fasting hypoglycemia and suspicion of hereditary metabolic disease are blood pH, lactate, ketone bodies (urinary and/or blood), liver parameters, creatine kinase, uric acid, triglyceride, free fatty acids, acylcarnitines (dry spot), carnitine profile, plasma amino acids, ammonia and urinary organic acids [4, 5].

Fatty acid oxidation disorders, gluconeogenesis disorders, and glycogenolysis disorders are the main inherited metabolic disorders responsible for fasting hypoglycemia in adults (Fig. 1) [1, 5].

A critical sample obtained during an acute episode is required to make the differential diagnosis of the etiological cause of hypoglycemia [2, 4]. Acute hypoglycemic episodes can be triggered by prolonged fasting in gluconeogenetic disorders [1, 4]. Ketosis (rarely not present) and lactic acidosis with high levels of glycerol and glucogenic amino acids (alanine, valine, glycine, etc.) during the acute

Table 3 Summary of fructose 1–6 bisphosphatase deficiency cases presented in the literature

Clinical presentation	Diagnosis
Baker and Winegrad [11] • Case: A child presented with fasting hypoglycemia accompanied by metabolic acidosis	Measuring the enzyme activity in liver biopsy specimen
Bührdel et al. [12] • Case 1: A 17-month-aged male infant presented with pneumonia and developed metabolic acidosis and ketonuria after sorbitol-containing fluid infusion • Case 2: A male born experienced a short apneic spell with cyanosis 12 h after delivery. He did well after feeding with breast milk. The diet was changed to a sucrose-containing formula at the 3rd week and vomiting, hypoglycemia, metabolic acidosis, and convulsion occurred • Case 3: A 4 years 10-month-old, physically and mentally well girl presented with a right-sided cataract and moderate hepatomegaly. She developed hypoglycemia with increased lactate level during 5 h fasting. Oral fructose also caused hypoglycemia with increased lactate level and metabolic acidosis within 2 h • Case 4: A premature male born admitted with seizure and hypoglycemia at the age of 3 days. A rapid increase in direct bilirubin was detected. Exchange transfusion was performed. The liver functions were diminished. Bilirubin levels returned to normal but transaminase levels persisted to be high at 3 months. He exhibited a hypoglycemic spell with metabolic acidosis after a sucrose-containing diet	Measuring the enzyme activity in liver biopsy specimen
Tavil and Sipahi [13] • Case: A 6-month old girl infant presented with hypoglycemia and metabolic acidosis, hyperuricemia and ketonuria induced by respiratory infection. Hepatomegaly and increased transaminase levels	Laboratory results were consistent with FBPase deficiency. No FBPase activity measurement or genetic analysis was performed
Krishnamurthy et al. [7] • Case: An adult woman presented with recurrent episodes of lactic acidosis and hypoglycemia during the second trimester of her first pregnancy. She was misdiagnosed with glycogen storage disease, previously. She had three successful pregnancies through dietary management	Genetic analysis
Paksu et al. [14] • Case: An 8-month-old male infant presented with hyperglycemia and acidosis mimicking diabetic ketoacidosis and sepsis	Results were consistent with a gluconeogenesis defect and leukocyte glycerol kinase activity was normal. No FBPase activity measurement or genetic analysis was performed
Lebigot et al. [15] • Total of 12 patients (4 in the neonatal period, 4 in the early infancy (< 1 year), 4 in childhood), most of them presented with acute metabolic acidosis and hypoglycemia, two patients presented with isolated hypoglycemia and one patient with Reye syndrome	Measuring the enzyme activity in leukocytes and genetic analysis
Josh et al. [16] • Case: A 6-year-old boy presented with hypoglycemia and metabolic acidosis. He had several hospital admissions due to hypoglycemic convulsions throughout his life. He was misdiagnosed with glycogen storage disease during early neonatal period	Urine and blood test results were consistent with FBPase deficiency. No enzyme activity measurement or genetic analysis was performed
Lu et al. [9] • Case: A 23-year-old woman presented with abdominal pain, vomiting and dizziness. Hypoglycemia, lactic acidosis, liver, and kidney dysfunction. Normal intellectual development	Genetic analysis

Table 3 (continued)

Clinical presentation	Diagnosis
Li et al. [8] • Case 1: A 5 years 6-month-old girl presented with fever, vomiting, seizures, and coma. She had been hospitalized several times throughout her life because of hypoglycemia and metabolic acidosis • Case 2: A 7 years 3-month-old girl presented with convulsion. She had been presented with hypoglycemia, metabolic acidosis, and convulsion two times before • Case 3: A 6 years 4-month-old girl presented with recurrent hypoglycemia. She had been hospitalized several times throughout her life because of hypoglycemia, metabolic acidosis, hyperlactatemia, convulsions, and syncope • Case 4: A 10 years 8-month- old boy presented with vomiting, convulsions, and coma. Hypoglycemia and lactic acidosis were revealed. He also had obvious intellectual development delay. He was misdiagnosed with epilepsy before	Genetic analysis
Kılıc et al. [17] • 10 children, diagnosis age was between 9 and 97 months. All of them presented with vomiting, hypoglycemia, lactic acidosis, and hyperuricemia	Genetic analysis
Salih et al. [18] • 7 children, diagnosis age was between 1 day and 3 years 7 months. All of them presented with hypoglycemia, lactic acidosis, and hyperuricemia. 1 patient had hepatomegaly and delayed speech	Critical sample obtained during episode and the test results suggested gluconeogenesis defect. Genetic analysis confirmed the exact diagnosis
Samprathi et al. [19] • Case: A 2-year-old girl presented with fever, vomiting, hypoglycemia, metabolic acidosis, hyperlactatemia, and ketonuria	Genetic analysis
Fawdry et al. [20] • Case: A 30-year-old man presented with symptomatic hypoglycemia and metabolic acidosis	Critical sample during prolonged fasting test suggested gluconeogenesis defect. Genetic analysis and low enzyme activity in white blood cells confirmed the exact diagnosis
Yi and Xie [21] • Case: A 4 years 1-month-old girl presented with headache and convulsions. Hypoglycemia, metabolic acidosis, hyperlactatemia, and ketonuria were detected	Genetic analysis
Liang et al. [22] • Case: A 12-year-old boy presented with repeated episodes of hypoglycemia and seizures. He was unconscious at the admission for 4 h. Hypoglycemia, lactic acidosis, and hyperuricemia were revealed. He had also developed epileptic encephalopathy with mental retardation by age 5	Genetic analysis

episode are consistent with gluconeogenetic defects [5, 10]. GSD-1, PC deficiency, PEPCK deficiency, and FBPase deficiency are the main gluconeogenetic disorders in human beings. Diagnosis of GSD-1 was unlikely because of the absence of the other manifestations. PC and PEPCK deficiencies have severely progressive courses and are usually fatal in early life. Although FBPase deficiency has usually a progressive course, cases with favorable courses have also been reported [1, 5, 10]. The exact diagnosis FBPase deficiency requires the demonstration of either biallelic FBP1 pathogenic variants in molecular genetic testing or deficient FBPase activity [1, 4, 5]. Because this variant is placed in a very well-conserved region and a hotspot, and the clinical picture overlaps with the results, it was classified as pathogenic. Although this variant was present in the dbSNP database, there is no published case in the literature and databases.

The main principles of management are consuming frequent meals, avoiding fasting, and restricting fructose, sucrose, sorbitol, and glycerol. Appropriate management during intercurrent illnesses, surgical procedures, and acute episodes is substantially vital [5, 7].

Table 4 The circumstances that raise the suspicion of inherited metabolic disorder

- Family history
- Hypoglycemia in childhood
- Myalgia
- Muscle fatigue
- Rhabdomyolysis
- Lactic acidosis
- Unexplained heart disease
- Hepatomegaly

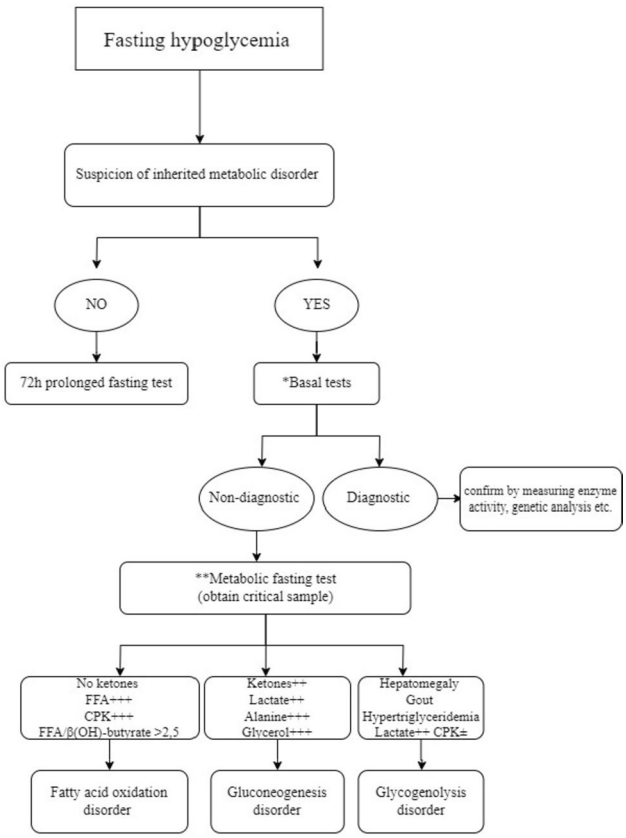

Fig. 1 Diagnostic approach to fasting hypoglycemia. Asterisk (*) indicates abdominal ultrasound, ECG, echocardiography, alanine aminotransferase (ALT), aspartate aminotransferase (AST), triglycerides, uric acid, creatine phosphokinase (CPK), lactate, acylcarnitine, carnitine, and urinary organic acids; two asterisks (**) indicate the prolonged fasting test performed in case of suspicion from inherited metabolic disorder; FFA, free fatty acids

Conclusion

Inherited metabolic disorders are rare diseases and likely underdiagnosed. They are usually diagnosed in early life but sometimes can be revealed in adulthood, especially in those with mild symptoms [1, 7, 10]. Suspicion is the first step to making a diagnosis. Hypoglycemia may sometimes be the presenting sign of an inherited metabolic disorder. The circumstances that raise the suspicion of inherited metabolic disorder should be kept in mind and the patient should be referred to an expert center, in case of doubt.

Acknowledgements The authors would like to thank Serdar Ceylaner, MD, for performing genetic analysis and for his contribution to the preparation of this manuscript.

Author contribution All authors were involved in the patients' diagnosis and clinical care. All authors were involved in the planning of the manuscript. Hakan Doğruel searched the literature and wrote the first draft. All other authors provided extensive input. All authors approved the final manuscript.

Funding None.

Data availability The data that support the clinical characteristics and findings of the case are available from the corresponding author upon reasonable request.

Declarations

Competing interests The authors declare no competing interests.

References

1. Douillard C, Jannin A, Vantyghem M-C (2020) Rare causes of hypoglycemia in adults. Ann Endocrinol (Paris) 81(2-3):110–117. https://doi.org/10.1016/j.ando.2020.04.003
2. Cryer PE, Axelrod L, Grossman AB et al (2009) Evaluation and management of adult hypoglycemic disorders: an Endocrine Society Clinical Practice Guideline. J Clin Endocrinol Metab 94(3):709–728. https://doi.org/10.1210/jc.2008-1410
3. Service FJ (1999) Diagnostic approach to adults with hypoglycemic disorders. Endocrinol Metab Clin North Am 28(3):519–532. https://doi.org/10.1016/s0889-8529(05)70086-4
4. Douillard C, Mention K, Dobbelaere D et al (2012) Hypoglycaemia related to inherited metabolic diseases in adults. Orphanet J Rare Dis 7:1–11. https://doi.org/10.1186/1750-1172-7-26
5. Bijarnia-Mahay S, Bhatia S, Arora V (2019) Fructose-1, 6-bisphosphatase deficiency. In: Adam MP, Feldman J, Mirzaa GM, et al (eds) GeneReviews® [Internet]. Seattle (WA): University of Washington, Seattle, pp 1993–2024. Available from: https://www.ncbi.nlm.nih.gov/books/NBK550349/. Accessed 20 November 2023
6. Iijima H, Ago Y, Fujiki R et al (2021) Novel GYS2 mutations in a Japanese patient with glycogen storage disease type 0a. Mol Genet Metab Reports 26:100702. https://doi.org/10.1016/j.ymgmr.2020.100702
7. Krishnamurthy V, Eschrich K, Boney A et al (2007) Three successful pregnancies through dietary management of fructose-1, 6-bisphosphatase deficiency. J Inherit Metab Dis 30:819. https://doi.org/10.1007/s10545-007-0606-y
8. Li N, Chang G, Xu Y et al (2017) Clinical and molecular characterization of patients with fructose 1, 6-bisphosphatase deficiency. Int J Mol Sci 18(4):857. https://doi.org/10.3390/ijms18040857
9. Lu J-R, Wang C, Shao L-P (2017) A Chinese adult patient with fructose 1, 6-bisphosphatase deficiency. Chin Med J 130(16):2009–2010. https://doi.org/10.4103/0366-6999.211890
10. Tran C (2017) Inborn errors of fructose metabolism. What can we learn from them? Nutrients 9(4):356. https://doi.org/10.3390/nu9040356
11. Baker L, Winegrad A (1970) Fasting hypoglycaemia and metabolic acidosis associated with deficiency of hepatic fructose-1, 6-diphosphatase activity. The Lancet 296(7662):13–16. https://doi.org/10.1016/s0140-6736(70)92474-8
12. Bührdel P, Böhme H-J, Didt L (1990) Biochemical and clinical observations in four patients with fructose-1, 6-diphosphatase deficiency. Eur J Pediatr 149:574–576. https://doi.org/10.1007/BF01957696
13. Tavil B, Sipahi T (2003) Fructose 1, 6 diphosphatase deficiency in a Turkish infant. Eur J Pediatr 162:719–720. https://doi.org/10.1007/s00431-003-1234-7
14. Paksu MS, Kalkan G, Asilioglu N et al (2011) Gluconeogenesis defect presenting with resistant hyperglycemia and acidosis mimicking diabetic ketoacidosis. Pediatr Emerg Care 27(12):1180–1181. https://doi.org/10.1097/PEC.0b013e31823b412d
15. Lebigot E, Brassier A, Zater M et al (2015) Fructose 1, 6-bisphosphatase deficiency: clinical, biochemical and genetic

features in French patients. J Inherit Metab Dis 38(5):881-887. https://doi.org/10.1007/s10545-014-9804-6
16. Joshi VS, Gangane SD, Mahajan M (2016) Fructose-1, 6-diphosphatase deficiency presenting as glycogen storage disease. J Med Sci Clin Res 4(01):8795–8799. https://doi.org/10.18535/jmscr/v4i1.02
17. Kılıç M, Kasapkara ÇS, Yılmaz DY et al (2019) Exon 2 deletion represents a common mutation in Turkish patients with fructose-1, 6-bisphosphatase deficiency. Metab Brain Dis 34:1487–1491. https://doi.org/10.1007/s11011-019-00455-8
18. Salih RM, Mohammed EA, Alhashem AM et al (2020) Fructose-1, 6-bisphosphatase deficiency with confirmed molecular diagnosis: an important cause of hypoglycemia in children. Saudi Med J 41(2):199. https://doi.org/10.15537/smj.2020.2.24885
19. Samprathi M, Sridhar M, Adiga R et al (2021) Novel mutation with fructose-1, 6-bisphosphatase deficiency. Indian J Pediatr 88:505. https://doi.org/10.1007/s12098-021-03694-9
20. Fawdry H, Gorrigan R, Ramachandran R et al (2022) A novel variant of fructose-1, 6-bisphosphatase gene identified in an adult with newly diagnosed hepatitis C. JIMD Rep 63(2):109–113. https://doi.org/10.1002/jmd2.12256
21. Yi C, Xie J (2022) Fructose-1, 6-bisphosphatase deficiency. Endokrynol Pol 73(5):911–912. https://doi.org/10.5603/EP.a2022.0064
22. Liang X, Liu X, Li W et al (2023) A novel variant in the FBP1 gene causes fructose-1, 6-bisphosphatase deficiency through increased ubiquitination. Arch Biochem Biophys 742:109619. https://doi.org/10.1016/j.abb.2023.109619

Publisher's Note Springer Nature remains neutral with regard to jurisdictional claims in published maps and institutional affiliations.

Springer Nature or its licensor (e.g. a society or other partner) holds exclusive rights to this article under a publishing agreement with the author(s) or other rightsholder(s); author self-archiving of the accepted manuscript version of this article is solely governed by the terms of such publishing agreement and applicable law.