P152 - ALLERGIC BRONCHOPULMONARY ASPERGILLOSIS:COULD BE PRESENT IN CHILDREN WITH IDIOPATIC BRONCHIECTASIS?

A. Aslan, E. Yalçın, D. Doğru, U. Özçelik, N. Kiper
Hacettepe University Pediatric Chest Diseases Unit, Ankara, Turkey

Allergic bronchopulmonary aspergillosis (ABPA) is a complex condition that results from hypersensitivity to the fungus Aspergillus fumigatus. Radiologic documentation of bronchiectasis may help the diagnosis of patients with ABPA. While ABPA is itself an important complication of asthma and cystic fibrosis (CF), we screened our idiopatic bronchiectatic patients whether or not to have ABPA. Twenty-two patients with bronchiectasis who hadn't had CF or immunologic disorder were included in this study aiming determination of the ABPA in this 2,29) and equal from_population. They ranged in age from 6-21 years (mean 13,59 both sexes. The lung sites of bronchiectasis in the patients were left basal in 6 patients, left basal and right medial in 5 patient, bilateral basal involvement in 4 patient and the other sites in 7 patients. Total IgE and eosinophil levels were all normal. And also Aspergillus fumigatus was not cultured in all patients. Our results revealed that ABPA is not accompaning with idiopathic bronchiectasis. This finding may be attributed to the small sample size and absence of proximal bronchiectasis in our patients.

P153 - CHARACTERISTICS OF ACUTE WHEEZING IN EARLY CHILDHOOD

F. Şimşek, İ. Bostancı**, N. Dalgıç*, İ. Türktaş****
**Departments of Pediatrics, Ankara University, Medical School, Ankara, Turkey*
***Department of Pediatric Allergy and Asthma, Ankara Education and Research Hospital, Ankara, TURKEY*
****Department of Allergy and Asthma, Gazi University, Medical School, Ankara, TURKEY*

Objectives; Wheezing is an important illness for children, which causes admission to hospital. The aim of the present study was to evaluate the demographic factors of wheezing. Another aim of our study was to evaluate the risk factors associated with the subsequent wheezing. Methods; This is a retrospective, chart review study of 1870 children with an acute bronchiolitis attack and wheezing admitted to the Department of Pediatrics, Gazi University. Results; In our study, the median age for the first wheezing episode was 6±2.1 months and 53% of patients had their first wheezing episode before the age of 6 months. Seasonal variations were shown as winter and early spring peaks, and male predominance was found. Age of the patient, age at the first attack, passive smoking, lack of breast-feeding and history of atopy in parents or siblings had strong influences on the number of attacks ($p<0.001$, $p<0.001$, $p<0.001$, $p0.001$, $p<0.05$). Prematurity, lack of breast-feeding and days of hospitalization had strong influence on the age of the first attack ($p<0.001$, $p<0.001$, $p<0.01$). Conclusions; Environmental factors such as maternal smoking during pregnancy, passive smoke exposure and family history of atopy were found to be the risk factors associated with the subsequent wheezing.

P154 - DIFFUSE PANBRONCHIOLITIS: A CASE REPORT

A. Aslan, F. Dalgıç*, E. Yalçın*, D. Doğru*, U. Özçelik*, N. Kiper*, B. Talim**, M. Haliloğlu****
**Hacettepe University Pediatric Chest Diseases Unit, Ankara, Turkey*
***Hacettepe University Pediatric Pathology Unit, Ankara, Turkey*
****Hacettepe University Radiology Unit, Ankara, Turkey*

Difusse panbronchiolitis(DPB) is a chronic progressive disease of the lower respiratory tract which is prevalant in the Far-East, but extremely rare in western countries. Disease is characterized by chronic recurrent sinopulmonary infection and inflammation. The diagnostic hallmarks of DPB are iflammatory changes observed in peribronchial tissue such changes include thickening of the wall of the respiratory bronchioles, thickening of peribronchial tissue, and bronchial infiltration by lymphocytes, plasma cells and inflammatory cytokines and IL-8. Lack of familiarity with DPB in the western_such as interleukin 1 countries may result in the failure to correctly diagnose and treat this disorder. We describe a 12-year old girl in whom the characteristic imaging and histologic features of DPB were recognised. We believe that DPB patients describe from Turkey and other non-Far Asian countries may also increase if this disease is taken into consideration in differantial diagnosis of sinopulmonary diseases. In this report we also described the second Turkish case of DPB, furthermore, to our knowledge she was the first childhood case described in Europe in the English literature .

P155 - UNILTERAL PULMONARY AGENESIS ASSOCIATED WITH COLLOIDAL GOITER IN A NEWBORN INFANT:A CASE REPORT

G. Gökhan, G. Özbilim**, S. Bozova*, A. Güra***, H. Ongun***, E. Mıhçı****
**Akdeniz Üniversitesi Patoloji*
***akdeniz Üniversitesi Patoloji*
****Akdeniz Üniversitesi Pediatri*

Unilateral pulmonary agenesis is a very rare developmental malformation that is often associated with other anomalies. It can be asymptomatic or present with respiratory symptoms. Our case is a female newborn infant who had been taken to the hospital suffering from difficulty in breathing at the first day of birth. Tachypnea, intercostal and subcostal retractions were detected in her physical examination. Because of respiratory failure, the baby passed away at the age of 3

days. In our autopsy examination and its histopathological evaluation, we detected right pulmonary agenesis and colloidal goiter. According to the literature; pulmonary agenesis is associated with other anomalies including esophageal atresia, tracheal stenosis, musculoskeletal anomalies, Di-George syndrome and cardiovascular malformations such as; septal defects, patent ductus arteriosus and total anomalous pulmonary venous return. To our knowledge, this is the first case that pulmonary agenesis associated with colloidal goiter.

P156 - CHARACTERISTICS OF LOWER RESPIRATORY TRACT ILLNESS IN CHILDHOOD

İ. Bostancı, S. Savaş**, Y. Dallar****
**Department of Pediatric Allergy and Asthma, Ministry of Healthy Ankara Education and Research Hospital, Ankara, TURKEY*
***Department of Pediatrics, Ministry of Healthy Ankara Education and Research Hospital, Ankara, TURKEY*
****Chief of Pediatrics, Ministry of Healthy Ankara Education and Research Hospital, Ankara, TURKEY*

Objective: Lower respiratory tract infections in children (LRTI) are a common cause of mortality in developing countries, and represent a major source of morbidity among children worldwide. The aim of this study was to evaluate the characteristic and demographic data in hospitalized children with LRTI. Method: 465 consecutive children admitted to hospital with LRTI between December 2000 and November 2001 was enrolled in the study. Data were entered into a form specifically designed for this study and included the following information: age; sex; average length of stay in hospitalization, month of hospitalization; microbiologic findings; maternal smoking habits; outdoor air pollution; number of other children in the family; a history of wheezing and recurrent respiratory infections; diagnosis. Results: 58.1 % of patients were girls and the mean age of the population was 27.3±2.7 (std.error) months. The distribution of patients due to age groups was 0-2 years; 332, 2-5 years; 71, 5-15 years; 62 cases. 317 of cases were pneumonia whereas 148 of them were bronchiolitis. Cough, wheezy and dyspnea symptoms combination was frequent in bronchiolitis whereas cough plus fever symptoms were frequent in pneumonia (p=0.03). The blood cultures of 317 patients were negative. Eight patients (1.7%) had a total of 2 pathogens identified from blood cultures. The maternal smoking ratio was 45.7%. The breastfeeding ratio was 65.6% 0-2 age group. The duration of hospitalization was below ten days in 89% patients. The first hospitalization ratio was as 83.3% in pneumonia group whereas recurrent hospitalization ratio was higher in bronchiolitis group (31.8%). Cases of LRTI were more frequent during winter month. The peak month of hospitalization for LRTI was January, February and July, December had a fewest admissions. Antibiotic therapy included the administration of beta lactam agents in 270 patients, cephalosporins in 41, and vancomycin in 6. Conclusion: these results, it would be conceivable to assume that blood cultures are of limited value especially in patients that have received an antibiotic treatment prescribed before admission. Clear associations were found with the history of previous pneumonia and wheezing particularly when hospital care was required.

P157 - PATIENT WITH PULMONARY BLASTOMA - CASE REPORT

K. Jandri_, T. Bara_, N. Petkovic, T. Sko_Aji_, Z. Gojkovic
Clinic of lung disease, Banja Luka, Bosnia and Hercegovina

In Clinical Centre in Banja Luka in last few years there were more than 300 new cases of bronchopulmonal cancers per year. But only one was diagnosed as pulmonary blastoma, mixed tumours of the lung, which contain malignant epithelial and stromal components. Two main varieties have been described-carcinosarcoma and blastoma. Distinction between them is sometimes not properly defined. We confirmed a biphasic pulmonary blastoma in a 58-year-old man. Patient asked for medical help after prolonged symptoms, like cough, hemoptysis and dyspnoea. Chest X-ray examination showed pulmonary infiltration on the right side and bronchoscopes finding was tumour mass in intermediary bronchi. Cytological analysis indicated presence of carcinoma planocellulare. After radical surgical treatment diagnosis was biphasic pulmonary blastoma. After 6 months by routine ultrasound examination was found large suprarenal mass, on the right side. Patient had surgical treatment. Only biopsy of tumour was possible. Analysis showed same mixed tumour, like described in first place. In year 2002, in December patient died, 12 months after initial diagnosis was confirmed. In this case of very rare and malignant tumour, we want to mark this tumour as possible diagnostic and therapeutic challenge, emphasising that it is tumour of big malign potential.
KEY WORDS: mixed tumours of lung, pulmonary blastoma

P158 - LARGE-CELL CARCINOMA OF LUNGS: OUR EXPERIENCE IN DIAGNOSIS AND SURGICAL TREATMENT.

N. Opanasenko, I. Liskina, B. Radionov
Institute of Tuberculosis & Pulmonology

Introduction. Large-cell carcinoma (LCC) of lungs is the rarest 4-th histologic type of lung carcinoma. Cigarette smoking is the predominant cause on LCC. Some studies have suggested a dismal operative treatment results and prognosis even with apparently curative resection. The aim of this study was to study perculiarities of clinic and surgical treatment LCC of lungs. Materials and methods. 26 cases of this pathology were operated last 15 years. 23 patients lived on

Periodicals Class USPS 157-860
ISSN 0012-3692

CHEST
SUPPLEMENT

www.chestjournal.org

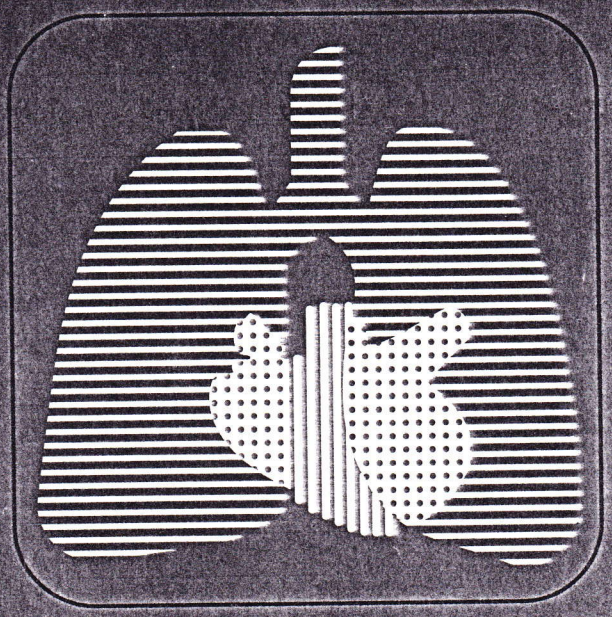

CHEST

THE CARDIOPULMONARY
AND CRITICAL CARE JOURNAL

FOR PULMONOLOGISTS, CARDIOLOGISTS, CARDIOTHORACIC SURGEONS,
CRITICAL CARE PHYSICIANS, AND RELATED SPECIALISTS

17th Asia Pacific Congress on Diseases of the Chest

August 29 - September 1, 2003
Istanbul, Turkey

OFFICIAL PUBLICATION OF
THE AMERICAN COLLEGE OF CHEST PHYSICIANS
3300 Dundee Road, Northbrook, IL 60062-2348
Return Postage Guaranteed