RESEARCH ARTICLE

Araştırma Makalesi

Yazışma adresi
Correspondence address
Cemil OKTAY
Department of Radiology,
Akdeniz University Medical Faculty,
Antalya, Türkiye

cemiloktay@gmail.com

Geliş Tarihi / *Received* : June 18, 2026
Kabul Tarihi / *Accepted* : September 07, 2026
Yayın Tarihi / *Published* : October 28, 2026

Bu makalede yapılacak atıf
Cite this article as
Gunduz D, Ozgur O, Heperenler E, Ozgul I, Oktay C.
Frequency of Transpleural Catheter Passage in Percutaneous Transhepatic Biliary Drainage and Its Relationship with the Access Level: A Single-Center Retrospective Study

Akd Med J 2026;12: 1-7

Demet GUNDUZ
Department of Radiology,
Akdeniz University Medical Faculty,
Antalya, Türkiye

Ozhan OZGUR
Department of Radiology,
Akdeniz University Medical Faculty,
Antalya, Türkiye

Erhan HEPERENLER
Department of Radiology,
Akdeniz University Medical Faculty,
Antalya, Türkiye

Ismail OZGUL
Department of Radiology,
Akdeniz University Medical Faculty,
Antalya, Türkiye

Cemil OKTAY
Department of Radiology,
Akdeniz University Medical Faculty,
Antalya, Türkiye

Frequency of Transpleural Catheter Passage in Percutaneous Transhepatic Biliary Drainage and Its Relationship with the Access Level: A Single-Center Retrospective Study

Perkütan Transhepatik Biliyer Drenajda Transplevral Kateter Geçişinin Sıklığı ve Giriş Seviyesi ile İlişkisi: Tek Merkezli Retrospektif Bir Çalışma

ABSTRACT

Objective

This study aimed to evaluate imaging-detected transpleural catheter passage after right-sided percutaneous transhepatic biliary drainage (PTBD), assess its association with intercostal access level, and investigate associated pleural complications.

Material and Methods

A retrospective analysis was conducted on 286 patients who underwent right-sided PTBD between January 2022 and December 2024. Fifty-eight patients with post-procedural computed tomography available for catheter tract evaluation were included. Access levels were categorized as high (8th-9th and 9th-10th intercostal spaces) or low (10th-11th and 11th-12th intercostal spaces). Transpleural catheter passage and associated pleural complications were analyzed.

Results

The median age was 63 years (IQR, 55–75), and 31% (n=18) of patients were female. Biliary obstruction was malignant in 41 patients (70.7%) and benign in 17 (29.3%). Transpleural catheter passage was identified in five patients. The rate of transpleural catheter passage was 29.4% (5/17) in the high-access group, whereas no cases were observed in the low-access group (0/41; $p<0.001$). Clinically significant pleural complications occurred in two patients, including one hemothorax and one bilothorax.

Conclusion

Transpleural catheter passage after right-sided PTBD may be more common than clinically recognized and is frequently asymptomatic. All cases occurred in procedures performed above the 10th intercostal space, suggesting that more caudal access levels may reduce the risk of pleural violation when anatomically feasible. Therefore, access site selection should be considered an important factor in minimizing pleural complications during PTBD planning.

Keywords

Percutaneous Transhepatic Biliary Drainage, Transpleural Catheter Passage, Bilothorax, Pleural Complications, Intercostal Access

DOI: 10.53394/akd.1973821

Akdeniz Medical Journal is licensed under the Creative Commons Attribution-NonCommercial-ShareAlike 4.0 International License.

ÖZ

Amaç

Bu çalışmanın amacı, sağ taraflı perkütan transhepatik safra drenajı (PTBD) sonrasında görüntüleme ile saptanan transplevral kateter geçişini değerlendirmek, bunun interkostal erişim seviyesiyle ilişkisini incelemek ve ilişkili plevral komplikasyonları araştırmaktır.

Gereç ve Yöntemler

Ocak 2022 ile Aralık 2024 tarihleri arasında sağ taraflı PTBD uygulanan 286 hasta retrospektif olarak değerlendirildi. İşlem sonrası kateter traktının değerlendirilmesine olanak sağlayan bilgisayarlı tomografi incelemesi bulunan 58 hasta çalışmaya dahil edildi. Giriş seviyeleri yüksek giriş (8.-9. ve 9.-10. interkostal aralıklar) ve alçak giriş (10.-11. ve 11.-12. interkostal aralıklar) olarak sınıflandırıldı. Transplevral kateter geçişleri ve ilişkili plevral komplikasyonlar analiz edildi.

Bulgular

Çalışmaya dahil edilen 58 hastanın median yaşı 63 (IQR, 55-75) yıl olup, hastaların %31'i (n=18) kadındı. Biliyer obstrüksiyon 41 hastada (%70,7) malign, 17 hastada (%29,3) benign nedenlere bağlıydı. Beş hastada transplevral kateter geçişi saptandı. Transplevral kateter geçiş oranı yüksek giriş grubunda %29,4 (5/17) iken, alçak giriş grubunda hiçbir olguda saptanmadı (0/41; p<0,001). Transplevral kateter geçişi bulunan hastaların ikisinde klinik olarak anlamlı plevral komplikasyon gelişti; bunlardan biri hemotoraks, diğeri ise bilotoraks idi.

Sonuç

Sağ taraflı PTBD sonrasında transplevral kateter geçişi klinik olarak fark edilenden daha sık görülebilir ve çoğu olguda asemptomatik seyredebilir. Tüm olguların 10. interkostal aralığın üzerindeki girişlerde görülmesi, anatomik olarak uygun hastalarda daha kaudal giriş seviyelerinin tercih edilmesinin plevral boşluğun ihlal edilme riskini azaltabileceğini düşündürmektedir. Bu nedenle PTBD planlamasında giriş yeri seçimi, plevral komplikasyonların en aza indirilmesinde önemli bir faktör olarak değerlendirilmelidir.

Anahtar Kelimeler

Perkütan Transhepatik Biliyer Drenaj, Transplevral Kateter Geçişi, Bilotoraks, Plevral Komplikasyonlar, İnterkostal Giriş

INTRODUCTION

Percutaneous transhepatic biliary drainage (PTBD) is an effective interventional procedure widely used to manage both malignant and benign biliary obstructions (1). Advances in imaging modalities and percutaneous biliary access techniques have made PTBD a safe, effective procedure with high technical success rates. Nevertheless, it may be associated with various complications. The most commonly reported complications are cholangitis, sepsis, and catheter-related problems, including occlusion, migration, and dislodgement, followed by hemobilia and bile leakage (2, 3). Although less common, pleural complications-including pleural effusion, pneumothorax, hemothorax, and bilothorax-remain important sources of morbidity (4-7). Particularly in right-sided approaches, the close anatomical relationship between the catheter tract and the pleural space may result in transpleural catheter passage. While this condition may remain clinically silent in some patients, it can also lead to serious pleural complications (6, 8, 9).

The inferior limit of the parietal pleura within the costophrenic recess extends inferiorly from its highest anterior point behind the xiphoid process, crosses the eighth rib at the costochondral junction, and reaches its lowest level at the tenth rib along the midaxillary line (4, 8). Posteriorly, the inferior pleural reflection extends to approximately the level of the L1 vertebral body. Because of the anatomical relationship between the access site, the diaphragm, and the pleural reflections, inadvertent pleural violation may occur during right-sided hepatic approaches. However, the literature has not adequately characterized the true incidence and clinical consequences of transpleural catheter passage. This study aimed to evaluate imaging-detected transpleural catheter passage after right-sided PTBD, assess its association with intercostal access level, and investigate associated pleural complications.

MATERIALS and METHODS

This retrospective single-center study included patients who underwent right-sided PTBD between January 2022 and December 2024. We included patients with post-procedural cross-sectional imaging (thoracic CT, abdominal CT, or the CT component of PET/CT) available and sufficient to visualize the drainage catheter tract. Except for one patient who underwent CT because of pleural effusion following PTBD, all examinations had been performed for clinical indications unrelated to the biliary drainage procedure. Of the 286 PTBD procedures performed during the study period, cross-sectional imaging suitable for catheter tract evaluation was available in 58 patients, who constituted the study cohort.

All procedures were performed under combined fluoroscopic and ultrasonographic guidance. As a tertiary referral teaching hospital, our institution performed procedures under the supervision of experienced interventional radiologists or interventional radiology trainees. We retrospectively reviewed procedure reports and imaging archives. For each patient, we recorded the intercostal access level. Post-procedural CT examinations and available follow-up fluoroscopic images were independently reviewed by two experienced interventional radiologists. We defined transpleural catheter passage as a catheter tract traversing the pleural space before entering the liver. Patients were classified according to the intercostal access level and evaluated for the presence of transpleural catheter passage. In addition, pleural complications including hemothorax, bilothorax, pneumothorax, requirement for chest tube placement, and need for additional interventions were recorded.

Descriptive statistics were presented as median (interquartile range [IQR]) or number (percentage), as appropriate. For statistical analysis, access levels were dichotomized into a high-access group (8th-9th and 9th-10th intercostal spaces) and a low-access group (10th-11th and 11th-12th intercostal spaces). The association between transpleural catheter passage and access level was analyzed using Fisher's exact test. Statistical analyses were performed using IBM SPSS Statistics for Windows, Version 26.0 (IBM Corp., Armonk, NY, USA). A p value <0.05 was considered statistically significant. Institutional ethics committee approval (decision no: TBAEK-118/ Date: 31.01.2025) was obtained. The requirement for informed consent to participate has been waived because of the retrospective nature of the study.

RESULTS

We performed 286 right-sided PTBD procedures during the study period. Transpleural catheter passage was confirmed in 5 patients, corresponding to an overall rate of 1.7%. Among the 58 patients in whom post-procedural cross-sectional imaging allowed direct evaluation of the catheter tract, 5 had transpleural catheter passage. In this study cohort, 18 patients (31.0%) were female, and the median age was 63 years (IQR, 55-75). Regarding PTBD indications, biliary obstruction was caused by benign disease in 17 patients (29.3%) and by malignant disease in 41 patients (70.7%).

Table I summarizes the distribution of patients by intercostal access level and the occurrence of transpleural catheter passage. The rate of transpleural catheter passage was 29.4% (5/17) in the high-access group (8th–9th and 9th–10th intercostal spaces), whereas no transpleural catheter passage was observed in the low-access group (10th–11th and 11th–12th intercostal spaces) (0/41, 0%). A statistically significant association was found between high intercostal access and transpleural catheter passage (p<0.001). Clinically significant pleural complications developed in two patients with transpleural catheter passage. One patient developed hemothorax and another developed bilothorax. The remaining three patients remained asymptomatic and did not require any additional treatment or intervention (Figures 1-3).

Table I. Distribution of intercostal access levels, patients with imaging-confirmed transpleural catheter passage, and symptomatic patients according to access level

Intercostal Space	n (%)	Transpleural Catheter Passage, n (%)	Symptomatic Patients, n (%)
8th-9th	7 (12.1)	4 (6.9)	1 (1.7)
9th-10th	10 (17.2)	1 (1.7)	1 (1.7)
10th-11th	26 (44.8)		
11th-12th	15 (25.9)		
Total	58 (100)	5 (8.6)	2 (3.4)



Figure 1. Intraprocedural fluoroscopic image obtained during right-sided percutaneous transhepatic biliary drainage demonstrating catheter placement via an intercostal approach (a). Follow-up fluoroscopic image obtained one week after right-sided percutaneous transhepatic biliary drainage demonstrating the catheter tract coursing through the pleural cavity with partial migration of the drainage catheter into the pleural space (b). The findings are consistent with transpleural catheter passage.



Figure 2. Coronal CT image of a patient who developed bilothorax following right-sided percutaneous transhepatic biliary drainage. The drainage catheter is seen traversing the pleural space before entering the hepatic parenchyma, with associated pleural fluid accumulation within the right hemithorax consistent with bilothorax. The findings are compatible with transpleural catheter passage.

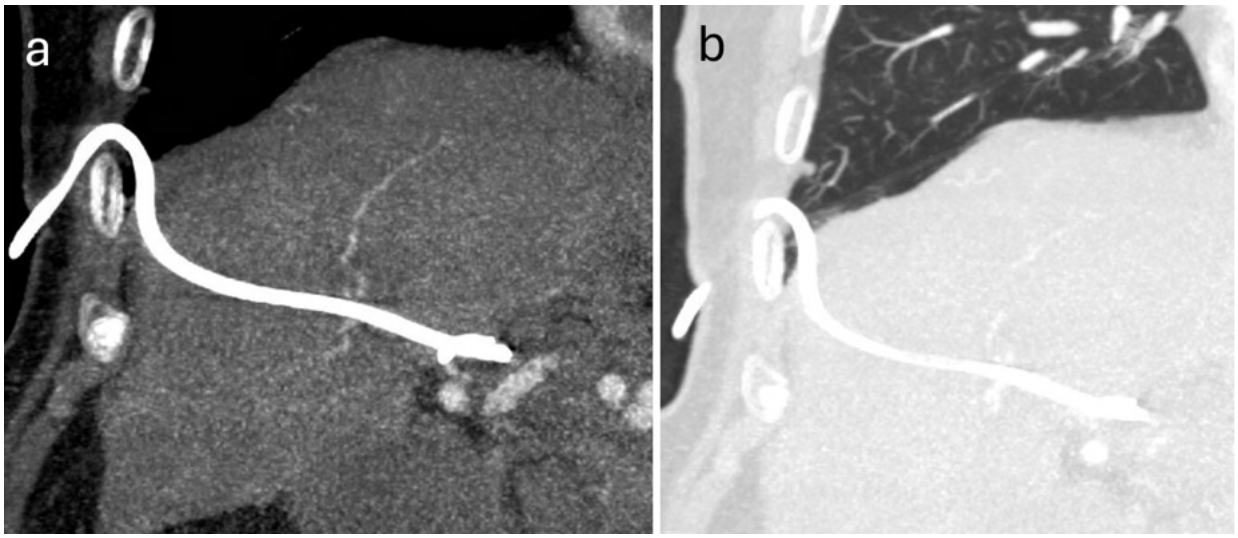

Figure 3. Follow-up CT images of an asymptomatic patient after right-sided percutaneous transhepatic biliary drainage. Coronal images obtained in the mediastinal window (A) and lung window (B) demonstrate the drainage catheter traversing the right lower lobe lung parenchyma and diaphragm before entering the hepatic parenchyma. Despite these imaging findings, no pleural or pulmonary complications developed during follow-up.

DISCUSSION

In this study, we investigated the frequency of transpleural catheter passage, its association with access level, and its clinical consequences in patients who underwent right-sided PTBD and had imaging available to evaluate the catheter tract. The principal findings of our study were that transpleural catheter passage was identified in five patients, exclusively following procedures performed above the 10th intercostal space, and that only two of these patients developed clinically significant pleural complications.

PTBD is widely accepted as a safe and effective interventional procedure with high technical success rates for treating both malignant and benign biliary obstruction (10). Nevertheless, although pleural complications are considered relatively uncommon, transpleural catheter passage may occur, particularly in right-sided hepatic approaches because of the close anatomical relationship between the catheter tract and the pleural space. Most available studies have focused on clinically apparent complications such as pneumothorax, hemothorax, and bilothorax, whereas data regarding the frequency of asymptomatic transpleural catheter passage detected on imaging remain limited.

Unlike previous studies that primarily reported clinically apparent pleural complications, our study directly assessed the catheter tract using post-procedural cross-sectional imaging. This imaging-based approach suggests that transpleural catheter passage may occur more frequently than previously appreciated, as many cases remain clinically silent (4). Notably, only two of the five patients with transpleural catheter passage developed clinically significant complications, whereas the remaining three patients remained completely asymptomatic. This finding suggests that transpleural catheter passage and pleural complications are not synonymous and that violation of the pleural space does not necessarily result in clinically significant sequelae. Consequently, studies focusing exclusively on symptomatic cases may underestimate the true frequency of transpleural catheter passage.

Another important finding was that all cases of transpleural catheter passage occurred in procedures performed through the 8th-9th or 9th-10th intercostal spaces. In contrast, we identified no transpleural catheter passage among the 41 procedures performed through the 10th-11th or 11th-12th intercostal spaces. These findings are consistent with the known anatomical extent of the pleural cavity. At the level of the costophrenic recess, the inferior pleural reflection extends to approximately the 8th–10th ribs anteriorly and to the level of the L1 vertebral body posteriorly (4, 8). Consequently, more cranial intercostal access levels are associated with an increased likelihood of traversing the pleural space.

Although our findings suggest that access below the 10th intercostal space may reduce the risk of transpleural passage, such an approach is not feasible in all patients. Drainage of high-lying segment VII–VIII bile ducts, severe spinal deformities, diaphragmatic positional abnormalities, previous hepatobiliary surgery, liver transplantation-related interventions, and patient-specific anatomical variations may necessitate a more cranial intercostal approach. Therefore, access-level selection should balance the goal of minimizing pleural complications with the need to achieve safe, effective access to the target biliary duct.

Our findings are also consistent with those reported by Nichols et al. (4). In their study, six pleural complications were identified among 230 intercostal procedures performed in the right upper quadrant, with only one case of bilothorax. Cadaveric analysis demonstrated that the pleural reflection extends inferiorly to the level of the 10th rib along the midaxillary line and that all punctures performed through the 9th-10th intercostal space traversed the pleura, diaphragm, and peritoneum before reaching the liver. The authors further suggested that, despite the low frequency of clinically recognized pleural complications, a substantial proportion of needle tracts likely pass through the costophrenic recess and pleural space while remaining inferior to the lung parenchyma. Our findings largely support this hypothesis. However, in one patient (Figure 3), CT imaging showed that the catheter tract traversed not only the pleural space but also the right lower lobe lung parenchyma without causing any clinical symptoms or pleural complications. This observation suggests that even catheter tracts crossing the lung parenchyma may remain clinically silent in selected patients. The absence of clinical manifestations in most patients with transpleural catheter passage further supports the notion that pleural violation may occur more frequently than generally appreciated while remaining clinically occult in many cases. Data regarding the frequency of pleural complications following PTBD remain limited. In a study published by Liu et al., pleural effusion developed in 17 of 175 patients (9.7%) who underwent right-lobe PTBD (11). However, the study did not characterize the nature or etiology of the pleural fluid. The rate of clinically significant pleural complications observed in our study appears lower than the pleural effusion rate reported in that series. Given that many patients undergoing PTBD have advanced malignancy and multiple comorbidities, it is difficult to determine whether pleural effusions are directly attributable to transpleural catheter passage. Therefore, studies based solely on the presence of pleural effusion may not accurately reflect the true frequency of transpleural catheter passage.

One patient with transpleural catheter passage in our cohort developed bilothorax. Bilothorax (thoracobilia or cholethorax) is a rare but potentially serious complication defined as the presence of bile within the pleural cavity (5). The literature on this condition consists predominantly of case reports and small case series (2, 4-9). In a systematic review by Acharya et al. (2024), 115 cases of bilothorax were analyzed, and PTBD was the most common underlying cause, accounting for 23.47% of cases (5). Because the clinical and radiological features of bilothorax often overlap with other causes of pleural effusion, diagnosis frequently requires a high index of suspicion. Consequently, its true frequency may be underestimated. Furthermore, delayed diagnosis may result in pleural inflammation, fibrosis, empyema, and permanent pleural sequelae. Therefore, bilothorax should be considered in the differential diagnosis of unexplained pleural effusions developing after PTBD.

Complications related to pleural violation are not unique to PTBD. Similar complications have been reported following percutaneous abscess drainage, tumor ablation procedures, liver biopsies, and other percutaneous interventions performed near the right hemithorax (12-14). Indeed, Pisani et al. described a case of bilious pleural effusion following liver biopsy (15). These observations suggest that the close anatomical relationship among the liver, diaphragm, and pleural space, rather than the specific procedure itself, underlies many of these complications. Accordingly, careful assessment of the relationship between the planned needle or catheter tract and the pleural space is essential when planning right upper abdominal interventions, and pleural violation should be avoided whenever feasible.

This study has several limitations. First, it was retrospective and single-center. Second, we should acknowledge potential selection bias because post-procedural cross-sectional imaging was not routinely performed after PTBD and was available only in a subset of the cohort. Therefore, the frequency observed in the imaging-evaluable cohort should not be interpreted as the true frequency of transpleural catheter passage in the overall PTBD population. Although the five imaging-confirmed cases represented 1.7% of all 286 PTBD procedures, this figure reflects only the minimum number of identified cases and may underestimate the true frequency because the catheter tract could not be evaluated in the remaining procedures. Finally, because our institution is a tertiary teaching hospital, operators performed procedures with varying levels of experience, and we did not specifically evaluate the influence of operator experience on access-site selection and complication rates.

In conclusion, transpleural catheter passage identified on CT or fluoroscopic imaging following right-sided PTBD may be more common than clinically recognized. These passages were observed predominantly in procedures performed above the 10th intercostal space, suggesting that more caudal access levels may reduce the risk of pleural violation when anatomically feasible. In addition, bilothorax should be considered in the evaluation of pleural effusions developing after PTBD, and prompt diagnosis and appropriate treatment should be provided when necessary.

Ethics Committee Approval
This research complies with all the relevant national regulations, institutional policies and is in accordance with the tenets of the Helsinki Declaration, and has been approved by the Akdeniz Medical Faculty Ethical Committee, Akdeniz University (decision no: TBAEK-118/ Date: 31.01.2025).

Informed Consent
The requirement for informed consent to participate has been waived because of the retrospective nature of the study.

Author Contributions
Concept – D.G., E.H., C.O., Ö.Ö., İ.Ö.; Design - D.G., E.H., C.O., Ö.Ö., İ.Ö.; Supervision - D.G., Ö.Ö., ; Materials - D.G., E.H., C.O., Ö.Ö., İ.Ö.; Data Collection and/or Processing - D.G., E.H., C.O., Ö.Ö., İ.Ö.; Analysis and/or Interpretation - D.G., E.H., C.O., Ö.Ö., İ.Ö.; Literature Search - D.G., E.H., C.O., Ö.Ö., İ.Ö.; Writing Manuscript - D.G., E.H., C.O., Ö.Ö., İ.Ö.; Critical Review - D.G., E.H., C.O., Ö.Ö., İ.Ö.

Conflict of Interest
The authors have no conflict of interest to declare.

Financial Disclosure
The authors declared that this study has received no financial support.

Declaration of AI and AI-Assisted Technologies in the Writing Process
Artificial intelligence (ChatGPT, OpenAI) was used solely to assist with English language editing, grammar correction, and improvement of manuscript readability. The authors reviewed, revised, and approved all generated content and take full responsibility for the final manuscript.

REFERENCES

1. Covey AM, Brown KT. Percutaneous transhepatic biliary drainage. Tech Vasc Interv Radiol. 2008;11(1):14-20.

2. Molina H, Chan MM, Lewandowski RJ, Gabr A, Riaz A. Complications of Percutaneous Biliary Procedures. Semin Intervent Radiol. 2021;38(3):364-72.

3. Antalek M, Patel ME, Knight GM, Malik A, Husnain A, Stiff K, Talwar A, Reiland A, Nemcek AA Jr, Salem R, Riaz A. Adverse events after percutaneous transhepatic biliary drainage: A 10-year retrospective analysis. J Vasc Interv Radiol. 2025;36(4):564-572.e1.

4. Nichols DM, Cooperberg PL, Golding RH, Burhenne HJ. The safe intercostal approach? Pleural complications in abdominal interventional radiology. AJR Am J Roentgenol. 1984;142(5):1013-8.

5. Acharya R, Kafle S, Sedhai YR, Thapa S, Ghimire S, Dhital R, Paudel R. Bilothorax: A case report and systematic literature review of the rare entity. Pulm Med. 2024;2024:3973056.

6. Jayabalan D, Donaghy M, Charlesworth C, Fysh ETH, Lee YCG. Bilothorax Following Percutaneous Transhepatic Biliary Drainage for Cholangiocarcinoma: Recognising the Depth of Pleural Reflections. Respirol Case Rep. 2025;13(7):e70259.

7. Strange C, Allen ML, Freedland PN, Cunningham J, Sahn SA. Biliopleural fistula as a complication of percutaneous biliary drainage: experimental evidence for pleural inflammation. Am Rev Respir Dis. 1988;137(4):959-61.

8. Kim SH, Zangan SM. Percutaneous Transhepatic Biliary Drainage Complicated by Bilothorax. Semin Intervent Radiol. 2015;32(1):54-6.

9. Turkington RC, Leggett JJ, Hurwitz J, Eatock MM. Cholethorax following percutaneous transhepatic biliary drainage. Ulster Med J. 2007;76(2):112-3.

10. Devane AM, Annam A, Brody L, Brown DB, Ganguli S, Gervais DA, Kundu S, Lorenz JM, Saad WEA, Salem R, Singh H, Walker TG, Wojak JC, Cardella JF. Society of Interventional Radiology Quality Improvement Standards for Percutaneous Cholecystostomy and Percutaneous Transhepatic Biliary Interventions. J Vasc Interv Radiol. 2020;31(11):1849-56.

11. Liu YS, Lin CY, Chuang MT, Tsai YS, Wang CK, Ou MC. Success and complications of percutaneous transhepatic biliary drainage are influenced by liver entry segment and level of catheter placement. Abdom Radiol (NY). 2018;43(3):713-22.

12. Avella DM, Toth JW, Reed MF, Stone ME, Fox PS, Aloia TA. Pleural space infections after image-guided percutaneous drainage of infected intraabdominal fluid collections: a retrospective single institution analysis. BMC Surg. 2015;15:42.

13. Kambadakone A, Baliyan V, Kordbacheh H, Katabathina VS, Odisio BC. Imaging guided percutaneous interventions in hepatic dome lesions: Tips and tricks. World J Hepatol. 2017;9(19):840-9.

14. Wu M, Zhu Q, Chen L, Yan D. Bilious pleuritis due to hepatic microwave ablation: Two illustrative cases and literature review. Medicine (Baltimore). 2020;99(44):e22763.

15. Pisani RJ, Zeller FA. Bilious pleural effusion following liver biopsy. Chest. 1990;98(6):1535-7.