Journal of Cardiology Cases (2011) 4, e87—e89

available at www.sciencedirect.com

ScienceDirect

journal homepage: www.elsevier.com/locate/jccase

Case Report

Aorta-right atrial tunnel leading to heart failure

Refik Emre Altekin (MD)[a,*], İbrahim Basarici (MD)[a], Serkan Koc (MD)[b], Murathan Kucuk (MD)[c], Atakan Yanikoglu (MD)[a], İbrahim Demir (PhD)[a]

[a] *Cardiology Department of Akdeniz University Medical Faculty Hospital, Antalya, Turkey*
[b] *Cardiology Department of Agri State Hospital, Agri, Turkey*
[c] *Cardiology Department of Manavgat State Hospital, Manavgat, Antalya, Turkey*

Received 23 November 2010; received in revised form 10 March 2011; accepted 13 June 2011

KEYWORDS
Atrium;
Tunnel;
Aorta

Summary Congential aorta-right atrial tunnel (ARAT) is a rare anomaly. Many patients are asymptomatic and diagnosis can be made during investigation of systolic and diastolic continuous murmur heard on cardiac oscultation. In some patients, symptoms such as palpitation, dyspnea, and fatigue on exertion can be seen. With transthoracic and transesophageal echocardiography diagnosis can usually be made, but more definite diagnosis is possible with coronary angiography, aortography, and computerized tomography. Herein with the data from current literature we will discuss a case who was admitted to our clinic with symptoms of heart failure and diagnosed with ARAT.
© 2011 Japanese College of Cardiology. Published by Elsevier Ltd. All rights reserved.

Introduction

Extracardiac connections between aorta and other chambers of heart are rare congenital anomalies. The most common type of those connections is between aorta and left ventricle. Aorta-right atrial tunnel (ARAT) was firstly defined by Otero and colleagues in 1980 as a fistulation between ascending aorta and right atrium [1]. In our case we discuss a patient who was admitted to our outpatient clinic with symptoms of heart failure and diagnosed as having ARAT.

Case report

A 39-year-old male patient without any known systemic and cardiac disorder was admitted to our clinic with symptoms of progressive dyspnea for 20 days, coughing, malaise, and fatigue. His functional capacity was New York Heart Association class III. On physical examination, he was tachycardic and there were audible S3 and systolo-diastolic continuous murmur along the right sternal border on cardiac oscultation. There were bilateral crackling rales at the base of lungs and decreased respiration sounds at the base of the right lung on respiratory system examination.

On electrocardiography there was only sinusal tachycardia. Both cardiophrenic sinuses were closed, there was a mild increase in pulmonary vascularity and there was an image compatible with right pleural effusion on chest X-ray. Both right and left ventricle sizes and function were normal

* Corresponding author at: Cardiology Department of Akdeniz University Medical Faculty Hospital, Dumlupinar Boulevard, Antalya, Turkey. Tel.: +90 242 2696804; fax: +90 242 2274490.
E-mail address: dremre29@yahoo.com (R.E. Altekin).

1878-5409/$ — see front matter © 2011 Japanese College of Cardiology. Published by Elsevier Ltd. All rights reserved.
doi:10.1016/j.jccase.2011.06.003

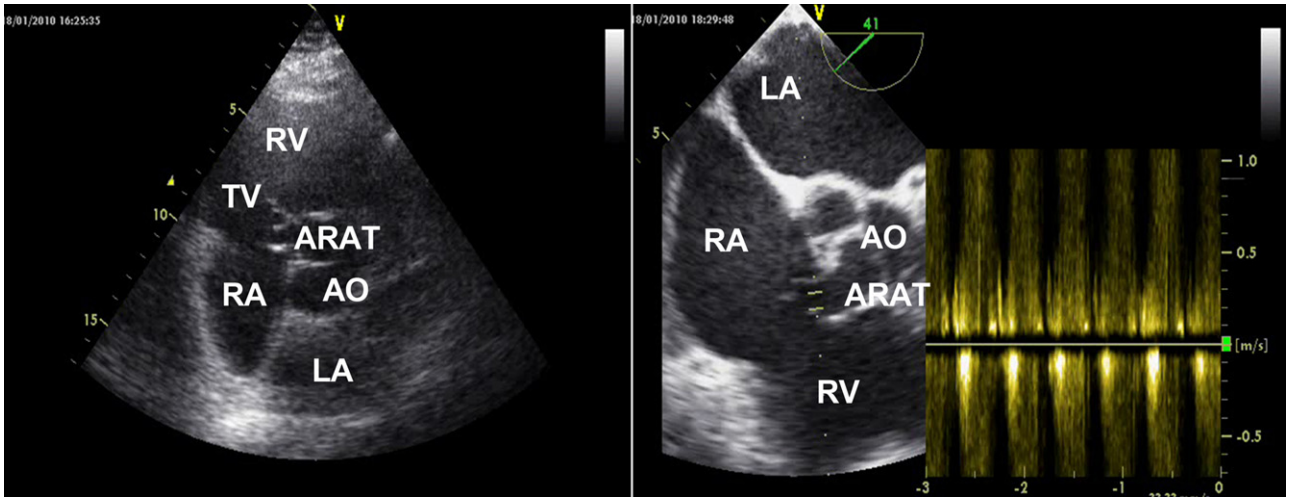

Figure 1 The left panel shows fistulous structure between aorta and right atrium suspected as ARAT at parasternal short axis on transthoracic echocardiography. Right panel shows flow on pulse wave Doppler at the level of ARAT on transesophageal echocardiography. RV, right ventricle; RA, right atrium; LV, left ventricle; LA, left atrium; AO, aorta; ARAT, aorta-right atrial tunnel; TV, tricuspid valve.

but there was a structure lying between right sinus valsalva and right atrium and there was flow from aorta to right atrium on both pulse wave and color Doppler on transthoracic echocardiography (Fig. 1). A fistula was detected lying between right sinus valsalva and right atrium and there was flow from the aorta to right atrium on both pulse wave and color Doppler on transesophageal echocardiography (Fig. 1 and Videos 1 and 2). In order to determine other possible vascular and cardiac abnormalities multislice computerized tomography was performed and a tunnel lying from right atrium and aorta and its origin from aorta were visualized (Fig. 2). In order to evaluate the anatomy of coronary arteries a coronary angiography was performed and all coronary arteries were found to be normal and in aortography there was a fistula track between right coronary sinus and right atrium (Fig. 2). The shunt ratio (Qp/Qs) was 1.5 on catheterization. The patient was referred to the cardiovascular surgery department with a diagnosis of ARAT for operation.

Discussion

The 90% of extracardiac connections between aorta and spaces of the heart are associated with the left ventricle [2]. ARAT is the rarest one of them. In the literature most of them are case reports, but the largest case study with 9 patients was reported by Gajjar and colleagues [3]. The etiology of ARAT is still unclear. Hypothesized mechanisms include a congenital defect of elastic lamina, a mesocardiac cystic structure arising from 5th aortic arch during early intrauterine cardiac development, a supravalvular aneurysmal dilatation of primitive aorta, or an intrauterine rupture of sinus valsalva aneurysm. The posterior type which originates from the left sinus valsalva is more common [4]. The anterior type which has an origination from right sinus valsalva is less common. It can also have an origination from non-coronary sinus.

Many of the patients with ARAT are asymptomatic but palpitations, being easily fatiguable, dyspnea, and recurrent

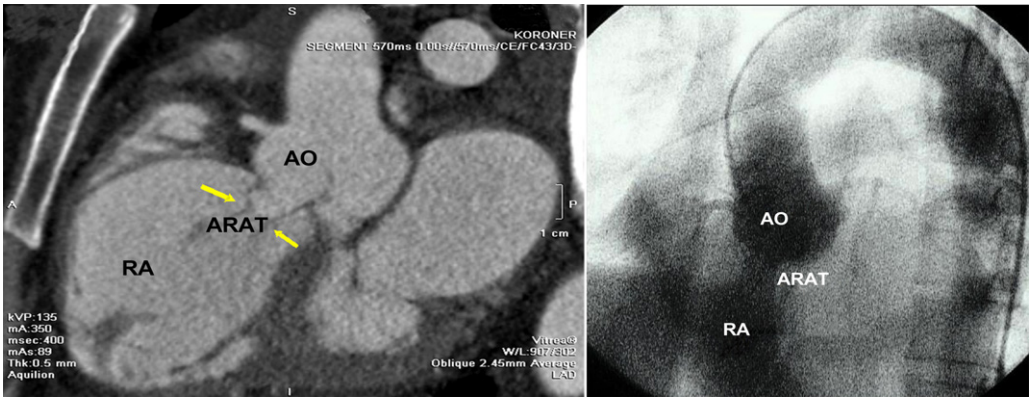

Figure 2 On left panel MCT indicates communication between right sinus valsalva and right atrium with an extracardiac course. Right panel shows contrast passage to right atrium through ARAT on aortography. MCT, multislice computerized tomography; RA, right atrium; AO, aorta; ARAT, aorta-right atrial tunnel.

pulmonary infections can also be seen. The most prominent and most common physical examination finding is continuous murmur along the right sternal border. Echocardiography is usually an adequate tool for diagnosis but tomography, angiography, and aortography are necessary tools for differential diagnosis from ruptured sinus valsalva aneurysm or coronary artery fistula. And also those diagnostic tools are necessary for determination of other accompanying anomalies, exact localization of lesion, and interaction with coronary arteries [3]. In our case, besides echocardiography, we excluded sinus valsalva aneurysm with intact appearance of sinus valsalva on tomography, and we excluded coronary artery fistula with absence of contrast passage to a second space and normal coronary anatomy with angiography and aortography.

Treatment is recommended for patients with ARAT even if they are asymptomatic because of the risk of infective endocarditis, heart failure, aneurysm development, spontaneous rupture, pulmonary vascular disease, and high risk of probable surgery in the future [3]. Usually surgery is recommended for opportunity to repair accompanying anomalies, but in the literature there are 2 cases in childhood ages treated with coil embolization [5]. The surgical technique is usually planned taking into account the ARAT's localization, size, and interaction with coronary ostia. Usually surgery is aimed at removal of the connection between right atria, primary repair of right atrium, closing of the aortic side with patch, and if necessary reconstructing coronary ostia [6,7].

Appendix A. Supplementary data

Supplementary data associated with this article can be found, in the online version, at doi:10.1016/j.jccase.2011.06.003.

References

[1] Otero-Coto E, Caffarena JM, Such M, Marques JL. Aorta-right atrial communication; report of an unusual case. J Thorac Cardiovasc Surg 1980;80:941—4.
[2] Fernandes ED, Kadivar H, Hallman GL, Reul GJ, Ott DA, Cooley DA. Congenital malformations of the coronary arteries; the Texas Heart Institute experience. Ann Thorac Surg 1992;54:732—40.
[3] Gajjar T, Voleti C, Matta R, Iyer R, Dash PK, Desai N. Aorta-right atrial tunnel: clinical presentation, diagnostic criteria and surgical options. J Thorac Cardiovasc Surg 2005;130:1287—92.
[4] Rosenberg H, Williams WG, Trusler GA, Smallhorn J, Rowe RD, Moes CA, Freedom RM. Congenital aortico-right atrial communications. The dilemma of differentiation from coronary-camaral fistula. J Thorac Cardiovasc Surg 1986;91:841—7.
[5] Madhu S, Baruah B, Dash PK. Aorta-right atrial tunnel-a novel therapeutic option. Int J Cardiol 2006;107:410—2.
[6] Turkay C, GolbaSi I, Belgi A, Tepe S, Bayezid O. Aorta-right atrial tunnel. J Thorac Cardiovasc Surg 2003;125:1058—60.
[7] Kursaklioglu H, Iyisoy A, Celik T, Kose S, Amasyali B, Isik E. Aortico-right atrial tunnel in an adult patient. Int J Cardiovasc Imaging 2005;21:383—5.