Peker *et al.*
Egyptian Journal of Medical Human Genetics (2025) 26:44
https://doi.org/10.1186/s43042-025-00674-y

Egyptian Journal of Medical Human Genetics

RESEARCH Open Access

Insights on 7p21 deletion including the TWIST1 gene: a case report of an adult patient with macroglossia and a literature review

Alp Peker[1*], Özden Altıok Clark[1], Mert Coşkun[1], Ali Duru[1], Feyza Altunbaş Yalabık[1], Duygu Gamze Aracı[1], Aslı Toylu[1], Sezin Yakut Uzuner[2], Alper Tunga Derin[3] and Ercan Mıhçı[4]

Abstract

Background This study presents an adult 7p21 deletion patient, including a literature review specific to 7p21 deletion, and concludes recommendations toward such patients. A 47-year-old male with moderate-to-severe learning disability and significant dysmorphic features was seen in our Medical Genetics clinic. Initially, a chromosome analysis was requested considering a pre-diagnosis of Down syndrome with adult age, and other chromosomal abnormalities.

Results In karyotype analysis, one chromosome 7 was observed to have a deletion on its short arm. Subsequently, single nucleotide polymorphism array (SNP Array) analysis was pursued to confirm the abnormality seen in the chromosome analysis and to elucidate its details. The results indicated a 16-megabase loss in the 7p21.3-p15.3 regions.

Conclusions Patients with deletions of the short arm of chromosome 7 may exhibit various phenotypic features, including case-specific anomalies. Common abnormalities often linked to the heterozygous loss of 7p21 include a wide nasal bridge and ear shape abnormalities. Our 47-year-old patient presented with macroglossia and dysmorphic traits, suggesting macroglossia as a potential clinical finding for follow-up in adults. Further research is needed to confirm if all such specific anomalies are due to 7p genetic material loss.

Introduction

Heterozygous loss-of-function mutations of the human TWIST1 gene are associated with multiple diseases, including Saethre–Chotzen syndrome, and it is shown in the literature that the loss of one TWIST1 gene copy in humans is associated with a distinct phenotype characterized by a variety of malformations including craniosynostoses, along with many other dysmorphic features such as high and flat forehead, ptosis, small low-set ears, and hypoplasia of the maxilla [1]. The mechanism of pathogenicity, causing an autosomal dominant inheritance for TWIST1 mutations, is haploinsufficiency rooting from either degradation of the protein or mislocalization on the subcellular level [2]. Aberrations in the calvarial ossification have been shown in studies of TWIST1 knockout animal models as well [3].

The deletion of the short arm of chromosome 7 in humans involving the chromosomal location of 7p21.1, where the TWIST1 gene is located, is associated with manifestations of Saethre–Chotzen syndrome and varying degrees of neurodevelopmental problems [4].

*Correspondence:
Alp Peker
alpeker96@gmail.com
[1] Department of Medical Genetics, Akdeniz University Medicine Faculty, Antalya, Turkey
[2] Department of Medical Biology, Akdeniz University Medicine Faculty, Antalya, Turkey
[3] Department of Otolaryngology, Akdeniz University Medicine Faculty, Antalya, Turkey
[4] Department of Pediatric Genetics, Akdeniz University Medicine Faculty, Antalya, Turkey

Springer Open

© The Author(s) 2025. **Open Access** This article is licensed under a Creative Commons Attribution 4.0 International License, which permits use, sharing, adaptation, distribution and reproduction in any medium or format, as long as you give appropriate credit to the original author(s) and the source, provide a link to the Creative Commons licence, and indicate if changes were made. The images or other third party material in this article are included in the article's Creative Commons licence, unless indicated otherwise in a credit line to the material. If material is not included in the article's Creative Commons licence and your intended use is not permitted by statutory regulation or exceeds the permitted use, you will need to obtain permission directly from the copyright holder. To view a copy of this licence, visit http://creativecommons.org/licenses/by/4.0/.

Because adults with genetic syndromes may exhibit distinct phenotypes and symptoms from those observed in children, it is essential to describe an adult syndromic case. Accurate diagnosis and treatment are often complicated by the fact that clinical manifestations of many genetic conditions can evolve over time, and become more subtle, delayed, or change. Co-morbidities or secondary health problems are not as obvious in younger populations, like organ dysfunction, neurodegeneration, or even mental illnesses, may develop in adult cases. Therefore, early intervention, more individualized care, and better outcomes for adult patients can result from acknowledging and fully documenting the variability in presentation. Additionally, documentation of adult cases also enhances the broader understanding of how certain genetic conditions progress, informing both clinical practice and research.

Here, in this case report, we present an adult 7p deletion patient who exhibits several dysmorphic features, intellectual disability of moderate to severe, and additionally, aberrant macroglossia causing respiratory problems and sleep apnea, which is not seen in another 7p deletion patient regarding the review of the literature data.

Material and method

The standard evaluation process for patients with multiple congenital anomalies calls for a chromosome analysis to begin with. Hence, a peripheral blood sample was obtained from the patient, and a conventional karyotype analysis was performed on the sample by G-banding (GTG), through phytohemagglutinin stimulation, treatment with Colchicine and acetic acid/methanol fixation, and Giemsa staining of chromosomes of peripheral blood cells in metaphase stage. A minimum of twenty metaphase plates from the patient's slide were evaluated on 550 band-level GTG. DNA extraction from white blood cells of the peripheral blood sample of the patient was performed by using Lab-Aid 824 s Blood DNA Extraction Kit (Xiamen Zeesan Biotech Co., Ltd.). Secondly, regarding the chromosomal analysis results, an SNP Array test was requested. Infinium Global Screening Array with Cytogenetics-24 v1.0 BeadChip assay for genome-wide cytogenetic analysis was used for SNP Array testing, in accordance with the manufacturer's guide. Later analysis and genotype calling were carried out via Illumina software. The N_xClinical Software, Genomic Variant Detection Software, was utilized for copy number variant screening, and pathogenic variants were reported applying the technical standards for the interpretation and reporting of constitutional copy number variants [5].

To rule out possible translocations or cryptic terminal deletions, FISH analysis for subtelomeric regions of the short arm of chromosome 7 was conducted on metaphase slides of the patient's peripheral blood lymphocytes using Cytocell's subtelomere-specific probes for chromosome 7pter (109a6, RH104000, RH104000, No. LPT 07PR/G), according to standard protocol. Metaphase plates were viewed with the Zeiss Imager M1 Axio fluorescence microscope (Carl Zeiss), and images were captured and analyzed using the MetaSystems ISIS software. Literature data were reviewed through NCBI PubMed and Google Scholar services.

Case description

A 47-year-old male presenting with macroglossia and hypertrophy of the basal part of his tongue was seen by the otolaryngology clinic of our hospital and was led to our clinic with conspicuous facial features and moderate-to-severe intellectual disability. It was stated that he had a depressed nasal bridge, and he had a deviation toward the right in the posterior area. His palate was dome-shaped, and he had a post-nasal drip. He and his family were also told that he might need a surgical intervention due to his macroglossia.

Upon initial clinical evaluation, he had dysmorphic features of brachycephaly, hypertelorism, epicanthal folds, bulbous nasal tip, mandibular prognathism, macroglossia, low-set dysplastic ears, low posterior hairline, and an irregular anterior hairline with a narrow forehead.

Short broad fingers, proximally located thumbs, enlarged second toes, and nail dystrophy were seen in physical examination.

His general appearance included truncal obesity with short stature, a short neck and excessive nuchal skin, and an upturned upper lip with an upturned left corner of the mouth overall causing an appearance of facial asymmetry.

By the time, he was referred to our clinic, he had a history of arrhythmia, and an operated cataract, additionally, there was a bone flap replacement with a graft from a left rib, and a platinum prosthesis implant in his cervical region due to a childhood post-fall surgery.

An echocardiogram performed showed mild hypertrophy evident in the left ventricular apex, and it was stated that there was a concordant connection between atrial and ventricular chambers. A follow-up echocardiogram indicated left ventricular hypertrophy with possible right ventricular hypertrophy and identified diffuse ST wave abnormalities.

The patient presented with a severe neurodevelopmental disorder, able to form only 3 to 4 words. Thus, the comprehensive history was taken from the patient's father. And as he stated, our patient had started walking when he was three or four years old. There was no parental consanguinity, he had no siblings, and there was

no any other relatives with similar conditions within the family.

With the clinical history and dysmorphic features taken into account, a chromosome analysis was requested as a first-line diagnostic tool, with the possible pre-diagnosis of a possible chromosomal abnormality, including an undiagnosed Down syndrome. Ciliopathy syndromes, Alström syndrome, and overgrowth diseases were also heeded for differential diagnosis. Tests for urine mucopolysaccharides and blood lysosomal enzymes were also requested considering the potential lysosomal storage diseases, which all yielded normal results. Craniofacial X-ray imaging was performed to assess the patient's brachycephaly and facial asymmetry (Fig. 1).

Results

As a result of the karyotype analysis, a deletion on the short arm of one chromosome 7 was revealed (Fig. 2). Later, SNP Array analysis was requested to confirm and detail the abnormality seen on chromosome analysis, showing a 16 megabases-long loss of 7p21.3-p15.3 chromosomal regions (GrCh37:7:7,446,319–24,105,209). FISH analysis for the 7p terminal region was also performed, resulting normally, to evaluate possible cryptic terminal deletions.

Regarding these results, a chromosome analysis of his parents was performed, revealing our patient's diagnosis as "de novo" with each parent showing a normal karyotype.

The heterozygous copy number loss in our patient, previously determined by the conventional cytogenetic method, spanned approximately 16 Mb across 7p21.3-p15.3 regions. This wide genomic area encompasses 55 protein-coding genes, 12 of which are identified to be morbid. When these morbid genes (*AGR2, GLCCI1, NDUFA4, TMEM106B, CRPPA, AHR, TWIST1, DNAH11, IL6, HYCC1, KLHL7, GPNMB*) were examined, it was determined that heterozygous loss of the *TWIST1* gene was expected to cause such clinical manifestations and was consistent with the patient's clinic.

The *TWIST1* gene is associated with Saethre–Chotzen syndrome with an autosomal dominant inheritance pattern and is thought to be the culprit of the craniosynostosis observed in patients with large 7p deletions [6]. There are data in the literature indicating the TWIST1 gene's haploinsufficiency [7–9]. Based on the data and the patient's multiple test results, the copy number loss determined in this case was classified as a "pathogenic" change.

Discussion

Part 1.—Review of the literature for 7p21 deletion patients and recommendations

We searched for other patients with 7p21 deletion involving the TWIST1 gene, whose dysmorphic features were detailed in the literature. In accordance with PRISMA for individual patient data systematic reviews (PRISMA-IPD) guidelines, our investigation led us to five similar patients, in terms of the deletion location in the chromosome, whom we could evaluate together [10]. There have been identified many patients with TWIST1 gene deletion throughout the years in different clinics; however, a big portion of these patients was diagnosed with Saethre-Chotzen syndrome only, and no wider deletion was shown as a chromosomal abnormality. Also, some of the patients in the literature have been identified with much

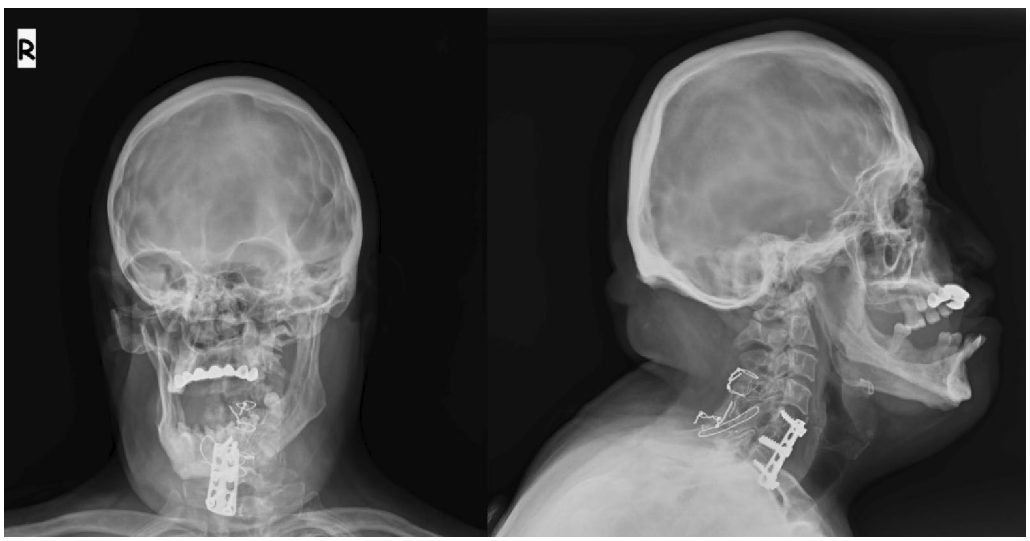

Fig. 1 Patient's craniofacial X-ray images showing signs of craniosynostosis

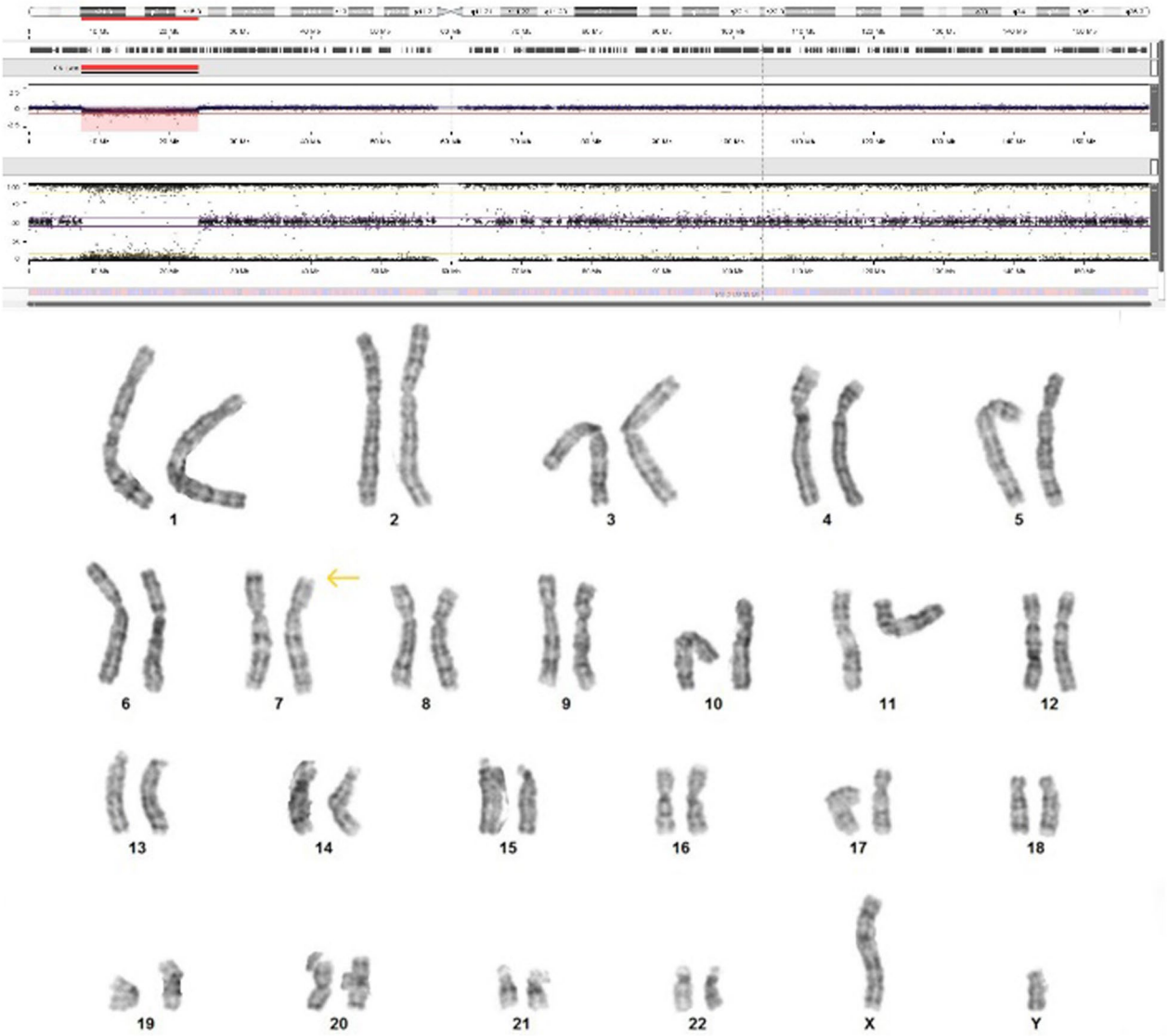

Fig. 2 Patient's chromosome analysis and SNP Array images showing the heterozygous copy loss of 7p21.3-p15.3 regions

larger deletions including some other important haplodeficiency-sensitive genes, making the patients' clinical picture much more complex to be included with our patient for the review when comparing their findings and clinical history. Eventually, the data of the cases with 7p21 deletion throughout the literature who had their dysmorphic findings and patient history well defined, whose deletion did not reach the 7p15.2 area containing the HOXA genes, were selected to be included and reviewed in Table 1.

As can be seen in Table 1, the most striking phenotypical feature of these patients of 7p21 deletion was the wide nasal root, seen in all patients. Along with that, all patients had an ear abnormality whether if it was low-set small dysplastic ears or prominent crus, upturned lobules, or various shape abnormalities. Since all patients in the review appear to have a wide nasal root and an ear abnormality, it is easy to say that these two features are definitely to look for when diagnosing a patient with 7p deletion. Furthermore, five of six patients were observed to have the dysmorphic features of ptosis, arched eyebrows, hypertelorism, and epicanthal folding. A greater percentage of patients had intellectual disability and started walking at a late age. This means that physical therapy starting at early age and special tutoring will be of utmost importance for these patients.

When reviewing other features, we observed brachydactyly, clinodactyly, and simian crease of the hands

Table 1 Showing patient data from different cases, all are identified to have a heterozygous copy loss in the 7p21 chromosomal area involving the TWIST1 gene [6, 11, 12]. Multiple case-specific findings were not described in the table, such as macroglossia of P1, hypoplastic kidney of P3, and hypodontia of P6

	P1 (Peker A.)	P2 (PMID: 23,958,897, Cho E.)	P3 (18,255,367, Schluth-Bolard C.)	P4 (21,333,765, Busche A.)	P5 (21,333,765, Busche A.)	P6 (21,333,765, Busche A.)
Mutation position	arr7p21.3-p15.3(7,446,319–24,105,209) × 1	arr7p21 .1p15.3(15,957,375–20,331,837) × 1	Array result: 690 kb deletion in 7p21.3 + 2p:7p translocation	arr 7p21.2p15.2 (15,332,314–26,990,434)1	arr 7p21.1 (19,030,013–19,556,598)1	arr 7p21 .2p15.2(16,962,368–26,139,032)1
Gender	M	M	M	F	F	M
Intellectual ability	Severe ID	U	Severe ID	Severe ID	Normal	Profound ID
Age of walking (months)	U	U	15	24	16	24
Hypertelorism	Yes	Yes	No	Yes	Yes	Yes
Epicanthal folds	Yes	No	Yes	Yes (inversus)	Yes	Yes
Arched eyebrows	Yes	Yes	Yes	Yes	Yes	No
Ptosis	Yes	No	Yes (bilateral)	Yes (bilateral)	Yes (left)	Yes (bilateral)
Wide nasal root	Yes	Yes	Yes	Yes	Yes	Yes
Ear anomaly	Low-set dysplastic	Low-set ears, prominent crura	Low-set ears, upturned lobule, prominent crura	Small dysplastic	Low-set posterior angulated	Small dysplastic, abnormal helical shape
Philtrum abnormality	No	Flat	Long	Long + flat	Flat	No
Nuchal abnormality	Short neck / excess nuchal skin	U	Short neck / excess nuchal skin	No	No	Short neck / excess nuchal skin
Brachydactyly	Yes	No	Yes	No	No	Yes
Clinodactyly	Yes	No	Yes	Yes	Yes	No
Simian Crease	Yes	Yes	Yes	No	No	Yes

as the main extremity abnormalities of 7p21 deletion patients. Aside from all these findings, there were case-specific abnormalities. Patient 3 had syndactyly of right-hand fingers, left hypoplastic kidney, and cryptorchidism, and patient 6 had hypodontia, as findings not observed in other patients. It should be noted that the patient evaluated by Schluth-Bolard C. (Patient 3) also was a carrier of a complex chromosomal rearrangement of a translocation between 2 and 7p. Having a deletion nearly just as wide as a 0,7 megabase, the urinary pathologies of patient 3 might also be associated with the complex chromosomal abnormality they carry, including the translocation breakpoints within 2p and 7p. Nonetheless, observing such case-specific clinical findings, it is very important to have a full body check-up of patients when they are identified to have a 7p21 deletion.

We recommend that along with the X-ray imaging of the cranium, and a neurological evaluation of the patients are needed, especially by experienced clinicians of a neurology department.

Since it is in the very nature of craniosynostosis to possibly pressure optic chiasma and cranial nerves associated with hearing, it is essential to have a hearing test performed and an evaluation by ophthalmologists for possible visual impairment.

We suggest an abdominal and pelvic ultrasound be performed as such specific cases are present with urological complications.

Psychological aid to both the patient and the parents is necessary as 7p21 deletion includes intellectual aspects.

Part 2.—Macroglossia

With the patient's findings and genetic test results, our patient is confirmed to be diagnosed with monosomy 7p. To our knowledge, at the age of 47, our patient may be the oldest individual to be diagnosed with 7p deletion syndrome, thus our patient's clinical history is surely valuable for patients who are yet to be diagnosed and evaluated. Our patient seems to have very similar facial features to other patients observed throughout the years but he appears to be the only patient with 7p deletion syndrome with the clinical feature of aberrant macroglossia requiring surgical intervention. The patient is currently using a CPAP (continuous positive airway pressure) mask as he was recently diagnosed with sleep apnea due to macroglossia. Further interventions are to be planned to evaluate the CPAP treatment.

At the time of the patient's visit to our clinic, a surgery for macroglossia was the issue of debate for the patient. However, for a number of reasons, operating on a patient who has an intellectual disability can be especially difficult. Individuals with intellectual disabilities may struggle with resistance, anxiety, or cooperation issues. Medical personnel may find it more difficult to gather accurate medical histories or to fully explain the procedure and its risks. Furthermore, these patients might have respiratory or cardiovascular disorders that coexist, which could raise their anesthesia-related risk and complications following surgery. Adherence to post-operative care instructions may also be impacted by behavioral or cognitive limitations, which could result in complications or a slower rate of recovery. Thus, a customized, patient-focused strategy is necessary to guarantee the optimal security and comfort.

Patient's SNP Array data was searched for specific genes or chromosomal loci linked to macroglossia or overgrowth diseases, however, no data was found in the literature for such association. Future investigations and case reports might elucidate if any relation between macroglossia and genomic areas that lie within our patient's chromosomal deletion area (GrCh37:7:7,446,319–24,105,209) may exist or not. However, as we can see in the literature review (Table 1), patients with 7p deletion appear to have phenotypic changes that are only observed on a case level, which could mean that macroglossia seen in our patient might be one of these case-specific abnormalities as well.

A patient's distinct genetic composition or environmental exposures may result in uncommon or unexpected growth patterns, skeletal abnormalities, or atypical responses to medication. Since these abnormalities might not correspond with frequently seen patterns in larger patient populations, they can make diagnosis and treatment more difficult. Thus, it is essential to comprehend such case-specific abnormalities in order to customize individualized medical care, guarantee precise diagnoses, and select the best interventions based on the individual's unique clinical presentation.

The observation of this novel feature in just one individual may not be representative of the wider population, and further studies involving larger cohorts are needed to determine whether macroglossia is a recurrent or rare manifestation in this syndrome. Additionally, the absence of other similar cases limits the ability to assess the potential genetic or environmental factors contributing to this unique presentation. As macroglossia can be associated with various clinical conditions, including amyloidosis, where the deposition of amyloid proteins in tissues can lead to organ enlargement, including the tongue, further assessment of the tissue is needed. However, there are risks and benefits to consider for a biopsy or a surgery in our case. Especially, post-operative care related complications make such invasive actions questionable.

Part 3.—Differential diagnosis and findings

Taking a wide range look at patients described in the literature, we see that 7p deletion patients might present with urogenital malformations if the deletion includes the HOXA gene cluster in the 7p15.2 region [13]. The cluster of HOXA gene, particularly HOXA13, has been associated with a phenotype named hand-foot-genital syndrome in the literature with features of hypoplasia of the first-digit and distal genitourinary tract malformations [14]. Furthermore, the addition of region 7p13 into the deletion is associated with Greig cephalopolysyndactyly syndrome due to the heterozygous loss of the GLI3 gene [15]. Our patient's deletion does not involve these regions; therefore, we have not observed specific findings related to these phenotypes such as urogenital malformations or polysyndactyly in physical examination. However, it must be said that an urogenital examination or a close-up look for digital anomalies should be performed when patients are diagnosed with having a large deletion of the chromosome 7p.

Upon the patient's initial visit to our clinic, he had exhibited characteristic features often associated with the adult phenotype of Down syndrome, including his brachycephaly, dysplastic low-set ears, broad nasal bridge, and excess nuchal skin. We would like to recommend that during the evaluation of adult patients with such dysmorphic features, 7p deletion should be considered as a part of differential diagnosis.

Significant physiological and anatomical changes that affect a person's phenotypic features can happen as they grow from childhood into adulthood. Differences in physical appearance, muscle mass, and fat distribution can result from these changes, which can also include changes in skeletal structure, skin elasticity, hormone regulation, and body composition. For instance, secondary sexual traits like breast development in females or facial hair in males can emerge during puberty. These modifications may result in new differential diagnoses and alter how some medical conditions manifest. In adulthood, a wider range of diagnostic considerations may be necessary due to the emergence or evolution of conditions like hormonal imbalances, joint disorders, or dermatological concerns. Because new phenotypic traits need to be carefully considered during the transition period, clinical assessment may change. There is a lack of continuous clinical care for our patient. A longitudinal follow-up over a long period of time is important for such patients to clearly identify the changes, and therefore, to evaluate new findings and differential diagnoses related to these findings.

Conclusion

Patients with deletions of the short arm of chromosome 7 might present with various phenotypical features, correlating with the regions the deletion is involving. It is seen that wide nasal bridge and various ear shape abnormalities are the most common, maybe essential, to the heterozygous loss of 7p21. Our patient, at the age of 47, was forwarded to our clinic with aberrant macroglossia and dysmorphic features, making macroglossia a possible new clinical finding of 7p deletion syndrome of adult age; however, there are multiple case-specific dysmorphic features pointed out in the literature, yet to be discovered if all such anomalies are arising from the loss of genetic material in chromosome 7p. As more patients are diagnosed and followed up to adult ages, phenotypical features and the progression of the disease over the years will be better understood.

Supplementary Information

The online version contains supplementary material available at https://doi.org/10.1186/s43042-025-00674-y.

Additional file 1.

Acknowledgements

We would like to thank the patient's family for their continuous interest and helpfulness involving the patient's genetic studies. OpenAI (2023), ChatGPT (May 24 version) [Large language model]. https://chat.openai.com/chat has been used for simple language correction.

Author contributions

Alp Peker helped in writing of the study, clinical assessment of patient, and literature review. Özden Altıok Clark involved in chromosome analysis and SNP array analysis of the patient and provided general writing aid. Mert Coşkun and Ali Duru done clinical assessment of the patient in Medical Genetics clinic and contributed to the literature review writing. Feyza Altunbaş Yalabık completed SNP Array analysis, prepared report of the patient, and contributed to the literature review writing. Duygu Gamze Aracı conducted SNP Array analysis and prepared the report of the patient along with general writing aid. Aslı Toylu performed clinical assessment of the patient in Medical Genetics clinic and contributed to general writing aid. Sezin Yakut Uzuner conducted FISH analysis of patient and provided general writing aid. Alper Tunga Derin carried out the clinical assessment of the patient in Otolaryngology clinic. Ercan Mıhçı carried out the clinical assessment of the patient in Pediatric Genetics clinic and helped in defining dysmorphic findings.

Funding

No funding was received for this publication.

Availability of data and materials

More data and material can be made available on reasonable request.

Declarations

Ethics approval and consent to participate

Consent forms for data and image publication have been taken from the patient's legal guardians (patient's parents). Ethical committee approval was taken from Akdeniz University Medicine Faculty with number; 03.01.2025/Decision No:12.

Consent for publication
Consent form from patient's legal Guardian (patient's father) was taken (consent form number: 70.01.08.15.04, test consent form document code HD.RB.901, revision 00).

Competing interests
None of the authors declare a conflict of interest.

Received: 5 July 2024 Accepted: 14 February 2025
Published online: 08 March 2025

References

1. Qin Q, Xu Y, He T et al (2012) Normal and disease-related biological functions of Twist1 and underlying molecular mechanisms. Cell Res 22:90–106. https://doi.org/10.1038/cr.2011.144
2. El Ghouzzi V, Legeai-Mallet L, Aresta S, Benoist C, Munnich A, de Gunzburg J, Bonaventure J (2000) Saethre-Chotzen mutations cause TWIST protein degradation or impaired nuclear location. Hum Mol Genet 9(5):813–819. https://doi.org/10.1093/hmg/9.5.813
3. Craniofacial abnormalities in a murine model of Saethre-Chotzen Syndrome https://doi.org/10.1016/j.aanat.2019.05.011
4. Alawneh RJ, Johnson AL, Hoover-Fong JE, Jackson EM, Steinberg JP, MacCarrick G (2023) Postnatal progressive craniosynostosis in syndromic conditions: two patients with saethre-chotzen due to TWIST1 gene deletions and review of the literature. Cleft Palate Craniofac J 60(8):1021–1028. https://doi.org/10.1177/10556656221090844
5. Riggs ER, Andersen EF, Cherry AM, Kantarci S, Kearney H, Patel A, Raca G, Ritter DI, South ST, Thorland EC, Pineda-Alvarez D, Aradhya S, Martin CL. Technical standards for the interpretation and reporting of constitutional copy-number variants: a joint consensus recommendation of the American College of Medical Genetics and Genomics (ACMG) and the Clinical Genome Resource (ClinGen). Genet Med. 2020;22(2):245–257. https://doi.org/10.1038/s41436-019-0686-8. Epub 2019 Nov 6. Erratum in: Genet Med. 2021;23(11):2230. https://doi.org/10.1038/s41436-021-01150-9. PMID: 31690835; PMCID: PMC7313390.
6. Busche A, Graul-Neumann LM, Zweier C, Rauch A, Klopocki E, Horn D (2011) Microdeletions of chromosome 7p21, including TWIST1, associated with significant microcephaly, facial dysmorphism, and short stature. Eur J Med Genet 54(3):256–261. https://doi.org/10.1016/j.ejmg.2011.02.002
7. Kress W, Schropp C, Lieb G, Petersen B, Büsse-Ratzka M, Kunz J, Reinhart E, Schäfer WD, Sold J, Hoppe F, Pahnke J, Trusen A, Sörensen N, Krauss J, Collmann H (2006) Saethre-Chotzen syndrome caused by TWIST 1 gene mutations: functional differentiation from Muenke coronal synostosis syndrome. Eur J Hum Genet 14(1):39–48. https://doi.org/10.1038/sj.ejhg.5201507
8. de Heer IM, de Klein A, van den Ouweland AM, Vermeij-Keers C, Wouters CH, Vaandrager JM, Hovius SE, Hoogeboom JM (2005) Clinical and genetic analysis of patients with Saethre-Chotzen syndrome. Plast Reconstr Surg 115(7):1894–1902. https://doi.org/10.1097/01.prs.0000165278.72168.51. (**discussion 1903-5**)
9. Ko JM, Jeong SY, Yang JA, Park DH, Yoon SH (2012) Molecular genetic analysis of TWIST1 and FGFR3 genes in Korean patients with coronal synostosis: identification of three novel TWIST1 mutations. Plast Reconstr Surg 129(5):814e–821e. https://doi.org/10.1097/PRS.0b013e31824a2dda
10 Stewart LA, Clarke M, Rovers M, Riley RD, Simmonds M, Stewart G, Tierney JF (2015) PRISMA-IPD Development Group. Preferred reporting items for systematic review and meta-analyses of individual participant data: the PRISMA-IPD statement. JAMA 313(16):1657–1665. https://doi.org/10.1001/jama.2015.3656
11. Cho E, Yang TH, Shin ES, Byeon JH, Kim GH, Eun BL (2013) Saethre-Chotzen syndrome with an atypical phenotype: identification of TWIST microdeletion by array CGH. Childs Nerv Syst 29(11):2101–2104. https://doi.org/10.1007/s00381-013-2235-0
12. Schluth-Bolard C, Till M, Labalme A, Rey C, Banquart E, Fautrelle A, Martin-Denavit T, Le Lorc'h M, Romana SP, Lazar V, Edery P, Sanlaville D (2008) TWIST microdeletion identified by array CGH in a patient presenting Saethre-Chotzen phenotype and a complex rearrangement involving chromosomes 2 and 7. Eur J Med Genet 51(2):156–164. https://doi.org/10.1016/j.ejmg.2007.12.003
13. Kosaki R, Higuchi M, Mitsui N, Matsushima K, Ohashi H, Kosaki K (2005) Deletion involving the TWIST locus and the HOXA cluster: a contiguous gene syndrome on 7p? Congenit Anom (Kyoto) 45(1):35–38. https://doi.org/10.1111/j.1741-4520.2005.00059.x
14. Goodman FR, Bacchelli C, Brady AF, Brueton LA, Fryns JP, Mortlock DP, Innis JW, Holmes LB, Donnenfeld AE, Feingold M, Beemer FA, Hennekam RC, Scambler PJ (2000) Novel HOXA13 mutations and the phenotypic spectrum of hand-foot-genital syndrome. Am J Hum Genet 67(1):197–202. https://doi.org/10.1086/302961
15. Schwarzbraun T, Windpassinger C, Ofner L, Vincent JB, Cheung J, Scherer SW, Wagner K, Kroisel PM, Petek E (2006) Genomic analysis of five chromosome 7p deletion patients with Greig cephalopolysyndactyly syndrome (GCPS). Eur J Med Genet 49(4):338–345. https://doi.org/10.1016/j.ejmg.2005.10.133

Publisher's Note

Springer Nature remains neutral with regard to jurisdictional claims in published maps and institutional affiliations.