LETTER TO THE EDITOR

Management of reperfusion deficiency with indocyanine green fluorescence imaging during deceased donor liver transplantation in a pediatric recipient

To the Editor,

We read the study of Figuero *et al.*[1] about imaging of the graft perfusion during liver transplantation with great interest. They concluded that a relationship between graft function and imaging with ICG (indocyanine green) fluorescence might predict the primary graft dysfunction during liver transplantation. As a contribution to this precious literature, we considered presenting our experience about using ICG fluorescence imaging in liver transplantation practice. Recently, a 4 years old, 20 kg boy undergone deceased donor liver transplantation due to Maple Syrup Urine Disease in our center. The age, weight, and height of the donor were 3 years, 15 kg and 95 cm, respectively. On postoperative day 4 the hepatic artery (type III according to Michels classification) could not be visualized by the doppler which was confirmed by computed tomography angiography. The patient was taken to the theatre, and the thrombosed left hepatic artery was detected. Although the revision of the anastomosis absence of intraparenchymal blood flow and a focal hypoechoic area (necrosis?) in the left lobe was demonstrated by the ultrasound. After ICG infusion (0,05 mg/kg), the perfusion of the graft was monitored, and the ischemic area in the left lobe was demonstrated clearly while other segments perfused well (Fig. 1). The ischemic part of the liver was removed entirely, and the minimum liver volume loss was provided by preserving the fully healthy tissue. The patient is still alive in the postoperative month 3. The ICG fluorescence imaging can be used for managing the vascular complications with insufficient graft perfusion as a secure and feasible tool during liver transplantation.

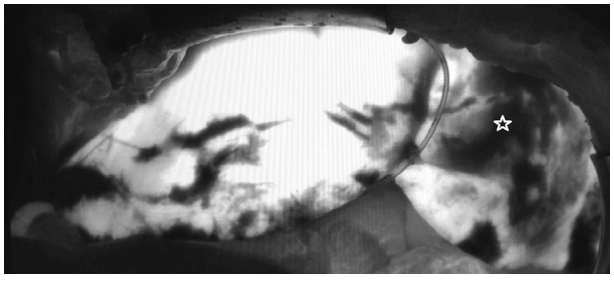

Figure 1 The ischemic area (star) in the left lobe demonstrated with indocyanine green fluorescence imaging during reperfusion of the transplanted graft

Funding sources
This study has no funding.

Conflict of interest
None to declare.

Abdullah Kisaoglu, Ismail Demiryilmaz, Ozgur Dandin
Akdeniz University Faculty of Medicine, Department of General Surgery, Tuncer Karpuzoglu Transplantation Center, Antalya, Turkey

Omer Ozkan
Akdeniz University Faculty of Medicine, Department of Plastic and Reconstructive Surgery, Tuncer Karpuzoglu Transplantation Center, Antalya, Turkey

Bulent Aydinli
Akdeniz University Faculty of Medicine, Department of General Surgery, Tuncer Karpuzoglu Transplantation Center, Antalya, Turkey

Correspondence: Ozgur Dandin, Akdeniz University Faculty of Medicine, Organ Transplantation Center, Antalya, Turkey.
E-mail: dandinozgur@gmail.com (O. Dandin)

Reference

1. Figueroa R, Golse N, Alvarez FA, Ciacio O, Pittau G, Sa Cunha A *et al.* (2019) Indocyanine green fluorescence imaging to evaluate graft perfusion during liver transplantation. *HPB* 21:387–392.

© 2019 International Hepato-Pancreato-Biliary Association Inc. Published by Elsevier Ltd. All rights reserved.