Journal of Cardiology Cases (2011) 4, e121—e125

available at www.sciencedirect.com

ScienceDirect

journal homepage: www.elsevier.com/locate/jccase

Case Report

Acquired QT interval prolongation and ventricular arythmias associated with brucellosis: A case report and review of literature

Atakan Yanikoglu (MD)*, Ibrahim Basarici (MD), Emre Altekin (MD), Serkan Karakas (MD), Sinan Ozbek (MD), Ali R. Gulcan (MD), Cengiz Ermis (PhD, MD)

Akdeniz University, School of Medicine Cardiology Department, Dumlupinar Street, Antalya, Turkey

Received 9 May 2011; received in revised form 5 June 2011; accepted 21 June 2011

KEYWORDS
Brucellosis;
Acquired long QT;
Ventricular tachycardia

Summary Brucellosis is a zoonosis caused by *Brucella* species and usually involves the lymphoreticular system. Cardiovascular involvement is rare but fatal. Endocarditis is the most common cardiovascular manifestation of brucellosis. Herein we report a case of brucellosis with a presentation of acquired QT prolongation and ventricular tachycardia without a clear clinical picture of endocarditis and myocarditis.
© 2011 Japanese College of Cardiology. Published by Elsevier Ltd. All rights reserved.

Introduction

Brucellosis is a zoonosis caused by *Brucella* species which are transmitted to humans via ingestion of raw meat, milk products, or direct contact with infected animals. It is common in the Middle East, Mediterranean region, Asia, Africa, and South America. Presentation can be acute and subacute-chronic (undulant fever). It usually involves the lymphoreticular system. Cardiovascular and neurologic involvements are rare but fatal. Endocarditis is the cardiovascular manifestation of brucellosis. It usually involves the aortic valve [1]. Here we report a case of brucellosis with a presentation of acquired QT prolongation and ventricular tachycardia without apparent vegetation on both transthoracic (TTE) and transesophageal (TEE) echocardiography.

Case report

A 69-year-old, diabetic and hypertensive woman without any known history of cardiac disease was admitted to the emergency department with complaints of malaise and dizziness. It was learned that she had two syncope episodes 5 days previously. Blood pressure was 125/70 mmHg and pulse was 70 beats/min, auscultation of respiratory system was normal, cardiac auscultation revealed extrasystolic beats and low grade systolic murmur at left sternal border, abdominal examination revealed no hepatomegaly but there was mild splenomegaly. A standard 12-lead electrocardiography was in sinus rythm with a rate of 67 beats/min but the QTc interval was calculated as 640 ms and there were couplet

* Corresponding author. Tel.: +90 242 2496775.
E-mail address: dratakany@yahoo.com (A. Yanikoglu).

1878-5409/$ — see front matter © 2011 Japanese College of Cardiology. Published by Elsevier Ltd. All rights reserved.
doi:10.1016/j.jccase.2011.06.007



Figure 1 Electrocardiography of the patient on admission. Corrected QT interval was 640 ms and there were ventricular extrasystoles.

and triplet ventricular extrasystoles (Fig. 1). Chest X-ray was normal. Complete blood count was normal. There was mild hyponatremia and hepatic enzymes were increased in blood biochemistry. Cardiac enzymes were normal (Table 1).

The patient was hospitalized because of abnormal electrocardiographic findings and for the purpose of identifying the etiology of syncope episodes. In follow up, the patient had a nonsustained ventricular tachycardia episode (Fig. 2). Thereafter the patient had a sustained ventricular tachy-

Table 1 Laboratory parameters on admission and follow up.

	Admission	Follow up
Complete blood count		
Hemoglobin (g/dL) (12.0—16.0)	14.3	
Hematocrit (%) (35.0—52.0)	42.4	
White blood cell (10^3/mm^3) (4.8—10.8)	6.2	
Thrombocyte (10^3/mm^3) (150.0—450.0)	105.0	
Blood biochemistry		
Creatinine (mg/dL) (0.5—1.10)	0.95	
ALT (U/L) (0.0—31.0)	107.00	
AST (U/L) (0.0—32.00)	162.00	
Na (mEquiv./L) (133.0—145.0)	131.0	133
K (mEquiv./L) (3.3—5.1)	4.08	3.19 (3.72)[a]
Ca (mg/dL) (8.6—10.2)	8.6	
Magnesium (mEquiv./L) (1.7-2.5)	1.9	1.8
Mass CK-MB (ng/dL) (0.0—2.88)	3.05	
Troponin-T (ng/dL) (0.01—0.10)	0.01	

ALT, alanine aminotransferase; AST, aspartate aminotransferase; CK-MB, creatine kinase-myocardial band.
[a] The potassium level after intravenous replacement.



Figure 2 Non-sustained ventricular tachycardia episode which was recorded on monitor electrocardiography.

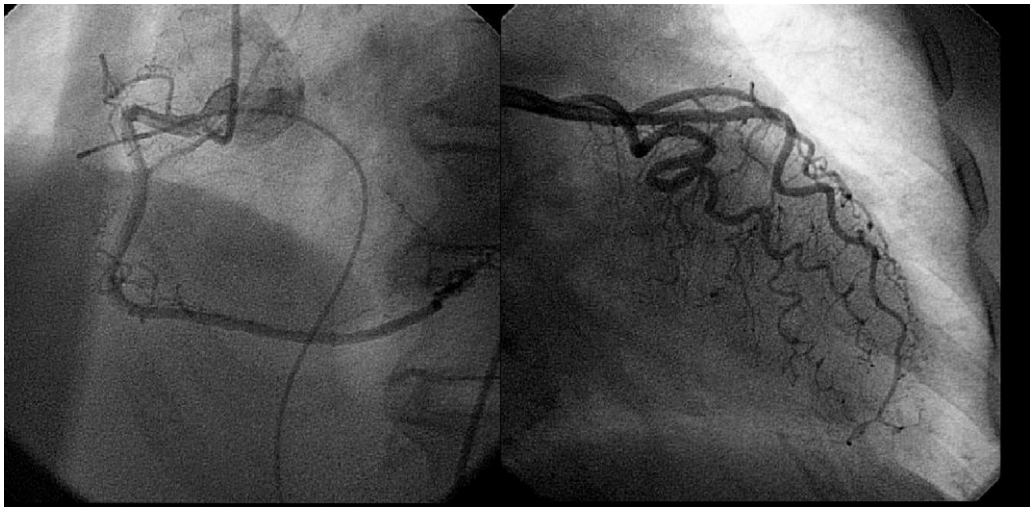

Figure 3 Coronary angiography of patient. Coronary anatomy was normal.

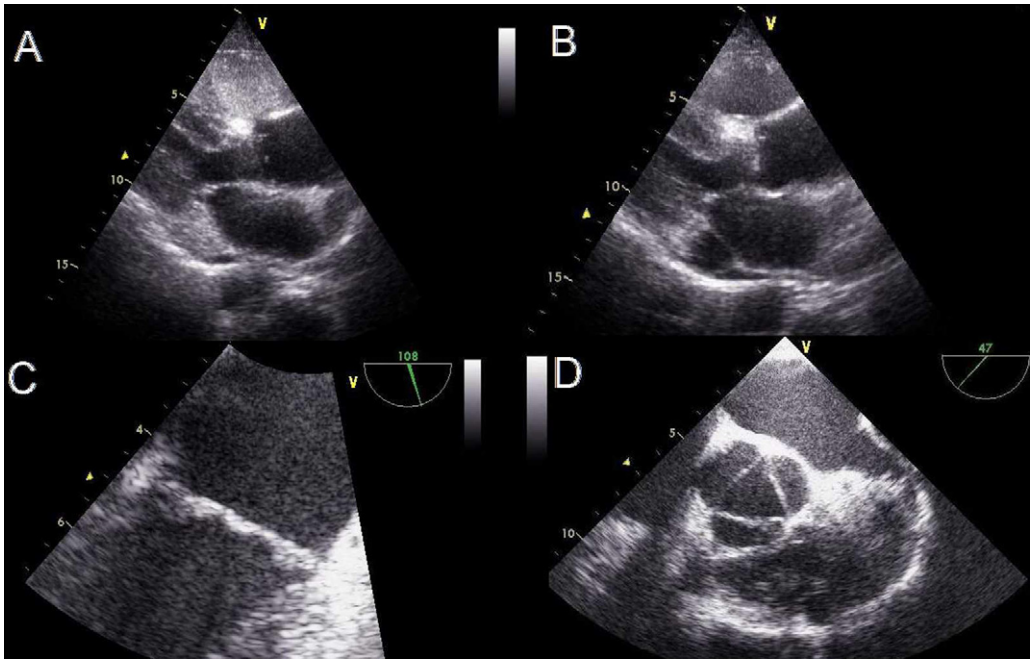

Figure 4 (A and B) Transthoracic echocardiographic images of the patient. Interventricular septum thickness was 1.3 cm and posterior wall thickness was 1.2 cm. (C and D) Transesophageal echocardiographic images of the patient. There were no visible vegetations on mitral (C) and aortic (D) valves.

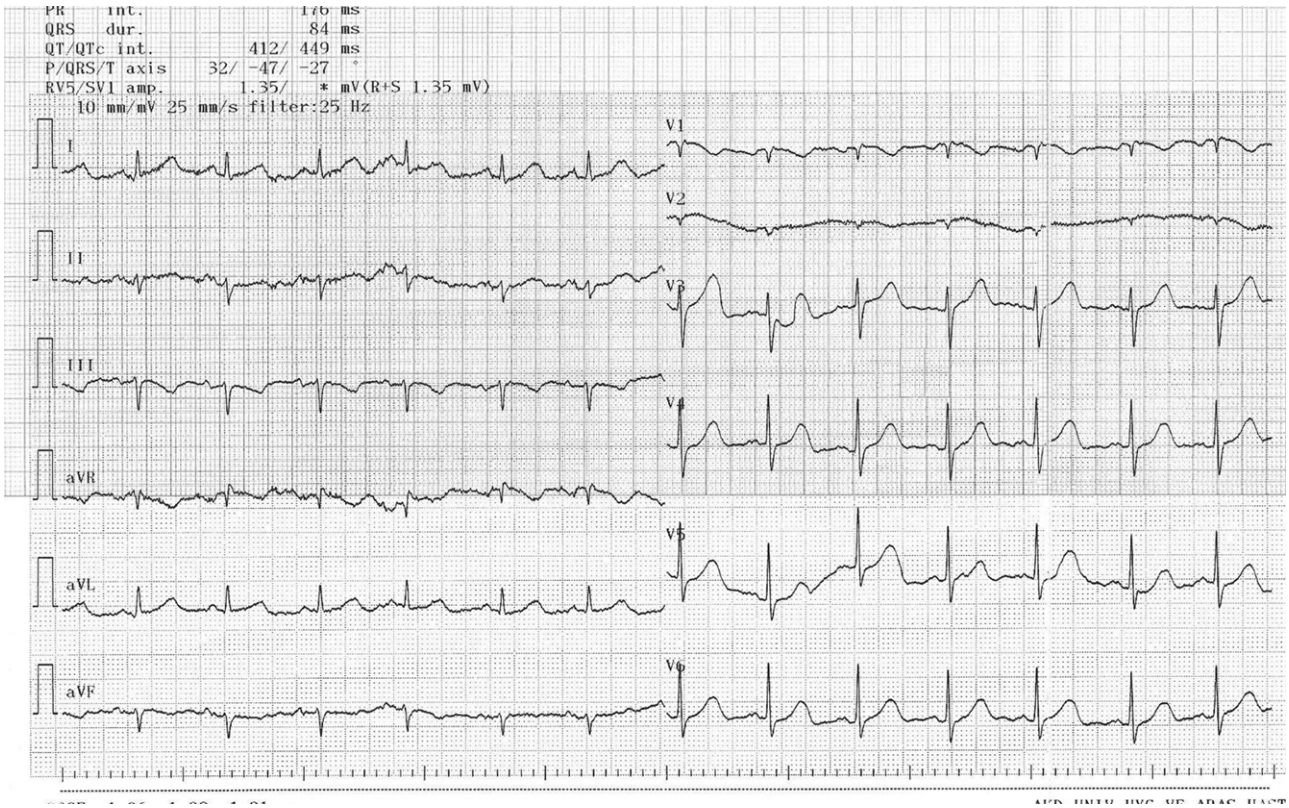

Figure 5 Electrocardiography on follow up. Corrected QT interval was shortened and ventricular extrasystoles were lost.

cardia episode which compromised the hemodynamic status and urgent electrocardioversion was performed. Electrolyte levels were checked in order to detect an electrolyte imbalance. Magnesium level was normal but there was mild hypokalemia (Table 1). Potassium deficit was replaced and amiodarone was given to the patient intravenously. Although we corrected the mild electrolyte imbalance, prolonged QT interval and nonsustained ventricular tachycardia episodes remained (Table 1). In order to control ventricular tachycardia episodes, a transient transvenous pacemaker adjusted with a rate of 110—120 beats/min was implanted to the patient.

TTE of the patient revealed normal ejection fraction and normal leaflet morphology but there were left ventricular hypertrophy (interventricular septum thickness 1.3 cm and posterior wall thickness 1.2 cm). In order to exclude ischemic etiology, coronary angiography performed and coronary arteries were found to be normal (Fig. 3).

Because the patient had increased hepatic enzymes, hepatitis virus was checked for and found to be normal. On the second day of hospitalization, blood and urine culture samples were collected because the patient had fever. After 6 days of hospitalization, *Brucella* species were isolated from all the blood cultures. An antibiotic regimen of doxycycline, rifamiycin, and gentamicin was started. To exclude infective endocarditis TEE was performed; no vegetation was seen on the leaflets (Fig. 4). C3, C4, and rheumatoid factor levels were also normal. Fundoscopic exam of the patient was also normal. As the time went on with the triple antibiotic regimen, on electrocardiography QTc interval became shortened and frequency of ventricular extrasystoles was diminished and the transient transvenous pacemaker was withdrawn from the patient (Fig. 5).

The patient had no ventricular extrasystoles and ventricular tachycardia at follow up. Liver enzymes were decreased and QTc interval shortened. She was discharged with oral antibiotic treatment.

Discussion

In this case we suppose that the reason of QT prolongation and torsades de pointes can be explained by *Brucella* infection for the following reasons: first, QTc interval was prolonged without any apparent reason; electrolyte levels were normal and also there were no drugs given to the patient that could prolong QT interval. Second, with appropriate antibiotic treatment the patient had no ventricular tachycardia episodes and QT interval shortened.

In the literature Devriendt et al. reported a case with legionellosis complicated with torsades de pointes as a result of myocarditis [2]. Our patient had no clinical presentation with heart failure and systolic functions of left ventricle were normal. The patient's cardiac markers were also normal. We did not diagnose myocarditis in this patient.

We know that in normal patients, QT interval shortens with fever [3]. In patients with type-2 long QT syndrome, QT interval can be prolonged and malignant ventricular arythmias can be seen [4]. Our patient had ventricular arrhythmia

episodes when she was afebrile, and with the antibiotic therapy the QT interval shortened.

The congenital long QT syndrome is caused by mutations of the genes for cardiac potassium, sodium, or calcium ion channels. There are at least 10 genes that have been identified. The definite diagnosis mainly relies on the molecular analysis of these defects. Genetic testing for known mutations can be done only in specialized centers. However, only approximately 50% of patients with this syndrome have known mutations. There are also unknown mutations of this syndrome. Therefore, genetic testing has high specificity but a low sensitivity [5,6].

In 1993, Schwartz et al. suggested diagnostic criteria that still serve as the best criteria for clinicians [7]. According to criteria suggested by Schwartz et al., our patient has a total of 6 points on admission (QTc on admission was greater than 480 ms: 3 points; torsades de pointes episode: 2 points; syncope without stress: 1 point) which corresponds to high probability to have long QT syndrome. However, after responding well to antibiotic therapy, the QTc interval shortened (449 ms) and according to these criteria our patient had a score of 3 points (normal QT interval: 0 points; torsades de pointes: 2 points; syncope without stress: 1 point) which corresponds to intermediate risk to have long QT syndrome. Because of this intermediate risk, and difficulties to access for these tests we did not see it necessary to do genetic testing in this patient.

Endocarditis is the most common cardiac presentation of brucellosis. Pericarditis can develop in association with endocarditis and as a primary infection of pericardium [8]. QT interval prolongation and torsades de pointes development has been reported only in one case with infective endocarditis [9]. In the pediatric age group, *Brucella* endocarditis can mimic acute rheumatic fever with carditis. Prolongation of the PR interval on electrocardiography can be seen in those patients [10]. This case has a surprising presentation with QTc prolongation and ventricular tachycardia episodes without apparent vegetation on both TTE and TEE. Also in our patient, with the appropriate antibiotic therapy the QTc interval shortened as in the previous case report in the literature [9].

We suggest that brucellosis may lead to QT interval prolongation and malignant ventricular arrhythmias without a clear clinical presentation of endocarditis and myocarditis, through unknown mechanisms. Involvement of the conduction system merely may have a role in that situation.

References

[1] Corbel MJ. Brucellosis: an overview. Emerg Infect Dis 1997;3:213—21.
[2] Devriendt J. Legionellosis and ''torsades de pointes''. Acta Cardiol 1990;45:329—33.
[3] Karjalainen J, Viitasalo M. Fever and cardiac rhythm. Arch Intern Med 1986;146:1169—71.
[4] Amin AS, Herfst LJ, Delisle BP, Klemens CA, Rook MB, Bezzina CR, Underkofler HA, Holzem KM, Ruijter JM, Tan HL, January CT, Wilde AA. Fever-induced QTc prolongation and ventricular arrhythmias in individuals with type 2 congenital long QT syndrome. J Clin Invest 2008;118:2552—61.
[5] Morita H, Wu J, Zipes DP. The QT syndromes: long and short. Lancet 2008;372:750—63.
[6] Hedley PL, Jørgensen P, Schlamowitz S, Wangari R, Moolman-Smook J, Brink PA, Kanters JK, Corfield VA, Christiansen M. The genetic basis of long QT and short QT syndromes: a mutation update. Hum Mutat 2009;30:1486—511.
[7] Schwartz PJ, Moss AJ, Vincent GM, Crampton RS. Diagnostic criteria for the long QT syndrome. An update. Circulation 1993;88:782—4.
[8] Young EJ, Corbel MJ, Brucellosis:. Clinical and laboratory aspects. Boca Raton: CRC Press; 1989.
[9] Sayar N, Terzi S, Yilmaz HY, Atmaca H, Kocak F, Dayi SU, Cakmak N, Tarhan A, Ozler A, Yesilcimen K. A case of prosthetic mitral valve *Brucella* endocarditis complicated with torsades de pointes. Heart Vessels 2006;21:331—3.
[10] Lubani M, Sharda D, Helin I. Cardiac manifestations in brucellosis. Arch Dis Child 1986;61:569—72.