P1726

A case of double chamber right ventricle with membranous ventricular septal defect: multimodality approach before and after surgical repair

Mehtap Yeni MY.[1]; Ibrahim Basarici İ B[2]; Nermin Bayar NB.[3]; Sakir Arslan SA.[3]

[1]Isparta State Hospital, Isparta, Turkey
[2]Akdeniz University Hospital, cardiology, Antalya, Turkey
[3]Antalya Education and Research Hospital, Cardiology, Antalya, Turkey

21 year old male admitted with progressive dyspnea. Transthoracic echocardiogram(TTE) showed membranous type ventricular septal defect(VSD).Additionally there was an evident turbulence and nearly 120mm Hg (5.5m/s maximal velocity) gradient in the mid region of right ventricle(RV) a muscle bundle was restricting the flow. Double chamber right ventricle(DCRV) and VSD have been confirmed also with right heart catheterisation.Measured RV pressures were 90/0/5 mmHg and pulmonary artery pressures were 17/4(mean:8mmHg).Qp/Qs was 1.3. Cardiac magnetic resonance imaging (CMRİ) excluded other congenital defects like atrial septal defect,abnormal pulmonary venous return or aortic coarctation. Cardiac BT also clearly showed the hypertrophied muscular bundle which is close to the apex; was dividing the right ventricle cavity into two parts. Patient has been referred for surgery.On follow up, patient was doing well and TTE nicely showed a clear decrease of gradient as measured maximal velocity was 2m/s and no residual shunt of VSD. Control CMRİ also showed good RV function with a mild residual muscle structure.

Our case was a nice example of VSD without pulmonary hypertension because of restricted blood flow of pulmonary artery by a muscle bundle. If VSD is presented with a restricted RV outflow ; instead of a dilated RV chamber as been expected; a concomitant DCRV should be kept in mind.

Abstract P1726 Figure. video 1

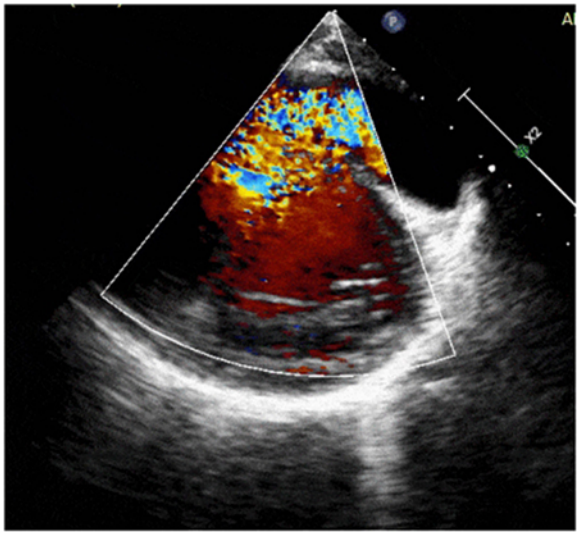

Downloaded from https://academic.oup.com/ehjcimaging/article/21/Supplement_1/jez319.1088/5708462 by Akdeniz Universitesi user on 20 September 2021