

PARIS

CHALLENGES, OPPORTUNITIES AND NEW PERSPECTIVES IN ENDODONTOLOGY

3-6 SEPTEMBER 2025 ese

General Endodontic Posters

GENERAL ENDODONTIC POSTERS 01

GE001 | EVALUATION OF SEALING ABILITY AND ADAPTABILITY OF DIFFERENT ENDODONTIC SEALERS: IN VITRO COMPARATIVE STUDY

A ALHILOU [1]

[1] *Department of Restorative Dentistry, College of Dentistry, Umm Al-Qura University, Makkah, SAUDI ARABIA*

AIM: Recently, new sealers have been introduced to the endodontic market. However, it remains unclear which one of these sealers is superior in terms of their sealing ability and adaptability. Therefore, this study aimed to evaluate and compare the sealing ability and adaptability of three root canal sealers.

Methodology: Forty-five single-rooted human teeth were decontaminated, de-coronated, and randomly divided into three groups of 15 samples each. Canals were prepared, irrigated, and obturated using the single cone technique. The external surfaces of the teeth were coated with two layers of varnish except for the last 1mm of the apex to allow dye penetration. As part of the adaptability evaluation, five samples in each group were longitudinally sectioned. The interfacial sealer/ radicular dentin contact percentage was determined. For the microleakage assessment, the dye penetration in the cleared teeth was measured using a stereomicroscope. One-Way ANOVA with Tukey's post-hoc test was used for intergroup comparison of normally distributed data, while for non-normally distributed data, Kruskal-Wallis One Way Analysis of Variance on Ranks with Dunn's Method was used.

Results: Nano Seal-S had the highest significant contact percentage of 92.3%, followed by AH Plus and Bio-C Sealer with 75.8% and 59.9%, respectively with a statistically significant difference ($P<0.001$) between the sealers. Bio-C had a median leakage of zero micrometer (µm), which was significantly different from Nano Seal (median=166µm) ($P<0.02$). AH Plus recorded an intermediate leakage value (median = 65 µm) with an insignificant median compared to other sealers.

Conclusions (mandatory): The results of the study indicated that Nano Seal exhibits superior adaptability to radicular dentin as compared to other sealers, while Bio-C stands out as the most effective for leakage prevention among the tested sealers.

GE003 | ENDODONTIC TREATMENT OF PERIAPICAL LESIONS WITH EXTRUSION OF TWO CONTEMPORARY BIOCERAMIC SEALERS - A CLINICAL OUTCOME STUDY

E. GYULBENKIYAN [1], P. IGNATOV [2], A. GUSIYSKA [1]

[1] *Faculty of Dental Medicine, Medical University, Sofia, BULGARIA*
[2] *Faculty of Medicine, Medical University, Sofia, BULGARIA*

AIM: To evaluate outcomes of endodontically treated teeth obturated with the sealers TotalFill BC (TFBC) and AH Plus Bioceramic (AHPBC) with and without periapical extrusion.

Methodology: There were 180 root canal treatments on 74 patients between the ages of 23 and 78.
All root canals were rotary instrumentated with the Ni-Ti system WaveOne Gold. The bioceramic sealers TFBC and AHPBC were used for the hermetic root canal obturating. During the obturation of 67 teeth, bioceramic sealer was intentionally extruded in the periapical zone - 29 teeth obturated with AHPBC and 38 with TFBC.
The Periapical Index score system by Orstavik was used to assess the dimensions of all periapical lesions (180). CBCT examination additionally followed part of the teeth (n = 60).
At a predetermined 95% confidence interval and 80% power, the independent samples (or two-sample) t-test was used to compare the two groups statistically. It was further corrected for unequal variances in some of the groups.

Results: The successful treatment of all teeth (N = 180) was 94.45% - a total of 170 teeth. Thirty-three (76.74%) teeth with a restored periapical zone initially had periapical lesions larger than 5 mm. In 137 teeth, there was a success rate of healing with initial lesions smaller than 5 mm. Sixty-three teeth (94.03%) with successful endodontic treatment had intentionally extruded bioceramics in the periapical zone, and 48 teeth (71.64%) of them were healed already at the 6th month. A statistically significant difference was found between the two groups of teeth (with and without bioceramic extrusion) - $p = 0.0445$.

Conclusions (mandatory): The bioceramic sealers are a reliable material for root canal obturation, which leads to predictable and excellent outcomes of root canal treatment. Extrusion of bioceramics in the periapical zone leads to faster healing by promoting anti-inflammatory and regenerative processes in the periapical lesion.



GE004 | Endodontic management of a trauma case and 20 months follow up

Irina Szene Msc,
Private Practice, Germany

AIM - To present a complicated trauma case where the endodontic treatment was started too late and survival chances were very low.

INTRODUCTION - Traumatic dental injuries affect approximately one billion people worldwide (Petti et al 2018) and these injuries can cause pulp necrosis (Hecova et al 2010). The consequence of pulp necrosis in these teeth is arresting of further root formation (Tsilingaridis et al 2012).

CASE PRESENTATION - Patient, 9 years old, is referred to a specialist because of complicated abcess regio 11-21. The referring dentist performed 5 appointments in the last 6 months to change the calcium hydroxide dressing. The swelling did not subside nor did the pus discharge coming from the tooth. Anamnestic data: pool accident 3 years before with avulsion of tooth 11. Tooth was replanted in 1 hour and splinted for 8 weeks. After removing the splintage, tooth was no longer kept under observation. 6 months ago patient presents to the general dentist with swelling regio 11-12 and upper lip and pain. An endodontic treatment was initiated. After 6 appointments at the general dentist office pat was referred to a specialist. First XRay at our practice is listed as Fig.1. After anesthesia, rubberdam placement and copious irrigation with 3% sodium hypochlorite, calcium hydroxide application in canal (procedure repeated 3 times in our practice), in the 4th appointment we were able to place a MTA plug(Fig.2). Before placing the MTA plug, granulation tissue was observed apical. One week after placing the apical plug I performed the composite restauration. Recall after 6 months is presented in Fig.3. In both Fig.3 and Fig.4 are observed as follows, from apical to coronal: MTA, Guttapercha, Opaque Flow and packable Composite. Recall after 20 months is presented in Fig.4. In the end we obtained a good “guided endodontic repair”. In Fig.5 is presented the tooth immediatly after completing the root canal treatment and in Fig.6 is presented the tooth at 20 months recall (coronal restauration was performed in the same appointment as completing the root canal treatment) .



Fig.1



Fig.2



Fig.3



Fig.4



Fig.5



Fig.6

DISCUSSION - The presented case wants to highlight the importance of an early diagnostic and the need to spread the word regarding trauma guidelines. In this case we can see a good healing and the goal it was from the beginning to keep the tooth along with good periapical tissues as long as possible on the arch. We can see this as an opportunity to change the impossible to possible and keep in place even teeth that seem impossbile at the beginning to heal.

CLINICAL RELEVANCE - With precise protocols and guidelines we can attempt to treat even this kind of cases. It is our duty to give the best and to be permanently informed regarding best practices to help our patients but also to be flexible and try new things, even if sometimes we cannot forsee the end result.

REFERENCES -

Cehreli ZC, Sara S, Uysal S, Turgut MD. MTA apical plugs in the treatment of traumatized immature teeth with large periapical lesions. Dent Traumatol. 2011 Feb;27(1):59-62. doi: 10.1111/j.1600-9657.2010.00941.x. Epub 2010 Dec 5. PMID: 21129158.
Wikström A, Brundin M, Lopes MF, El Sayed M, Tsilingaridis G. What is the best long-term treatment modality for immature permanent teeth with pulp necrosis and apical periodontitis? Eur Arch Paediatr Dent. 2021 Jun;22(3):311-340. doi: 10.1007/s40368-020-00575-1. Epub 2021 Jan 8. PMID: 33420674; PMCID: PMC8213569.
Diogenes, Anibal, et al. "Regenerative endodontics: a way forward." The Journal of the American Dental Association 147.5 (2016): 372-380.

GE005 | DIAGNOSTIC CHALLENGES IN THE FIELD OF ENDODONTICS – A PRACTITIONER'S VIEW

I. SZENE [1]

[1] *Private Practice, Wuppertal, GERMANY*

AIM: The aim of the presentation is to put into attention two very interesting cases where diagnostic was difficult to establish and where this diagnostic played an important role in the patient's future.

Methodology: Both patients were referred to an endodontist for a second opinion and/or endodontic treatment. The first patient is a female, 47 years old, diagnosed with bone cancer 12 years earlier and since then is resuming treatment with Denosumab, presents with diffuse pain in upper jaw, front teeth and second quadrant and in lower jaw in the third quadrant. After the clinical tests are performed, the decision is made to do a panoramic Xray. Seeing the findings on the panoramic Xray we strongly recommend a CBCT. The CBCT shows multiple idiopathic resorptions. The patient is referred to my surgeon colleague and the decision is made to perform multiple extractions due to the advanced status of the resorptions.
The second patient is a 36 years old male, no general diseases, no medication. The general dentist initiated a root canal treatment on tooth 26 but the palatal swelling did not go away. Patient was given also antibiotics, 3 times, every time 7 days, one month apart. Because of the strange character of the swelling, I recommended a CBCT. After seeing the extensive mass of tissue palatal in the second quadrant, I advised for a biopsy. The results came back with the following diagnostic: cells typical for Non-Hodgkin Lymphoma and Leukaemia. We then performed the root canal filling, and the patient was referred to the clinic for further investigations and treatment.

Results: • Diagnostic is the core of endodontics
• We must correlate all the information that we have
• Interdisciplinarity is a must
• When something feels not right investigate
• It is always beneficial to stay curious

GE006 |

CASE SERIES: Hemisection of an upper molar to maintain a closed dental arch

AIM: With the preservation of the crown structure of an upper molar, a closed dental arch can received. This is important to stabilize the neighbor teeth in a previously damaged periodontal denture (1), to prevent progressing periodontal inflammation and tipping. The aim is to reduce pocket depth and to fix the teeth in a naturally way with the neighbor teeth with the contact point.

INTRODUCTION: Three Cases with two different diagnosis (root fracture and caries lesion in the pulp chamber) treated in the same way with the same aim. Tooth preservation, no implant.
In Case one and two, deep periodontal defects are visible (x-ray below), and the patients are 69 and 80 years old, so they no longer wished for larger implantological procedures with bone reconstruction. Instead, they focused on preserving their teeth as well as possible. However, the patient in case three is 50 years old, has no periodontal history, but the endodontically treated tooth did not receive a crown to protect the cusps. This shows a fracture between the mesiobuccal and palatal roots.
In all three cases, a hemisection was performed. If not already in place, the teeth were then restored with a full ceramic crown (E-max, adhesively fixed).

CASE PRESENTATION:

1

04.08.2022
Fracture of the mesio-buccal root (while periodontal treatment)

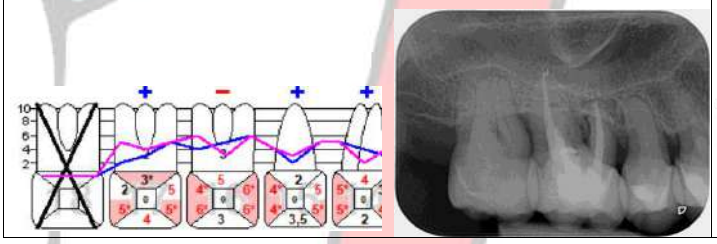

24.01.2023
Control X-ray after hemisection (Periodontal Screening before hemisection)

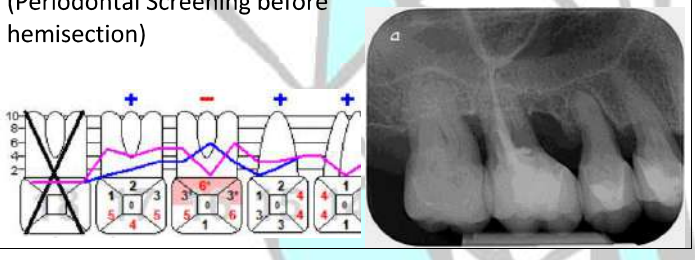

2

27.10.2023



01.12.2023 Preendo built up



20.03.2024



25.09.2024



3

08.01.2024



26.02.2024 Postendo built up



04.03.2024 Hemisection



28.10.2024



DISCUSSION: As published in the 2008 position paper of the AAE (2), teeth with fractures especially those affecting the depth of the root, have an unpredictable prognosis, which should be communicated to the patient. Several studies have addressed the ideal approach to fractures, but they come to contradictory conclusions (3). Additionally, there is often a high risk of Bias (4). For example, the study by Hilton et al. (2017) describes fractures as occurring more frequently in lower molars than in upper molars (5). This contradicts the cases presented here.
In the systematic review by Mokbel et al. (2019), 22 studies (some of them very heterogeneous) were included (4). From these studies recommendations for the approach are summarized. One critical point is the placement of a post, as this leads to further loss of tooth structure and weakens the Tooth's root anatomy. Much more important is the principle of "ferrule first, post second" (6) and an adequate oral hygiene (4). Nevertheless, it remains the only way to maintain a closed dental arch without implants.

CLINICAL RELEVANCE: Even seemingly hopeless cases of root fractures in periodontically compromised dentition can be preserved with adequate oral hygiene and regular recall visits, as the cases above demonstrate after 3 (28.10.2024-01.2025), 4 (25.09.2024-01.2025), 24 (24.01.23 – 01.2025) month.

(1) Aquilini et Caplan. "Relationship between number of proximal contacts and survival of root canal treated teeth" Int Endod Journal (2002)
(2) Rivera and Walton. "Endodontics: Colleagues for Excellence." American Association of Endodontists (2008)
(3) Patel et. al. "Position statement on longitudinal cracks and fractures of teeth." Int Endod Journal (2024)
(4) Mokbel et al. "Root Resection and Hemisection Revisited. Part I: A Systematic Review." Int J Periodotnics Restorative Dent (2019)
(5) Hilton et al. "Correlation between symptoms and external characteristics of cracked teeth: findings from the national Dental Practice-Based Research Network." The Journal of the American Dental Association (2017)
(6) Naumann et al. "Ferrule Comes First. Post Is second! Fake News and Alternative Facts? A Systematic Review." Journal of Endodontics (2018)

GE007 | THE DISSOLUTION OF MTA IN CLINICALLY COMPROMISED ENVIRONMENTS: CAUSES, EFFECTS, AND MANAGEMENT STRATEGIES

S. DRUKTEINIS [1]

[1] *Institute of Dentistry Faculty of Medicine Vilnius University, Vilnius, LITHUANIA*

AIM: This presentation analyses the factors contributing to mineral trioxide aggregate (MTA) dissolution in compromised clinical environments, particularly following secondary dental trauma (SDT). It highlights the impact of acidic conditions, root resorption, and re-injury on MTA stability while discussing effective management strategies to improve endodontic outcomes.

Methodology: Mineral trioxide aggregate (MTA) is a widely used endodontic material valued for its biocompatibility and sealing properties. However, its long-term stability can be compromised by secondary dental trauma (SDT) and an acidic microenvironment that results from inflammatory conditions. A lower pH can weaken the structure of MTA and accelerate its degradation. SDT further undermines MTA by exposing it to fluctuating pH levels and bacterial infiltration. Pre-existing conditions, such as orthodontically induced inflammatory root resorption (OIIRR), also compromise root structures, increasing susceptibility to trauma and disintegration of MTA. The breakdown of MTA can lead to a loss of root canal integrity, bacterial reinfection, and progressive root resorption, negatively affecting the prognosis of the tooth and potentially requiring retreatment. To manage these issues effectively, early diagnosis and regular clinical and radiographic assessments are essential. Alternative bioceramics, such as Biodentine, offer better acid resistance and faster setting times, making them more reliable in the long term. Comprehending the factors influencing MTA dissolution assists clinicians in enhancing treatment outcomes and ensuring the durability of endodontically treated teeth.

Results: • Acidic conditions, bacterial infiltration, and mechanical disturbances from SDT can influence MTA dissolution.
• Orthodontically induced inflammatory root resorption (OIIRR) can increase the risk of MTA degradation.
• Biodentine provides a more stable long-term alternative due to its superior acid resistance and faster setting.
• Early diagnosis, regular monitoring, and reinforced treatment approaches are critical for improving endodontic outcomes.
• Clinicians should consider new bioceramic materials to improve sealing techniques and optimize long-term tooth survival.

GE008 | ENDODONTIC MICROSURGERY ON A MANDIBULAR FIRST MOLAR WITH RADIX ENTOMOLARIS USING AUGMENTED REALITY TECHNOLOGY AND A 3D-PRINTED MODELS

K. MAKI [1], T. OKIJI [1]

[1] *Institute of Science Tokyo, Tokyo, JAPAN*

AIM: This case report aimed to present the advantage of using augmented reality (AR) technology and 3D-printed models in endodontic microsurgery on a mandibular first molar with radix entomolaris.

Methodology: A 35-year old female patient was referred for retreatment of tooth #30 due to swelling at its apical portion. Pre-operative periapical radiographs and CBCT scans revealed a periapical radiolucency involving the apex of three roots (mesial, distobuccal and distolingual), though root canal fillings appeared of good quality. Before endodontic microsurgery, AR images and 3D-printed models were created from CBCT data. The AR images helped enhance the three-dimensional recognition of root and root canal morphology and the extent of the periapical lesion. The 3D-printed models were used for surgical simulations, where the model was fixed to a phantom to check the feasibility of resecting the distolingual root (radix entomolaris) under the surgical condition using operative microscope. During the microsurgery, after performing full-thickness flap reflection, osteotomy and root-end resection of the mesial and distobuccal roots, the apex of the distolingual root was resected successfully by replicating the technique practiced on the 3D-printed models. Retrograde preparation was performed with ultrasonic tips, followed by retrograde filling with MTA cement (ProRoot MTA, Dentsply Sirona, Switzerland) for all three roots. Periapical radiographs were taken immediately after the surgery to confirm the procedure was completed without any complications. One year post-surgery, the patient was free from symptoms, and CBCT demonstrated a reduction of the periapical radiolucency.

Results: • Endodontic microsurgery on the radix entomolaris was successfully performed with the aid of AR and 3D printing.
• Preoperative simulation using 3D-printed models significantly enhanced the precision and quality of the endodontic microsurgery.

GE009 | POST REMOVAL WITHIN THE PROSTHETIC RESTORATION: CLINICAL FEASIBILITY OR LACK OF EVIDENCE?

T. KONTOGIANNIS [1]

[1] *Dental School, National & Kapodistrian University of Athens, Athens, GREECE*

AIM: To present and discuss whether post removal during retreatment can be predictably carried out with the prosthetic restoration in place.

Methodology: Preservation of the pre-existing prosthetic restoration (or not) during endodontic retreatment has been a matter of discussion, particularly in clinical practice. It is well known that only removal gives full and undoubted information about the underlying caries and the amount of healthy tissue remaining, let alone in retreatment cases. However, this may not be always feasible. Such conditions include both extensive restorations like full-arch bridges, or patient-related factors such as financial difficulty for a new restoration. Traditionally, post removal is the utmost indication for the clinician to completely remove the restoration. However, many such cases can also be handled with the restoration in place. Such an approach is affected by the type of the post, the type and quality of the prosthetic restoration, the clinician's skills and the patient's willingness (or not) to financially support a new prosthetic rehabilitation.

Results: • Ideally, all restorations should be removed in cases of retreatment with post. However, post removal with the restoration in place is feasible in many cases.
• Screw & glass-fiber posts are easier to be removed with the restoration in place than cast posts; the latter far more difficult to be removed in that way.

GE010 | THE MANAGEMENT OF LATERAL LUXATED IMMATURE PERMANENT UPPER CENTRAL INCISOR

R. MUSTAFA [1]

[1] *Concervative Dpartment,Faculty of Dentistry, Jordan University of Science and Technology, Irbid, JORDAN*

AIM: This case report describes the management of lateral luxated immature permanent upper central incisor and concussion for the right central incisor and left lateral incisor.

Methodology: Case presentation: A healthy 8-year-old boy reported to the emergency clinic complaining of pain in his upper anterior teeth and swelling of his upper lip after a fall trauma that occurred 16 hours earlier. There is no history of loss of consciousness or vomiting. After a complete clinical examination and radiographic evaluation, the left central incisor was manually repositioned and stabilized for four weeks using composite resin and a steel wire diameter of 0.4 mm flexible splint. In addition, conservative management for the right central incisor and left lateral incisor was considered. The antibiotic was prescribed. Follow-up examinations revealed that the tissues had healed well, progression of root development, and the response to sensibility tests (cold test and electric pulp testing) was regained for the affected immature teeth after 2-3 months.

Discussion: Dental trauma is a highly prevalent condition that is commonly seen in male children, especially when they are hyperactive in sports and games. Lateral luxation injury can result in the displacement of a tooth in a direction other than the axial direction. The most affected teeth are maxillary central incisors, followed by lower anterior teeth. There are many prognostic factors in the healing process, such as stage of root development, severity of periodontal tissue damage, speed of intervention, flexible splint, and root canal system infection. In this case, even with delayed intervention, immature root development favors revascularization and healing.

Results: Conclusion and clinical Relevance:
This case study highlights the significance of early diagnosis, proper management, and routine follow-up of traumatized teeth to control the possible complications. Conservative treatment should be considered in some circumstances.

GE011 | ATTITUDES OF DENTAL PRACTITIONERS FROM NORTHERN MOROCCO ON THE PRESCRIPTION OF ANTIBIOTICS DURING ENDODONTIC TREATMENT: A SURVEY

L. KHALAF [1], N. AKERZOUL [2], O. KHALOUFI [3], B. TOURE [4]

[1] *Faculty of Dental medicine.College of health sciences-UIR, Rabat, MOROCCO*
[2] *Faculty of Dental medicine.College of health sciences-UIR*
[3] *Faculty of Dental medicine.College of health sciences-UIR*
[4] *Faculty of Dental medicine.College of health sciences-UIR*

AIM: this study was to evaluate the prescribing attitudes of dental practitioners in Northern Morocco when treating pulpal and periapical pathologies.

Methodology: This cross-sectional study involved 220 dental practitioners registered on the board of the National Council Order of Dentists of Morocco. A self-administered questionnaire, regarding the types of antibiotics used for endodontic treatment in healthy adult patients with endodontic pathological situations, was used and filled out via on – line by practitioners chosen randomly. The data were analyzed with Jamovi (version 1.8.1). Quantitative variables were expressed as mean and standard deviation and qualitative variables as number and percentage. The Chi-square and the ANOVA tests were performed. The significance level was $P < 0.05$.

Results: Forty percent of dental practitioners prescribed amoxicillin as a first-line therapy for a patient without penicillin allergy, and for patients with a penicillin allergy; azithromycin was the drug of choice prescribed by 41.1% of practitioners. The duration of the prescription was 6.5 days ± 0.7. No statistically difference was noted regarding the duration of the prescription, concerning age, sex, specialization, and country of graduation ($P > 0.05$). The acute apical abscess represents the pathology for which most antibiotics are prescribed. Practitioners aged between 24 and 35 years prescribe more than the oldest practitioners ($P = 0.04$). Antibiotics were also prescribed for the management of pulpitis and chronic apical periodontitis. Conclusion: This study shows that a negligible number of practitioners use antibiotics appropriately in treating pulpal and periapical pathologies. A real lack of knowledge has been identified about indications, dosages, and duration

Results: • This study indicates that a limited number of dental practitioners appropriately use antibiotics in Endodontics.
• A lack of knowledge has been observed among dental practitioners about indications, dosages, and durations.
• Practitioners must follow the standard recommendations concerning the prescription of antibiotics in endodontics.

GE012 | ANTIMICROBIAL EFFICACY OF NATURAL EXTRACTS AGAINST ENTEROCOCCUS FAECALIS: AN IN-VITRO STUDY.

L. HASBINI [1], R. ABIAD [1], I. EL GHAZZAWY [2]

[1] *Beirut Arab University- Department of Restorative Sciences, Division of Endodontology, Beirut, LEBANON*
[2] *Alexandria University, Alexandria, EGYPT*

AIM: To evaluate the antimicrobial efficacy of Nigella sativa, ginger, and resin gum in comparison to Sodium hypochlorite (NaOCl) with Ethylenediaminetetraacetic acid (EDTA) root canal irrigating solutions against Enterococcus Faecalis (E.Faecalis).

Methodology: Thirty-eight extracted human mandibular premolars with single canals and fully developed roots were selected, decapitated for standardization at 16 mm, instrumented with K-file #15 to working length, and autoclaved. Teeth were placed in sterile vials with Tryptic Soy Broth, inoculated with E. faecalis, and incubated in brain heart infusion broth for 4 weeks (renewed weekly). Cultures were collected, canals re-instrumented to size 25/.06 and irrigated with 5% NaOCl. Teeth were then divided into 4 groups (n= 7) according to the final irrigation solution: NaOCl with EDTA (A), nigella sativa(B), resin gum(C), and Ginger(D), in addition to positive(E) and negative(F) control groups (n=5). Teeth were irrigated with 3ml of the final solution for 1 minute/group, and then cultures were collected for bacterial analysis. Statistical analysis was done by SPSS at P=0.05 (95% confidence interval). One-way ANOVA evaluated and compared treatment groups followed by Duncan's Multiple Range Tests (DMRTs) at 0.05. Spearman's and Pearson's correlation test analyzed interactions at 0.05.

Results: E.Faecalis at T1 showed significant reductions in Groups A (0.23 ± 0.37), B (0.29 ± 0.50), C (2.03 ± 4.46), and D (0.06 ± 0.10) compared to controls ($p < 0.001$). Reductions from T0 to T1 exceeded 99% in Groups A-D, with Resin Gum showing the strongest negative correlation with time ($r = -0.866$, Pearson). Group E showed significant bacterial increase. Heatmap and correlation analysis confirmed significant time-dependent reductions in E. faecalis. DMRTs confirmed significant differences between the groups ($p < 0.05$).

Conclusions (mandatory): Nigella sativa, ginger, and resin gum reduced E.faecalis counts, demonstrating antimicrobial efficacy comparable to NaOCl + EDTA as the final irrigating solution.

GE013 | AUGMENTED & VIRTUAL REALITY IN ENDODONTIC TREATMENT PLANING

M. REYMUS [1]

[1] *Department of Conservative Dentistry and Periodontology, University Hospital of LMU Munich, Munich, GERMANY*

AIM: The aim of the presentation is to provide attendees with a comprehensive overview of the potential benefits and limitations of diagnosing CBCT-based images using Augmented or Virtual Reality (AR/VR) for endodontic diagnosis and treatment planning.

Methodology: Recent advancements in AR/VR technology have expanded diagnostic options for endodontic practitioners, particularly when examining CBCT-based images. By importing high-resolution scans into immersive, three-dimensional environments, clinicians can gain deeper insights into complex root canal anatomies, detect pathologies with greater clarity, and refine surgical planning. This presentation will demonstrate the step-by-step workflow for transferring CBCT datasets into AR/VR platforms and offer practical tips for incorporating this technique into daily practice. Key advantages—such as enhanced spatial orientation, interactive image manipulation, and potentially improved diagnostic accuracy—will be highlighted. However, it is equally important to recognize potential drawbacks, including algorithmic inaccuracies, standardization hurdles, ergonomic challenges, and the cost of specialized hardware. The discussion will also include preliminary data from a survey of dentists who have implemented AR/VR in their workflows, providing real-world perspectives on the technology's impact. By the end of this session, attendees will be equipped to evaluate the feasibility and value of AR/VR solutions for optimizing endodontic diagnosis and patient care.

Results: • Understand the workflow for integrating CBCT data into AR/VR environments
• Identify strategies for seamlessly incorporating AR/VR into routine clinical practice
• Recognize the advantages, limitations, and ergonomic considerations of AR/VR technology

GE014 | Intracoronary bleaching of a endodontically treated tooth: a case report

Elina Väyrynen DDS , Marja-Liisa Laitala DDS, PhD, Professor, Päivi Havela DDS

Research Unit of Population Health, Faculty of Medicine,

University of Oulu, Finland

Introduction: Many techniques have been evolved for the purpose of managing discoloured non-vital teeth [1]. In order to achieve better control on the patients, in-office and intra-coronal bleaching procedures were introduced in clinical practice. Such techniques usually use high whitening agent concentrations activated by means of light sources, resulting in improved color stability in the long term.

Aim: The aim of this case report was to evaluate the success of intacoronary bleaching of a endodontically treated tooth with 35% hydrogen peroxide with light-based activation using the in-office bleaching technique.

Case Presentation: A 48-year-old healthy female patient visited a dental clinic with the complaint of non-aesthetic and discolored appearance in her right upper lateral incisor in August 2023. A Successful root canal treatment was done in 2020. A radiograph of the tooth was taken and the reason for discoloration was seen: obturation materials (gutta-percha and sealer AH Plus) also in coronal part of the tooth. In-office bleaching was planned. One week later, access cavity was done and glass- ionomer filling placed between the bleaching gel and the root canal filling. Rubber-dam was attached and 35% hydrogen peroxide with light-based activation was applied onto and in the tooth. After an application time of four minutes, the bleaching gel was rinsed off and the procedure was repeated two times. Adequate whitening result was achieved, and temporary filling was placed. After two weeks permanent coronary restoration was performed with composite resin. The whitening result was evaluated clinically and radiologically 18 months later with no signs of color regression or root resorption.

Discussion: The patient's satisfaction with her teeth and appearance has also positive effects on her self-perception and supports psychological well-being [2] . To minimize the risk of discoloration after endodontic treatment, all obturation materials should be strictly localized in the area of the root canal[3].

Clinical Relevance: Materials used in endodontics causes tooth discolorations. Intracoronary bleaching is a minimally invasive technique, an alternative treatment that addresses aesthetic concerns. Endodontic therapy should not focus solely on biological and functional aspects but take aesthetic considerations into account as well. To reduce the risk of material-induced tooth discoloration all materials should be applied carefully in areas of aesthetic concern.

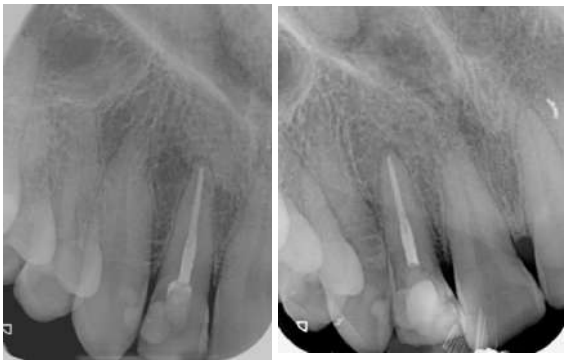

Fig.1: Pre and post (18 months) radiograph of the case



Fig. 2: Pre and postoperative photograph of the case



Fig. 3: 18 months follow up photograph of the case

References:

1. Coelho AS, Garrido L, Mota M, Marto CM, Amaro I, Carrilho E, et al. (2020) Non-Vital Tooth Bleaching Techniques: A Systematic Review. Coatings, 10(1):61.
2. Bersezio C, Martín J, Mayer C, Rivera O, Estay J, Vernal R, et al. (2018) Quality of life and stability of tooth color change at three months after dental bleaching. Quality of Life Research, 27(12):3199–207.
3. Krastl G, Allgayer N, Lenherr P, Filippi A, Taneja P, Weiger R. (2013) Tooth discoloration induced by endodontic materials: a literature review. Dental Traumatology, 29(1):2–7.

GE015 | PUSH – OUT BOND STRENGTH OF TOTALFILL BIOCERAMIC SEALER TO ROOT DENTINE TREATED WITH DIFFERENT IRRIGATION SOLUTIONS

T. AL OMARI [1], A. DUKMAK [2]

[1] *Jordan University of Science and Technology, Irbid, JORDAN*
[2] *Jordan University of Science and Technology, Irbid, JORDAN*

AIM: This study aimed to compare the push-out bond strength (POBS) of TotalFill (TFB) bioceramic sealer with different irrigation solutions.

Methodology: The canals of sixty extracted maxillary central incisors were chemo-mechanically prepared and divided randomly into 3 groups (N=10) based on the final irrigation protocol using: 2.5% sodium hypochlorite (NaOCl) (Gourp-1), 2.5% NaOCl and 17% EDTA (Group-2), or 2.5% NaOCl + (HEDP) (Group-3). Samples in each group were obturated using TFB sealer using the sealer only. For groups 1 and 2, NaOCl 2.5 % was used during canal preparation, and irrigated with either NaOCl or NaOCl /EDTA in final irrigation, while in Group-3 HEDP and NaOCl was mixed and used throughout the treatment. After the sealer was set completely, teeth were sectioned horizontally using IsoMet 1000 saw to produce 3 sections of 3mm thickness at the apical, middle and coronal levels. A universal testing machine was used to perform the push-out test on the root sections at a 1mm/min speed. The mode of failure was assessed using an optical microscope and scanning electron microscope (SEM). Two-way ANOVA was used for statistical analysis

Results: All irrigation solutions showed similar POBS results. The bond strength was highest HEDP/TFB group (12.4 ±2..01 MPa) and lowest for group NaOCl (11.8 ± 1.85). Irrigation did not influence the POBS ($P>0.05$). Mixed failure was most observed among all the groups (>65%). The Coronal section has the highest values of POBS in NaOCl group (14.8 ± 5.60), and lowest with NaOCL/ EDTA group (9.73 ± 2.96). however, in the Middle and apical sections NaOCl/EDTA group score the highest POBS (13.7 ± 2.71) and (14.5 ± 4.28) respectively

Conclusions (mandatory): The irrigation solutions did not affect the POBS with TotalFill sealer, all irrigation solutions tested could possibly use with bioceramic without the effect on future restorative options.

GE016 | ANALYSIS OF PROCEDURAL ERRORS ASSOCIATED WITH SEPARATED INSTRUMENT MANAGEMENT IN MOLAR TEETH

S. BUKHARI [1], S. ZAHRAN [1], R. ALBALAWI [2], W. ALAMEER [2]

[1] *Assistant Professor, Endodontic Department, Faculty of Dentistry, King Abdulaziz University, Jeddah, SAUDI ARABIA*
[2] *General Dentist, Jeddah, SAUDI ARABIA*

AIM: While existing literature extensively discusses various management methods of separated instruments and their outcomes, there is a notable gap in understanding the relationship between management strategies and procedural errors. This study aims to explore this correlation to enhance clinical decision-making.

Methodology: Ethical approval was obtained, and a retrospective review of molar teeth managed by postgraduate endodontic residents at King Abdulaziz University Dental Hospital was conducted. Data were collected from patient records and radiographs. Procedural errors were independently assessed by two endodontists. Fisher exact test was used to determine the association between management strategies and procedural errors using SPSS.

Results: A total of 203 molar teeth were included. Molars with instrument separation were predominantly in apical third of the root and in canals with mild root curvature. Procedural errors were observed in 26.6% of molars, with perforation, being the most common accounting for 50% of procedural errors (13% of overall cases with separation). The management strategy did not significantly influence the occurrence of procedural errors (P=0.665). However, management of rotary files was associated significantly with more procedural errors when compared to hand files (P=0.047).

Conclusions (mandatory): This study highlights the challenges and considerations in managing separated instruments in endodontics, emphasizing the influence of instrument type, location, and operator experience on the occurrence of procedural errors.

GE017 | IMPACT OF BIOACTIVITY ON PUSH-OUT BOND STRENGTH OF AH PLUS BIOCERAMIC VERSUS BC BIOCERAMIC ROOT CANAL SEALERS

A. ALNOURY [1], S. ABU ZEID [2,3]

[1] *Restorative Department, Faculty of Dentistry, King Abdulaziz University, Jeddah, SAUDI ARABIA*
[2] *Endodontic Department, Faculty of Dentistry, King Abdulaziz University, Jeddah, SAUDI ARABIA*
[3] *Endodontic Department, Faculty of Dentistry, Cairo University, Giza, EGYPT*

AIM: This study compared the push-out bond strength and adaptation of the recently developed AH Plus bioceramic (AHP-Bio) root canal sealer with Bioceramic Endosequence (BC) and AH Plus (AHP) sealers when exposed to simulated body fluid for inducing bioactivity.

Methodology: Cross-section discs of 1 mm thick slices from obturated root canals were prepared and either kept dry or immersed in serum for 30 days. All discs were evaluated using scanning electron microscopy (SEM) and then subjected to a push-out test. The failure modes were also determined. The data were statistically analyzed using an ANOVA test at $p < 0.05$.

Results: In both environments, the BC sealer recorded the greatest bond strength, while the AHP-Bio sealer recorded the lowest mean values. However, bond strength was significantly improved after immersion in serum ($p < 0.001$). The chi-square test and Fisher's exact test revealed a significant difference in failure mode among the tested groups at $p < 0.001$. The predominant failure mode was cohesive failure in both bioceramic sealers, with the greatest value for AHP-Bio (70%), and adhesive failure for AHP/gutta-percha (60%, 80%) in both environments. SEM revealed good dentin adaptation of the three sealers, with marked decreases in gaps at the bioceramic/dentin interface after immersion in serum.

Conclusions (mandatory): In conclusion, although BC exhibited greater push-out bond strength than AHP-Bio, the latter achieved good displacement resistance that increased when the sealer was exposed to simulated body fluid (serum).

Acknowledgements (optional): The authors would like to thank all of the staff members working in the Advanced Technology Dental Research Laboratory at the Faculty of Dentistry, King Abdulaziz University, for their valuable assistance in the specimens' preparation.

GE018 | EFFICIENCY OF FRACTURED FILE RETRIEVAL USING ULTRASONIC INSTRUMENT ACCORDING TO THE DIFFERENT NICKEL-TITANIUM ALLOY AND FRAGMENT LENGTH

J. YOON [1], J. KIM [2], S. KWAK [1], H. KIM [1]

[1] *Department of Conservative Dentistry, Dental and Life Science Institute, School of Dentistry, Pusan National University, YANGSAN, SOUTH KOREA*
[2] *Department of Dental Education, Dental and Life Science Institute, School of Dentistry, Pusan National University and D, YANGSAN, SOUTH KOREA*

AIM: This study aimed to evaluate the removal efficiency of fractured files using ultrasonic instruments based on alloy type and fragment length, using standardized resin blocks as a model.

Methodology: Simulated J-shape canal blocks were shaped up to ProTaper Gold F2. The file tips of ProTaper Gold (PTG) F2 and ProTaper Universal (PTU) F2 files were artificially fractured to make the fragments of 3 mm and 4 mm, respectively (n = 25 for each system and length). The file fragments were inserted 1.5 mm coronal to the apical end of the simulated canal. A stopwatch measured the retrieval time to record the time taken for the fractured file to be removed from the canal using an ultrasonic instrument. The differences in retrieval time based on alloy type and fragment length were statistically analyzed at the significance level of 95% confidence.

Results: For 3 mm fragments, the PTU files demonstrated significantly shorter retrieval times than the PTG files ($P < .05$). However, no significant difference in retrieval time was found between PTG and PTU files for 4 mm fragments. The fragment of 3 mm length was removed in a significantly shorter time than the 4 mm fragment group, regardless of the file alloy types ($P < .05$).

Conclusions (mandatory): The length and alloy type of fractured NiTi files significantly influenced their removal efficiency in clinical settings. These findings highlight the importance of considering these factors when planning fractured file removal and emphasize the need for continued efforts to prevent file fractures.

GE020 | COMPARISON OF DIODE LASER AND SONIC ACTIVATION ON GUTTA-PERCHA/SEALER REMOVAL FROM CURVED ARTIFICIAL CANALS: AN IN VITRO STUDY

Z.G. ÜRÜN [1], B. ÜRÜN [1]

[1] *Nigde Omer Halisdemir University, Department of Endodontics, Nigde, TURKEY*

AIM: This study aimed to evaluate the efficiency of sonically activated (EDDY), and diode laser-activated (DL) irrigation in the removal of gutta-percha and sealer from simulated curved canals.

Methodology: Thirty-three transparent resin blocks with J-shaped canals were used in the study. All canals were shaped using T-Endo Must files with an apical diameter of 25/06 and filled with a single cone system using resin-based root canal sealer and matched size gutta-percha. All samples were retreated with ProTaper Universal Retreatment System files and then divided into three different groups according to the activation technique of irrigation. All protocols were executed for 3 × 20 s. Needle irrigation (NI) with a 27G needle served as the control group. The samples were sectioned at the apical 2 mm, middle third 6 mm, and coronal third 10 mm points and the remaining filling residues were recorded using a digital camera attached to the microscope under ×40 magnification. ImageJ software was used to analyze and measure the percentage of area covered by remaining obturation material. Data was obtained and evaluated statistically using Two-Way Repeated Measures ANOVA. The significance level was set at $P < 0,05$.

Results: In the apical third 2 mm curved section and middle third 6 mm section, EDDY gave significantly better results than NI and DL groups ($p<0,001$). The success of the DL group was found significantly different between the apical third 2 mm and coronal third 10 mm sections ($p=0,0017$). There was no significant difference between the irrigation success of the groups in the coronal 10 mm section ($p>0,05$).

Conclusions (mandatory): None of the irrigation activation methods have been able to completely remove sealer and gutta-percha residues from the root canals. EDDY gave the most successful results in the curved apical 2 mm section, which was the most difficult area to clean.

GE022 | EFFECT OF INTRACANAL CRYOTREATED SODIUM HYPOCHLORITE ON ROOT SURFACE TEMPERATURE REDUCTION AND ORGANIC TISSUE DISSOLUTION: AN IN VITRO STUDY

M.F. IPARRAGUIRRE NUÑOVERO [1], P.C. GOMES TITATO [2], A. KOWALCZUCK [1], U. XAVIER DA SILVA NETO [1], V. P DIETZEL WESTPHALEN [1], S. JOIA MIZRAHI JAKOBSON [1], B. CAVALINI CAVENAGO [3], M.A. HUNGARO DUARTE [2], E. CARNEIRO [1]

[1] *Pontificia Universidade Católica do Paraná, Curitiba, BRAZIL*
[2] *Universidade de São Paulo, Bauru, BRAZIL*
[3] *Universidade Federal do Paraná, Curitiba, BRAZIL*

AIM: This study aimed to evaluate the effect of intracanal irrigation with cryotreated sodium hypochlorite (NaOCl) on reducing root surface temperature and its ability to dissolve organic tissue.

Methodology: Twenty-five mandibular premolars were accessed and prepared using a 40.05 instrument, then subjected to two final irrigation protocols with 20 mL of 2.5% NaOCl at different temperatures: room temperature (control) and 2.5°C (experimental). The initial and minimum temperatures reached during irrigation in the last 4 mm of the root were recorded using a digital thermometer for both groups. For tissue dissolution analysis, glass capillaries filled with catgut were fixed in the cervical and apical thirds of twenty prototyped maxillary incisors. These capillaries were weighed before and after the irrigation protocols. The data were statistically analyzed.

Results: The final irrigation protocol with cryotreated NaOCl resulted in a significantly greater reduction in root surface temperature ($p < 0.05$). Both room-temperature and cryotreated NaOCl dissolved similar amounts of organic tissue, with no significant difference between groups ($p > 0.05$).

Conclusions (mandatory): Cryotreated NaOCl effectively reduced root surface temperature while maintaining its organic tissue dissolution capacity, comparable to the control group.

GE024 | SUBMICRO-DIAMONDS COMBINED WITH SONIC AGITATION ENHANCE BIOFILM DISRUPTION AND SEALER PENETRATION IN ROOT CANALS

E. CHANG [1], Y.S. HSU [1,2], S.C. HSIEH [1,2]

[1] *Taipei Medical University - College of Oral Medicine - School of Dentistry, Taipei, Taiwan, * OTHER*
[2] *Taipei Municipal Wan-Fang Hospital - Department of Dentistry, Taipei, Taiwan, * OTHER*

AIM: Biofilms, composed of bacteria and extracellular polymers, are highly resistant and can penetrate dentinal tubules, making eradication challenging. While sodium hypochlorite with sonic or ultrasonic agitation can reduce biofilms, complete elimination remains difficult. Our previous research demonstrated that 500 nm submicro-diamonds at 10 mg/ml, combined with sonic agitation, effectively remove the smear layer, particularly outperforming EDTA in the apical region.
The aim of this study was to evaluate the effectiveness of submicro-diamond irrigants for biofilm removal under sonic agitation.

Methodology: A total of 120 extracted single-rooted premolars were shaped to 0.25 mm using nickel-titanium rotary instruments. The teeth were immersed in an Enterococcus faecalis culture for 21 days to form biofilms. Irrigants consisting of 500 nm submicro-diamonds mixed with sodium hypochlorite were used with sonic agitation. Following cleaning, 60 specimens were observed under a scanning electron microscope (SEM). The remaining 60 canals were obturated with a calcium silicate-based sealer and Rhodamine B, and analyzed using confocal laser scanning microscopy. Biofilm removal efficiency was evaluated using dentinal tubule coverage, penetration area, and sealer penetration depth.

Results: SEM images showed that sonic agitation led to some biofilm removal in the coronal region across all irrigants. However, sodium hypochlorite with submicro-diamonds significantly reduced biofilm in the middle and apical regions compared to other groups ($p < 0.05$). Confocal microscopy confirmed these findings, showing enhanced biofilm removal and improved sealer penetration with submicro-diamonds.

Conclusions (mandatory): This study demonstrates that 500 nm submicro-diamonds, when combined with sonic agitation and sodium hypochlorite, significantly enhance biofilm removal and improve sealer penetration in root canals. The results show superior biofilm disruption, particularly in the middle and apical regions, compared to other irrigant solutions. The addition of submicro-diamonds provides an effective method for improving the cleaning efficiency of endodontic treatments, offering potential for more effective root canal disinfection.

GE026 | ENDODATA: A GAME-CHANGER FOR CLINICIANS AND RESEARCHERS

P. KUOCH [1], S. DAHAN [2], F. BRONNEC [2], G. CARON [2], L. ARBONA [3], A. BORDONE [4], A. PIETRI [5], F. SANTIAGO [2], L. LADREIT DE LACHARRIERE [2], C. COUVRECHEL [2]

[1] *Université Paris Cité, Department of restorative dentistry and endodontics, Paris, FRANCE*
[2] *Private Practice, Paris, FRANCE*
[3] *Private Practice, Montpellier, FRANCE*
[4] *Private Practice, Marseille, FRANCE*
[5] *Private Practice, Toulon, FRANCE*

AIM: This presentation aims to highlight the benefits of EndoData, an innovative and advanced software designed to assist endodontists in clinical decision-making and research. By streamlining clinical data collection and analysis, EndoData enhances both daily practice and scientific studies.

Methodology: In modern endodontics, efficient clinical data collection and management is crucial for clinical excellence and research advancement. EndoData is a specialized tool widely used in France with more than 200 000 patients listed since 2016. It facilitates real-time documentation and communication with patients and referral practitioners, automated outcome tracking, and structured data analysis. Available in several languages, it provides an intuitive interface for case documentation, improving diagnostic accuracy and treatment monitoring for clinicians. For researchers, it enables seamless data extraction and statistical analysis, enabling high-quality clinical studies with minimal administrative burden.
EndoData is capable to bridge the challenging gap between clinical practice and research, offering a powerful tool for both individual practitioners and the scientific community.
This presentation will explore the software's capabilities, practical applications, and its potential to improve patient care and scientific outcomes.

Results: - Enhanced Clinical Efficiency: EndoData simplifies case documentation and follow-up by creating complete reports.
- Enhanced Patient-Centered Care: improved patient involvement by real time information and shared decision-making.
- Improved Decision-Making: standardized clinical data collection supports evidence-based practice.
- Better Patient Outcomes Assessment: comprehensive tracking improves treatment evaluation.
- Facilitated Research: automated data extraction and analysis streamline clinical studies.
- Future Perspectives: potential for AI integration and broader application in endodontics.

GE027 | ABSTRACT: MANAGEMENT OPTIONS OF A TRUE RADICULAR DENS INVAGINATUS TYPE IIIB IN AN 9-YEAR-OLD PATIENT - A CASE REPORT

B. VAN GEYTE [1], J. BROCHADO MARTINS [1]

[1] *Department of Endodontology - Academic Center for Dentistry Amsterdam, University of Amsterdam and Vrije Universiteit, Amsterdam, THE NETHERLANDS*

AIM: To evaluate treatment modalities for a true radicular dens invaginatus (RDI) in a 9-year-old patient.

Methodology: A 9-year-old female was referred for evaluation and treatment of tooth 11 due to a long-standing buccal sinus tract. The patient reported no pain and was in good general health (ASA1). Extra-oral examination revealed no abnormalities. Intra-oral examination showed a wide crown of tooth 11 in disto-version (not fully erupted). The tooth exhibited no sensitivity to palpation or percussion, normal sensibility (cold test), and normal periodontal probing depths. A periapical radiograph of tooth 11 showed an abnormal crown and radicular shape as well as an apical radiolucency, while CBCT confirmed a true RDI Type IIIb, with a funnel-shaped lateral pseudocanal. The final diagnosis was chronic periodontal abscess with true RDI and pulp necrosis. Given the complexity of the case and the primary goal of restoring normal function and aesthetics with long-term prognosis, the following treatment options were considered:
- Orthograde treatment of the invagination and removal of the radicular part.
- Orthogarde treatment of the invagination and RCT + Intentional reimplantation + coronal reduction
- Orthograde treatment of the invagination and RCT + apical microsurgery + coronal reduction
- Extraction of tooth 11 and autotransplantation of tooth 25 to position of tooth 11
The true radicular variant of dens invaginatus (DI) is rare occurrence. Managing true RDI with apical periodontitis in both foramina is complex, and due to the poor prognosis, most cases are treated with extraction. Autotransplantation of tooth 25 to position 11 is a promising treatment that ensures better long-term prognosis and minimal complications compared to other invasive treatments.

Results: • Importance of early diagnosis of true RDI in pediatric patients.
• Autotransplantation is a promising non-experimental treatment option

GE028 | ENDODONTIC RETREATMENT: CLEANING YOUR WAY TO THE APEX

W. LAGMOU [1]

[1] *Moroccan academy of endodontics, Casablanca, MOROCCO*

AIM: This oral presentation aims to explore the efficiency and effectiveness of non surgical tridimensional endodontic retreatment procedures in comparison to conventional approaches. By examining the advancements in technology and their impact on retreatment outcomes, this presentation seeks to provide, through a comprehensive review of the literature, insights into optimizing clinical practices for better patient care.

Methodology: Non-surgical endodontic retreatment is a delicate therapy that aims to address the failure of previous root canal treatments, requiring a specialized technical platform and a clinical approach with several steps, allowing meticulous cleaning and correct shaping of the canal. The removal time of the previous filling material is the most crucial step, which requires an effective instrumentation, allowing access to the canal and its appropriate irrigation. The presentation will commence with an overview of endodontic retreatment challenges and will delve into the principles of tridimensional endodontic retreatment, highlighting its advantages. Comparative analyses between 3D and conventional retreatment methodologies will be discussed, regarding the different instruments used in the process of root canal retreatment, along with claiming the scientific analysis of their effectiveness and cleaning capacity. The presentation will also address practical clinical considerations by presenting clinical evidence to illustrate the practical application and efficacy of 3D endodontic retreatment.

Results: Understand the role of advanced instrumentation techniques, in facilitating efficient removal of previous filling material and optimizing canal cleaning and shaping.
Compare the outcomes of endodontic retreatment using the latest techniques for gutta-percha removal with those of conventional techniques
Emphasize the significance of appropriate irrigation techniques in conjunction with advanced instrumentation for effective debridement and disinfection of the root canal system
Gain a thorough understanding of both the advantages and obstacles associated with non surgical retreatment
Enable dental professionals to refine their clinical approaches during endodontic retreatment procedures.

GE029 | AGITATION METHODS INTENSIFY DENTINE ALTERATIONS AND CALCIUM REMOVAL DURING FINAL IRRIGATION WITH SODIUM HYPOCHLORITE FOLLOWED BY EDTA, BUT NOT WITH THE SODIUM HYPOCHLORITE–ETIDRONIC ACID MIXTURE

T. TARTARI [1], R. SANTOS CAIRES [1], L. ARANTES DE SOUZA LIMA [2], M.A. MARCIANO [1], A. DE JESUS SOARES [1], B.P. DE ALMEIDA GOMES [1], M.A. HUNGARO DUARTE [2]

[1] *Piracicaba School of Dentistry - UNICAMP, Piracicaba, BRAZIL*
[2] *Bauru School of Dentistry - USP, Bauru, BRAZIL*

AIM: To investigate the effects of final irrigation protocols, with or without agitation methods, on composition and calcium removal from dentine.

Methodology: Dentine discs from bovine teeth crowns were attached to the root of a prototyped canine tooth and distributed into three groups (n=40): G1 – 2.5% sodium hypochlorite (NaOCl, 5 min); G2 – 2.5% NaOCl (4 min) - 17% EDTA (1 min); G3 – mixture of 5% NaOCl + 18% etidronic acid (HEDP, 5 min). During the final minute of irrigation, subgroups were established based on agitation methods (n=10): a) no agitation; b) passive ultrasonic irrigation (PUI, Irrisonic-E1 insert); c) sonic agitation (Eddy tip); and d) continuous rotation (Easy clean), with subgroups “b”, “c” and “d” undergoing three 20-second cycles of dynamic agitation. Attenuated total reflectance in Fourier transform infrared spectroscopy was used to assess dentine composition changes by calculating the initial and final amide III/phosphate ratios. The irrigants used in each sample were collected and calcium removal from dentine was quantified using inductively coupled plasma optical emission spectroscopy. Data were compared by Wilcoxon and Two-way ANOVA with Tukey ($\alpha<0.05$).

Results: The results showed that all protocols altered dentine composition ($p<0.05$). NaOCl and NaOCl + HEDP subgroups exhibited similar reductions in the amide III/phosphate ratio ($p>0.05$), indicating collagen matrix degradation by NaOCl. NaOCl - EDTA subgroups increased the ratio, suggesting a potent chelating action of EDTA, with extensive mineral removal, and collagen matrix exposure. Only chelating-agent-containing protocols removed calcium, with NaOCl + HEDP causing less removal than NaOCl + EDTA ($p<0.05$). In NaOCl-EDTA subgroups the agitation significantly potentiated dentine alterations and calcium removal compared to non-agitation ($p<0.05$), with no differences among methods tested ($p>0.05$).

Conclusions (mandatory): All irrigation protocols altered dentine composition, but only those containing chelating agents promoted calcium removal. Agitation methods enhanced only EDTA effects with comparable outcomes.

Acknowledgements (optional): FAPESP PROCESS 2018/12690-5, 2023/12920-9

GE030 | ASSESSMENT OF DENTINE MATRIX PROTEINS ON DENTAL-PULP-STEM-CELL MIGRATION AND MINERALISATION

L. RAGUINE [1], S. ALAPATI [1], A. SLOAN [1], M. EVANS [1], R. MOSES [1]

[1] *University of Melbourne, Melbourne, AUSTRALIA*

AIM: Root canal treatment aims to alleviate clinical signs and symptoms of apical periodontitis through instrumentation and antimicrobial irrigation. Adjunct therapies to conventional root canal treatment are of growing interest. Dentine matrix proteins (DMPs) present in the dentine extracellular matrix have been suggested to regulate the formation of regenerative dentine in response to trauma or infection and have therapeutic potential to regenerate dentine, pulp, and periradicular tissues. Dental pulp stem cells (DPSCs) are crucial to this process. When exposed to growth factors, DPSCs can differentiate into odontoblast-like cells responsible for synthesising mineralised or pulp-like tissue in empty root canals. This study aims to assess the effect of DMPs on DPSCs in terms of cytotoxicity, mineralisation, gene expression and cellular migration. It is hypothesised that DMPs allow for periapical healing and/or dentine or pulp tissue regeneration.

Methodology: A colourimetric assay was performed to evaluate DPSCs viability, proliferation, and metabolic activation in the presence of DMPs. Alizarin red staining was utilised to visualise and quantify calcium deposition and the mineralisation capacity of DPSCs exposed to DMPs. Quantitative polymerase chain reaction (qPCR) was employed to analyse mineralisation markers RUNX2 and alkaline phosphatase expression. A transwell migration assay assessed cell migration in response to DMPs.

Results: Exposure to DMPs influenced the growth and mineralisation capacity of DPSCs. Expression of mineralisation markers was detected. DMPs possess chemotactic properties.

Conclusions (mandatory): Understanding signalling cues between DMPs and dental mesenchymal progenitor cells could provide valuable insights into their therapeutic potential. This highlights the importance of the quality of dentine in dental tissue regeneration, indicating that it serves a more active role than just being a passive structure.

GE031 | MIGRATION OF STREPTOCOCCUS ANGINOSUS AND ENTEROCOCCUS FAECALIS THROUGH DENTINE: AN EX-VIVO STUDY

Y. SHIBATA [1], S. ALAPATI [1], L. TEOH [1], A. SLOAN [1], M. EVANS [1], R. MOSES [1]

[1] *The University of Melbourne, Melbourne, AUSTRALIA*

AIM: Infected dental pulp occurs when bacteria invade the pulp tissue and form biofilms, triggering inflammation in the surrounding periapical tissue. This process can ultimately lead to apical periodontitis. Polymicrobial infections, particularly those involving Streptococcus anginosus (S. anginosus) and Enterococcus faecalis (E. faecalis), significantly reduce the viability of the dentin-pulp complex. Therefore, understanding bacterial penetration mechanisms is crucial to elucidating how bacteria invade tooth structures and contribute to apical pathosis.

Methodology: A three-dimensional organotypic tooth-slice model using non-carious extracted third molars was developed. Transverse slices (2 mm) were sectioned with a minitom and inoculated with planktonic bacterial cultures. Colony-forming units (10^3 and 10^2/mL) were cultured on the tooth slices in brain heart infusion, maintained at 37°C in a 5% CO2/95% air environment for 24 hours. Tooth slices were fixed with 2.5% glutaraldehyde in PBS, ethanol-dehydrated, critically dried, gold sputter-coated and then examined using scanning electron microscopy (SEM). SEM images were acquired from pulp tissue, predentine, and mantle dentine regions. Bacterial attachment and penetration into dentinal tubules were quantified using Fiji image analysis software (Fiji, GNUv3.0).

Results: Bacterial apposition was predominantly observed in the pulp tissue, predentine, and mantle dentine regions, in descending order of prominence. E. faecalis demonstrated a higher attachment and penetration rate of 85% into dentinal tubules, compared to a 60% penetration rate for S. anginosus. Both species demonstrated a strong affinity for pulp tissue, particularly in areas of vasculature, with E. faecalis exhibiting the highest level of attachment.

Conclusions (mandatory): The quantitative data highlight the differences between S. anginosus and E. faecalis, particularly in their behaviour and interactions within a host environment. Understanding the complex relationships between these bacterial species and the host environment will pave the way for improved diagnostic and treatment strategies for apical pathosis.

Acknowledgements (optional): The University of Melbourne

GE032 | Regenerative Endodontic Treatment for Immature Teeth: A Case Series

Salihanur Sarı, Gülsen Kiraz

Kutahya Health Sciences University, Faculty of Dentistry, Department of Endodontics, Kutahya, Türkiye

AIM - To present a regenerative endodontic treatment procedure for immature teeth by utilizing different intracanal medicaments in two distinct cases.

INTRODUCTION - Regenerative endodontic procedures are biologically driven treatments that restore damaged tooth structures and promote pulp-dentin complex regeneration. Over the past two decades, they have gained widespread use, particularly for immature teeth with pulp necrosis. While mechanical preparation reduces the microbial load, the limited extent of instrumentation and the complex canal anatomy in regenerative treatments often hinder complete disinfection. Thus, intracanal medicaments like calcium hydroxide and triple antibiotic paste are commonly used for microbial control.

CASE PRESENTATION- CASE 1

A systemically healthy 27-year-old male patient presented for a routine examination. Tooth #21 exhibited an open apex without sensitivity. Under rubber dam isolation, the canal was irrigated with 20 mL of 1.5% sodium hypochlorite for 5 minutes, followed by 5 mL of saline, and 20 mL of 17% EDTA. After drying, calcium hydroxide (Ultracal XS; Ultradent Products South Jordan, USA) was applied, and a temporary restoration was placed. At the second visit, the canal was re-irrigated with 20 mL of 17% EDTA and 5 mL of saline. Bleeding was induced with a #40H-file with a rotational motion, leading to the formation of a blood clot 2 mm below the gingival margin. Mineral Trioxide Aggregate MTA; Angelus, Brazil) was placed 2 mm below the cemento-enamel junction, followed by adhesive restoration (G-ænial, GC Corporation, Tokyo, Japan). At follow-up, palpation and percussion tests were negative, and the tooth remained non-responsive to vitality and cold tests. Radiographic evaluations revealed an increase in root length and thickness.

CASE 2

A 46-year-old systemically healthy male patient presented for a routine examination. He had previously undergone root canal treatment on teeth #11 and #21. Regenerative endodontic treatment was planned for tooth #11, while MTA apical plug treatment was planned for tooth #21. At the first visit, under rubber dam isolation, the root canal filling was removed. The irrigation was performed as in Case 1. After drying, 5 mg/mL triple antibiotic paste (metronidazole, ciprofloxacin, minocycline at a 1:1:1 ratio) was applied. At the second visit, irrigation with 17% EDTA and 5 mL of saline was performed. A #40 H file was used to induce periapical bleeding, forming a blood clot 2 mm below the gingival margin. MTA was placed, followed by light-cured glass ionomer cement and composite resin restoration. At follow-up, palpation and percussion tests were negative, and the tooth remained non-responsive to vitality and cold tests. Radiographic evaluations revealed an increase in root length and thickness.

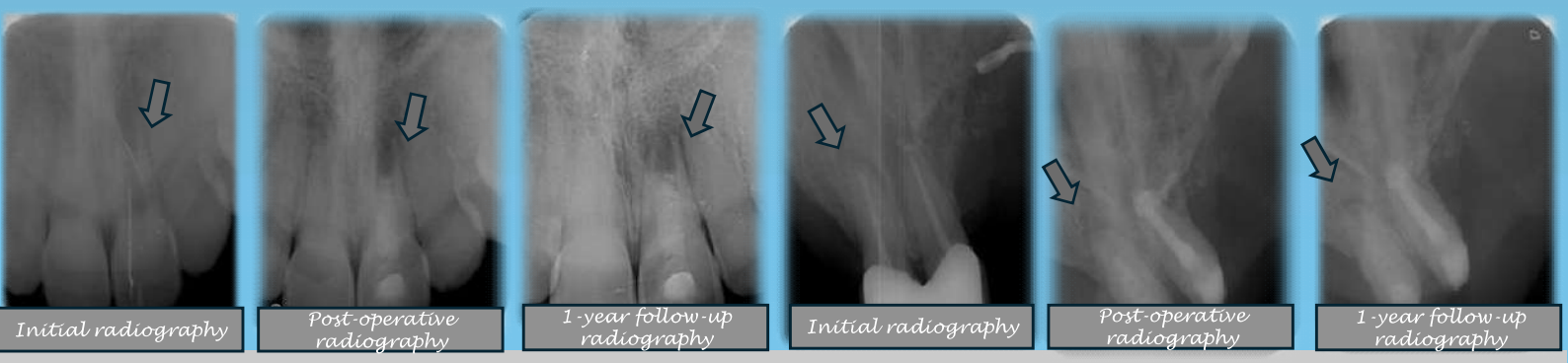

DISCUSSION - Studies indicate that regenerative endodontic treatments using triple antibiotic paste and calcium hydroxide achieve superior outcomes compared to MTA apexification. Clinicians with appropriate training should consider this approach as a viable alternative to apexification on a case-by-case basis. As evidence supporting the clinical applicability of regenerative endodontic treatments continues to grow, these procedures are expected to become standard practice in endodontics.

CLINICAL RELEVANCE - Various intracanal medicaments, including calcium hydroxide and triple antibiotic paste, are utilized in regenerative endodontic treatment. The success of this approach depends on both effective bacterial elimination within the root canal system and strict adherence to procedural protocols.

REFERENCES

1- Segura-Egea, JJ., Gould, K., Hakan Şen, B., et al. (2018). European Society of Endodontology position statement: the use of antibiotics in endodontics. *International Endodontic Journal*, *51*(1), 20-25.
2- Ribeiro, J.S., Münchow, E.A., Bordini, E.A.F., da Rosa, W.L.D.O., Bottino, M.C. (2020). Antimicrobial therapeutics in regenerative endodontics: a scoping review. *Journal of endodontics*, *46*(9), 115-127.

GE033 | GLIDE PATH WITH NITI INSTRUMENTS: FULL ROTARY MOTION, RECIPROCATION OR TACTILE CONTROLLED ACTIVATION? LITERATURE REVIEW AND REPORT OF RESPECTIVE CASES.

A. CHARALAMPAKI [1], T. KONTOGIANNIS [2]

[1] *Dental School, National & Kapodistrian University of Athens, Athens, GREECE*
[2] *Dental School, National & Kapodistrian University of Athens, Athens, GREECE*

AIM: To compare the effectiveness of three motions of rotation in glide path instruments (full rotary, reciprocation and tactile controlled activation) based on the literature, as well as to present respective clinical cases of each type of movement.

Methodology: A literature review was carried out between 1990 & 2024. The key words used were “glide path”, “rotary files for glide path”, reciprocation” & “tactile controlled activation”. Furthermore, one case for each technique is presented; in all cases, the same glide path instrument was used (a new one for each tooth). All cases were primary root canal treatments and were all treated by the same clinician (T.K.).

Results: Literature review showed that reciprocation is considered to be the best option, thanks to less transportation of the canal and higher fracture resistance. However, data on tactile controlled activation used on glide path files is still scarce; further research is required. In terms of the cases presented, the tactile controlled activation, although more time-consuming, provided the clinician with better tactile sense during glide path creation.

Conclusions (mandatory): Reciprocation seems to be better for glide path instruments than full rotary movement; however, the application of tactile controlled activation may be equally promising.

GE035 | DIABETES MELLITUS AND PERIAPICAL HEALTH IN ENDODONTICALLY TREATED TEETH: A SYSTEMATIC REVIEW

H. HIMANI [1]

[1] *All India Institute of medical Sciences, Kalyani, West bengal, INDIA*

AIM: This systematic review will assess the impact of diabetes mellitus on periapical healing outcomes in endodontically treated teeth.

Methodology: Periapical diseases are prevalent dental conditions that necessitate non-surgical endodontic treatment for effective management. However, the impact of diabetes mellitus (DM) on periapical healing outcomes in affected individuals remains inadequately elucidated. Evaluating the impact of diabetes mellitus on periapical health in endodontically treated teeth is vital for optimizing therapeutic strategies and improving patient prognosis.
A thorough search of electronic databases, including PubMed, Scopus, Web of Science, and Embase, will be performed in accordance with PRISMA guidelines. Studies evaluating the periapical status of endodontically treated teeth in diabetic and non-diabetic patients will be included. A comprehensive assessment of bias risk and study quality will be conducted for all included studies.

Results: This review anticipates to assess the effect of diabetes mellitus on periapical healing outcomes in endodontically treated teeth.
This review will systematically analyze the existing evidence to elucidate the diabetes-periapical healing relationship, aiding clinicians in optimizing treatment outcomes.

GE036 | OSTEOPOROSIS AND ITS IMPACT ON PERIAPICAL HEALTH AFTER NON SURGICAL ENDODONTIC TREATMENT: A SYSTEMATIC REVIEW

S. J PARVATHY [1]

[1] *All India Institute of medical Sciences, Kalyani, West bengal, INDIA*

AIM: The aim of this study was to evaluate the impact of Osteoporosis on Periapical Health after non surgical endodontic treatment.

Methodology: Numerous risk factors are shared between systemic diseases and oral infections, which may complicate understanding the potential connection between them. Osteoporosis, the most prevalent bone disorder, is characterized by a reduction in bone mass, degeneration of bone tissue, and disruption of bone microstructure, leading to weakened bone strength and an increased risk of fractures. However, the effect of osteoporosis on dental health, particularly on periapical health following non-surgical endodontic treatment, remains uncertain. Although existing studies suggest possible complications, no systematic review has yet thoroughly explored the link between osteoporosis and periapical health outcomes after such treatments. This review aims to fill this gap by investigating how osteoporosis might affect the healing process and outcomes of non-surgical endodontic procedures.
A systematic search will be conducted across major databases such as PubMed, Scopus, EBSCO and Web of Science in accordance with the guidelines outlined in the Preferred Reporting Items for Systematic Reviews and Meta-Analyses (PRISMA) statement. Data extraction will focus on periapical health outcomes and the quality of included studies will be assessed.

Results: This systematic review is expected to provide valuable insights into how osteoporosis influences the periapical tissues after non-surgical endodontic treatment.
The review will contribute to understanding the implications of osteoporosis on endodontic treatment outcomes, ultimately guiding clinicians in managing patients with osteoporosis who require non-surgical endodontic care.

GE037 | DOES THE USE OF PREOPERATIVE CONE BEAM COMPUTED TOMOGRAPHY (CBCT) IMPACT THE OVERALL LENGTH OF CLINICAL TREATMENT IN ENDODONTICS

T. HORGAN [1], I. HUSSAIN [2], S. BHATTI [3]

[1] *Specialty Trainee Endodontics, Manchester Dental Hospital, Department of Restorative Dentistry, Manchester, UNITED KINGDOM*
[2] *Clinical teaching Fellow Endodontics, Manchester Dental Hospital, Department of Restorative Dentistry, Manchester, UNITED KINGDOM*
[3] *Consultant in Restorative Dentistry, Manchester Dental Hospital, Department of Restorative Dentistry, Manchester, UNITED KINGDOM*

AIM: To evaluate decision making regarding provision of CBCT scans and their impact on the overall treatment for patients having endodontic treatment at Manchester Dental Hospital

Methodology: A retrospective assessment of records for forty patients was carried out. All patients were referred by their Dentist and then assessed by a specialist endodontist. Reasons for referral included fractured instruments, managing complex anatomy and difficult retreatments. Patients were subsequently booked for either treatment or a CBCT before treatment.
20 patients had a CBCT to aid treatment and 20 patients had treatment without a CBCT. All records were selected at random. All treatment was carried out by postgraduate students on an endodontic training programme.
In the CBCT group 13 patients had a CBCT prior to starting treatment while 7 had a CBCT requested mid treatment.

Results: Twenty-three were male while seventeen were female. The average age was 42, with the youngest being 17 and eldest 77.
There were 14 teeth needing re root treatment in the CBCT group and 6 in the non CBCT group. The average number of visits for completion of treatment for cases who had no CBCT or who had the CBCT requested during treatment was five visits. The average number of visits for patients who had the CBCT pretreatment was three. In the cases who had a CBCT prior to starting treatment, the most common indication for the CBCT was for teeth which required re root canal treatment.

Conclusions (mandatory): Within the limitations of this study CBCT taken prior to starting treatment reduces the overall duration of treatment within a teaching environment. This has to be balanced with exposing the patient to further radiation and cost. The decision to take a CBCT is affected by the operator's experience but incorporation of CBCT into clinical practice must be part of a standardised digital protocol.

GE038 | TREATMENT OF ENDODONTICALLY TREATED TEETH WITH THE ENDOCROWN APPROACH IN A SINGLE-VISIT

Bartu Benliay, Betul Aycan Uysal

Health Science University, Faculty of Dentistry, Department of Endodontics, Istanbul, Türkiye

Aim: This study aimed to present the indirect endocrown restorations of 3 endodontically treated molar teeth.

Introduction: Endodontic treatment is common in dental practice (1). However, it can weaken the tooth and reduce its mechanical properties due to the loss of tooth structure (1, 2). This loss of structure reduces the fracture resistance, affecting the tooth's long-term survival rate. Endocrowns are a suitable restorative option for endodontically treated posterior teeth, especially when there is significant tooth structure loss. They are primarily made from lithium disilicate glass-ceramic and can be fabricated using heat pressing or CAD/CAM technology (3).

Case 1: A 23-year-old male patient presented with a large periapical lesion and a failed coronal restoration in the right mandibular first molar. Following the evaluation, a diagnosis of chronic apical periodontitis was established, and retreatment was planned. The existing root canal filling was removed, and the canals were reshaped (Endoart, Inci Dental, Turkey). Subsequently, calcium hydroxide medication was applied for three weeks. In the second session, an apical plug was created in the distal canal using mineral trioxide aggregate (MTA) (Pro Root MTA, Dentspyl-Sirona, USA), while the mesial canals were filled with a resin-based root canal sealer (Dentac Sealart, Turkey) using the lateral condensation technique. A digital impression was taken with a Dentsply-Sirona (Germany) scanning device, and an endocrown was designed. After the milling process, the restoration was subjected to surface treatments and cemented adhesively to the tooth. Clinical and radiographic evaluations showed regression of symptoms and a functionally and esthetically successful restoration. The patient is following-up.

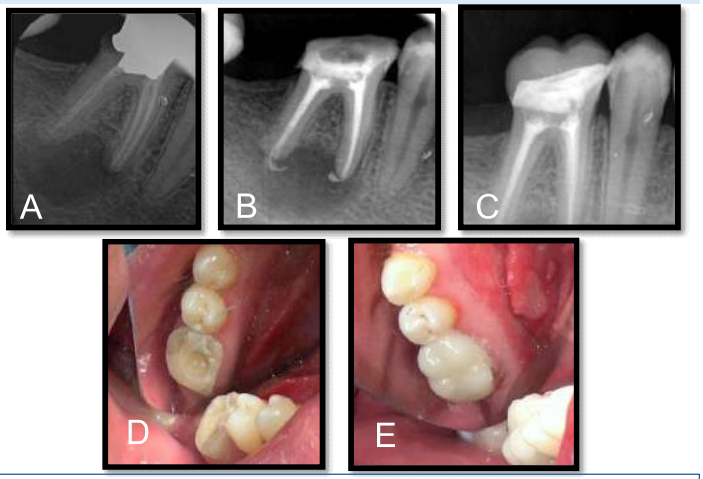

Figure 1. A: Pre-operative radiography. B: Post-operative radiography C: After cementation radiography. D: Intraoral preparation E: After intraoral cementation

Case 2: A 16-year-old female patient presented to our clinic with deep caries in the left mandibular first molar and radiolucency in the apical region. Following clinical and radiographic evaluation, a diagnosis of chronic apical periodontitis was established, and root canal treatment was planned. During endodontic treatment, the canals were shaped using Ni-Ti rotary files (Endoart, Inci Dental, Turkey) and ultrasonic activation. The treatment was completed with a resin-based root canal sealer (Dentac Sealart - Turkey) and gutta-percha.

In the restorative phase, a composite filling (Ruby Dental - Turkey) was used for core buildup, followed by tooth preparation and digital impression taking. After the design and milling processes were completed using the CAD/CAM system (Dentsply Sirona - Germany), the endocrown restoration underwent surface treatments and was adhesively cemented to the tooth on the same day. Clinical evaluations confirmed the functional and esthetic success of the treatment, and the patient is following-up.

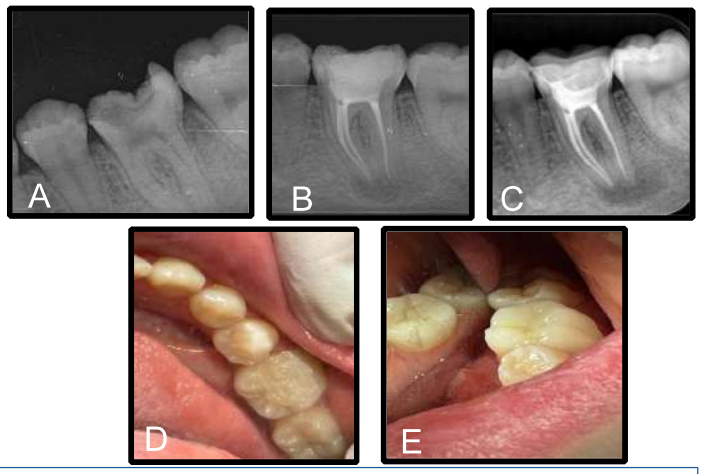

Figure 2. A: Pre-operative radiography. B: Post-operative radiography C: After cementation radiography. D: Intraoral preparation E: After intraoral cementation

Case 3 : In a 48-year-old male patient, a failed amalgam restoration and radiolucency in the apical region were detected in the left maxillary first molar. Following clinical and radiographic evaluation, a diagnosis of chronic apical periodontitis was established, and root canal treatment was planned. After shaping with Ni-Ti rotary instruments (Endoart, Inci Dental, Turkey), calcium hydroxide was applied inside the canal for three weeks. The root canal treatment was then completed using a resin-based sealer (Dentac Sealart - Turkey) and gutta-percha. In the restorative phase, a core build-up was performed using composite filling material (Ruby Dental - Turkey), followed by tooth preparation and digital impression taking (Dentsply Sirona - Germany). The endocrown restoration was adhesively cemented to the tooth, completing the treatment. Clinical and radiographic evaluations confirmed the functional and esthetic success of the procedure, and the patient is following -up.

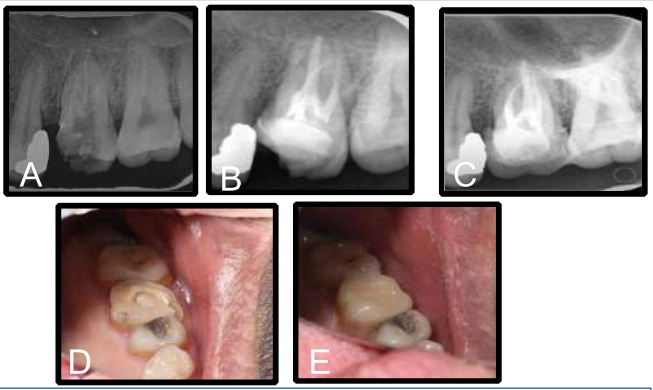

Figure 3. A: Pre-operative radiography. B: Post-operative radiography C: After cementation radiography. D: Intraoral preparation E: After intraoral cementation

Discussion: Endocrown restorations offer biomechanical advantages in endodontically treated teeth by preserving tooth structure and reducing the risk of fracture. While CAD/CAM technology ensures high precision and esthetics, it comes with a higher cost (3).

Clinical Relevance: Endocrown restorations offer an alternative to conventional crowns by preserving more tooth structure in endodontically treated teeth. Adhesive cementation and CAD/CAM technology ensure high durability and esthetic success. However, the need for specialized equipment increases the cost. Despite this, they remain a valuable clinical option for functional and long-lasting tooth restoration.

References

1. Ciobanu P, Manziuc MM, Buduru SD, Dudea D. Endocrowns - a literature review. Med Pharm Rep. 2023 Oct;96(4):358-367.
2. Papalexopoulos D, Samartzi TK, Sarafianou A. A Thorough Analysis of the Endocrown Restoration: A Literature Review. J Contemp Dent Pract. 2021 Apr 1;22(4):422-426.
3. AlDabeeb DS, Alakeel NS, Al Jfshar RM, Alkhalid TK. Endocrowns: Indications, Preparation Techniques, and Material Selection. Cureus. 2023 Dec 5;15(12):e49947.

GE039 | MANAGEMENT OF A SEVERE CURVATURE AND LARGE PERIAPICAL LESION

I. MUSLIM [1], J. CAMILLERI [1]

[1] *University of Birmingham, Birmingham, UNITED KINGDOM*

AIM: This case report highlights the management of a maxillary second premolar with a severely curved root and a large apical radiolucency, demonstrating successful periapical healing

Methodology: Severely curved canals and large apical lesions pose significant challenges in endodontic treatment. However, with proper assessment, technique, and material selection, predictable healing can be achieved. This case report highlights the management of a maxillary second premolar with a severely curved root and a large apical radiolucency, demonstrating successful periapical healing. A 34-year-old female was referred for endodontic evaluation after a routine radiographic examination revealed a large apical lesion on tooth #25, extending toward tooth #24. The tooth was diagnosed with pulp necrosis and asymptomatic apical periodontitis. Due to the severe curvature, the root canal was instrumented using NiTi files (TruNatomy) with a conservative approach, followed by single cone and hydraulic cement sealer (CeraSeal) obturation. Irrigation protocols were optimized with 5.25% sodium hypochlorite (NaOCl) and 17% EDTA, all activated using sonic device (EndoActivator) (30s for NaOCl, 1 min for EDTA, and a final 30s NaOCl rinse) to ensure effective disinfection. Follow-up radiographs at six months confirmed significant lesion regression based on PAI index, indicating periapical healing. This case underscores the importance of thorough root curvature assessment using periapical radiographs taken at multiple angulations and measured with the Schneider method, along with used of an operating microscope to aid in canal identification, strategic file selection and advanced materials to achieve successful outcomes in complex endodontic cases.

Results: • Severely curved canal
• Large apical lesion
• Bioceramic sealer
• Periapical healing

GE040 | EFFECT OF INTRACANAL CRYOTHERAPY TEMPERATURES AND ITS DELIVERY ON THE FRACTURE RESISTANCE OF ENDODONTICALLY TREATED TEETH

J.C. DA WEI [1], A.B. SAFURA [1], L.S. WONG [2]

[1] *National University of Malaysia, Department of Restorative Dentistry, Faculty of Dentistry, Kuala Lumpur, MALAYSIA*
[2] *National University of Malaysia, Department of Craniofacial Diagnostic and Biosciences, Faculty of Dentistry, Kuala Lumpur, MALAYSIA*

AIM: The study aims to provide insights into the effects of intracanal cryotherapy on the mechanical properties of endodontically treated teeth, aiding in determining the feasibility of advocating intracanal cryotherapy for managing post-operative endodontic pain.

Methodology: One hundred thirty-five single-rooted maxillary premolars were collected and divided into nine groups. After chemo-mechanical preparation, teeth were placed in a 37°C water bath. The final irrigation using their respective irrigant delivery system was done using 20 ml of saline solution at the assigned temperature for 5 minutes. The groups include a control with one solution at room temperature, two cryotherapy groups (2.5°C and 13.5°C) with EndoVac, and similar groups with a 27-gauge side-vented needle or IrriFlex tip. Saline solutions and tips were refrigerated at the specified temperatures before use. The roots were then coated with silicone, mounted in self-cure acrylic and then subjected to a fracture test using a universal testing machine with a bar-shaped stainless steel horizontal indenter (3 mm in diameter) at a crosshead speed of 1mm/min until occurrence of fracture. The maximum fracture load (N), was recorded and analysed using the Kruskal-Wallis test.

Results: The median maximum fracture load (N) of EndoVac groups at room temperature, 2.5°C and 13.5°C were 727.4N, 506.91N and 684.54N respectively. As for the side-vented needle at room temperature, 2.5°C and 13.5°C were 643.46 N, 572.25N and 722.06N respectively. And finally, for Irriflex at room temperature, 2.5°C and 13.5°C were 723.64 N, 538.56N and 812.57N respectively. Although there was a decrease in the fracture resistance of teeth after cryotherapy using 2.5°C, the differences were not statistically significant ($P>0.05$)

Conclusions (mandatory): This study found that using cryotherapy during an endodontic procedure doesn't weaken its fracture resistance. Hence, cryotherapy can be an efficient and cost-effective way to reduce post-operative endodontic pain.

GE043 | MANAGEMENT OF MULTIPLE TRAUMATIC DENTAL INJURIES IN MIXED DENTITION

R.K. SINGH [1]

[1] *King Georges Medical University, Department of Paediatric and Preventive Dentistry, Lucknow, INDIA*

AIM: To optimally manage a case of multiple traumatic dental injuries in a paediatric patient

Methodology: An 8-year-old male patient was referred to our department for the management of traumatic dental injuries. He presented 24 hours post-injury with three avulsed teeth, which had been wrapped in paper. The patient had been involved in an accident and was initially treated at a private hospital for a leg fracture and multiple orofacial injuries before being referred to us for dental trauma care.
Clinical examination revealed that the patient had avulsed his left permanent maxillary central incisor along with two primary incisors, while his right permanent maxillary central incisor was intruded. The avulsed permanent tooth was replanted and splinted in two sections, excluding the intruded incisor. Following splinting, the MTA Barrier Technique was applied.
Follow-up examinations at 1, 3, and 6 months showed no signs of periapical resorption in the traumatized teeth, and the intruded incisor exhibited spontaneous re-eruption.

Results: • Comprehensive Assessment – A thorough evaluation of the patient's condition guided the treatment plan, considering both dental and systemic injuries.
• Choice of Apexification Over Revascularization – Due to the patient's extended recovery period for a leg fracture, apexification was preferred for better predictability and prognosis.
• Challenges in Isolation – The presence of inflammatory gingival fluid and early mixed dentition complicated the procedure, requiring innovative solutions like a two-sectioned splint.
• Importance of Proper Tooth Storage – The avulsed teeth were initially stored improperly (wrapped in paper), highlighting the need for public awareness on appropriate tooth preservation methods.
• Role of Systemic Antibiotics and Follow-Up Care – Regular check-ups, antibiotic therapy, and patient instructions were critical to successful healing and preventing complications.
• Need for Further Research – The case emphasizes the necessity for continued studies to establish the best endodontic approaches for pediatric dental trauma cases.

GE044 | RETRIEVAL OF ENDODONTIC FILE SEPARATED BEYOND THE CURVATURE IN MAXILLARY MOLAR

Bojan Dželetović (presenting author), Tatjana Savić Stanković, Maja Ležaja Zebić
School of Dental Medicine, University of Belgrade

AIM - To report a clinical case of broken file retrieval from beyond the curvature of bucco-distal canal of maxillary molar.

INTRODUCTION - Instrument separation is a mishap that can occur during endodontic treatment as a result of complex root canal morphology or procedural errors. This complication prevents optimal cleaning of root canal system that can result in infection persistence and periapical lesion formation.

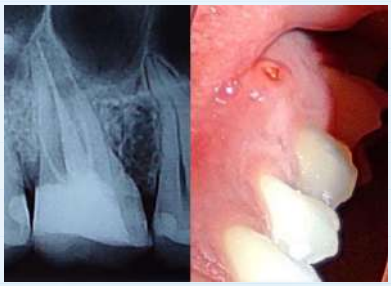

Fig. 1. Pre-operative radiogram and clinical image



Fig. 2. Radiogram after secondary separation and retrieval



Fig. 3. Radiogram after complete file retrieval and removed fragments

CASE PRESENTATION - Female patient was referred to our department due to persistent sinus tract at vestibular projection of the periapical region of maxillary left first molar. Medical history was nonsignificant but patient had intermittent mild bite sensitivity. Periapical radiography showed inconsistent filling in bucco-distal canal with a break in continuity and apical part presumed to be separated endodontic file (Fig. 1). After old filling was removed from the canals using Gates–Glidden burs and reciprocating file system, the block was found in bucco-distal canal. In order to obtain straight-line access to the broken file and soften the curve of blocked canal it was needed to remove portion of the distal wall of distal canal and extend its access distally. This allowed visibility with an aid of dental microscope (40x). Using ultrasonic endodontic tip, a platform around the coronal aspect of the fragment was formed and vibrations precisely transferred to its coronal end. These vibrations loosened up, separated and popped-up coronal portion of the fragment which was confirmed by radiogram (Fig. 2). To allow good visibility of the remaining secondary fragment additional access extension distally was necessary. During this distal wall of the bucco-distal canal was perforated 1mm from its entrance. Another platform around the coronal aspect of the secondary fragment was formed and ultrasonic vibrations transferred to it. Finally, secondary fragment was loosened up and retrieved. Patency was achieved along entire canal and removal of the fragment was confirmed radiographically (Fig. 3). Instrumentation of root canal system was finished using reciprocating file system and irrigation with 1% sodium hypochlorite and 10% citric acid. Calcium-silicate material was applied at perforation site and compacted against weakened walls of buco-distal canal with a gutta-percha point used as a space keeper, in order to strengthen the orifice (Fig. 4). Calcium hydroxide medicament was placed for a week. During the next visit, sinus tract receded, canals were obturated using gutta-percha cone with epoxy-based sealer and radiogram was taken to assess filling quality (Fig. 5). Two years and ten months later, control clinical examination revealed absence of any symptoms and radiography confirmed favorable outcome (Fig. 6).



Fig. 4. Repair of weakened canal wall



Fig. 5. Post-obturation radiogram and clinical image



Fig. 6. Control radiogram after two years and ten months

DISCUSSION - Removal of fractured endodontic file should be performed with minimal root dentin damage but it is not always possible to preserve original canal shape. Due to the need for straight-line access to separated fragment, in our case, it was necessary to reduce portion of the canal wall.

CLINICAL RELEVANCE - Specialized ultrasonic tips for fractured files removal are relatively simple, conservative and low-cost solution for this endodontic complication. On the other hand, it requires to sacrifice dental tissue, so in some cases it is important to find the compromise and repair the damage afterwards.

REFERENCES

1. Y.Terauchi, WT Ali, MM Abielhassan (2022) Present status and future directions: Removal of fractured instruments. Int Endod J, 55(3), 685-709.
2. Terauchi Y, Sexton C, Bakland LK, Bogen G (2021) Factors Affecting the Removal Time of Separated Instruments. J Endod, 47(8), 1245-1252.
3. Suter B, Lussi A, Sequeira P (2005) Probability of removing fractured instruments from root canals. Int Endod J, 38, 112-123.

GE045 | IATROGENIC FURCAL PERFORATION REPAIR IN FIRST MANDIBULAR MOLAR: 8-YEARS FOLLOW-UP

Bojan Dželetović, Azra Tutić (presenting author), Maja Ležaja Zebić
School of Dental Medicine, University of Belgrade

AIM - To report a case of successful conservative therapy of left first mandibular molar with a large furcal perforation.

INTRODUCTION - Iatrogenic root perforations are procedural mishap that can be significant cause of endodontic therapy failures. Perforations that occur during access cavity preparation or canal orifice exploration can compromise root integrity and be challenging for treatment.



Fig. 1. Furcal perforation

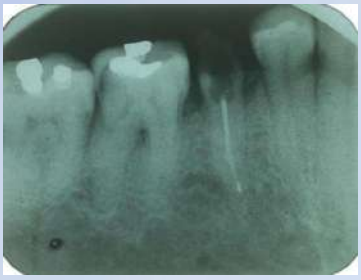

Fig. 2. Preoperative radiogram

CASE PRESENTATION - A 42-year-old female patient was referred to our department after iatrogenic furcal perforation related to inadequate access to pulp chamber of left first mandibular molar that was diagnosed as symptomatic pulpitis. Clinical examination revealed massive furcal perforation localized closer to lingual pulp chamber wall and distal root (Fig. 1) while preoperative radiogram showed quite obliterated pulp chamber and root canals (Fig. 2). Also, generalized wear of teeth was visible and probably could be attributed to parafunctional behaviors (Fig. 3). After evaluation of the defect size and location, canal orifices were identified and perforation sealed with calcium silicate-based material inserted by hand instrument. The material was condensed using fat end of a paper point (Fig. 4) and covered with glass ionomer cement as a temporary filling. X-ray was taken to check the quality of material placement (Fig. 5). Patient showed up after one year and eight months but with calcium silicate material still present in the defect and radiography revealed asymptomatic apical periodontitis (Fig. 6). Root canals were instrumented using rotary file system and irrigated with 1% sodium hypochlorite and 10% citric acid. Calcium hydroxide paste was applied as an intracanal dressing for two weeks and canals were obturated using single cone technique and epoxy resin sealer (Fig. 7). The tooth was restored with glass ionomer cement and resin-based composite filling. Six years later, during control examination, patient was symptom free, without percussion and palpation sensitivity and radiographic examination showed satisfactory outcome (Fig. 8).



Fig. 8. Control radiogram after around eight years



Fig. 3. Enamel/teeth wear



Fig. 7. Post-obturation radiogram



Fig. 4. Perforation defect repair



Fig. 6. Radiogram after 20 months asymptomatic apical periodontitis

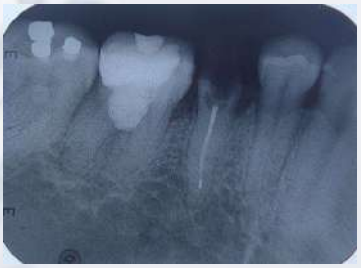

Fig. 5 Control radiogram

DISCUSSION - Narrowing of the root canals makes endodontic therapy challenging and errors such as failure to locate the canal, excessive dentin removal or root perforation are more likely. Root perforation significantly raise the endodontic therapy difficulty and its prognosis is influenced by several factors such as size, location, shape and time before treatment.

CLINICAL RELEVANCE - Beside appropriate planning and careful clinical technique, the essential requirement for desirable treatment outcome is the use of materials with properties favorable for repair process. Calcium silicate-based materials are capable of stimulating healing process without significant negative impact even in cases without a barrier during condensation and extrusion of the material into surrounding tissues. Favorable outcome and prolonged survival of the tooth is possible even in neglected cases and large defects.

REFERENCES

1. Clauder T (2022) Present status and future directions - Managing perforations. Int Endod J, 55(4), 872-891.
2. Camilleri J, Atmeh A, Li X, Meschi N (2022) Present status and future directions: Hydraulic materials for endodontic use. Int Endod J, 55(3), 710-777.

GE046 | PERIAPICAL LESION HEALING AFTER SEPARATED INSTRUMENT RETRIEVAL AND RETREATMENT OF LOWER MOLAR

Bojan Dželetović, Jovana Prljinčević (presenting author), Jelena Nešković
School of Dental Medicine, University of Belgrade

AIM – To report a clinical case of successful treatment outcome after retrieval of separated instrument and retreatment of lower first molar with periapical lesion.

INTRODUCTION - Separation of endodontic instrument is an unpredictable complication occurring during the treatment, often as a result of procedural error or complex canal morphology. The effect of this mishap on periapical tissues depends on different factors such as pretreatment diagnosis or instrumentation phase during which separation occurred.

CASE PRESENTATION - Patient was referred to our department due to endodontic instrument separated in her lower right molar. Panoramic radiogram showed inadequate endodontic filling with 2-3 mm long fragment in the middle third of the mesial root and radiolucency around apical aspect of the same root (Fig. 1). Patient had no complaints and was without discomfort to palpation or sensitivity to percussion. After partial removal of old filling, in order to obtain a straight-line access to separated fragment coronal curvature of the mesio-buccal canal was softened using Gates-Glidden burs. Additional visibility was achieved using dental microscope magnification (40x) that enabled precise removal of dentin around coronal aspect of the fragment. The formed space enabled application of a specialized ultrasonic tip and transfer of vibrations to the side of separated instrument. These vibrations detached and successfully retrieved fractured file (Fig. 2) from the canal and that was confirmed by periapical radiogram (Fig. 3). Afterwards, old gutta-percha filling was removed using Gates–Glidden burs and reciprocating file system. Canals were irrigated with 1% sodium hypochlorite and 10% citric acid and instrumented using the same file system. Medication was placed for two weeks and during the next visit glass ionomer material was compacted against weakened distal wall of mesio-buccal canal and around hand file as a space keeper (Fig. 4). Canals were obturated using single cone technique and epoxy resin sealer. Post-obturation radiogram showed extrusion of the sealer over the apex of the mesial root (Fig. 5). At follow-up, 22 months later, patient was without symptoms and X-ray confirmed complete periapical healing (Fig. 6).



Fig. 1. Pre-operative radiogram



Fig. 2. Retrieved fragment



Fig. 3. Radiogram after fragment removal



Fig. 4. Repair of weakened canal wall



Fig. 5. Post-obturation radiogram



Fig. 6. Control radiogram after 22 months

DISCUSSION - In cases of infected endodontic space thorough cleaning and disinfection is a prerequisite for periapical lesion healing. As instrument separated in root canal affects instrumentation and irrigation, complete fragment retrieval is the most desirable solution.

CLINICAL RELEVANCE - Although, the removal of a separated file in some cases is connected with damaging of root dentin due to the need for adequate access it is often more conservative in comparison to surgical procedures. Retrieval requires significant clinical experience and specialized equipment but it should be the first option in treatment planning of these complications.

REFERENCES

Terauchi Y, Ali WT, Abielhassan MM (2022) Present status and future directions: Removal of fractured instruments. Int Endod J. 55(3), 685-709.

Yadav S, Nawal RR, Talwar S (2022) Nonsurgical Management of a Large Periapical Lesion Following Instrument Retrieval From the Apical Third: A Case Report With a Three-Year Follow-Up. Cureus. 14(5), e24995.

GE047 | REMOVAL OF ENDODONTIC FILE BROKEN IN TWO-CANAL MANDIBULAR INCISOR

Bojan Dželetović, Mirjana Nedeljković (presenting author), Svetlana Antić
School of Dental Medicine, University of Belgrade

AIM - To report a clinical case of broken endodontic file removal from the apex of mandibular incisor with two root canals.

INTRODUCTION - The endodontic file separation is one of the accidents that may occur during endodontic treatment and reduce the effectiveness of root canal cleaning. It compromises prognosis and favorable outcome, so removal would be ideal solution.



Fig. 1. Pre-operative radiogram



Fig. 2. Removed fragment



Fig. 3. Radiogram after file removal

CASE PRESENTATION - Patient was referred to our clinic for the removal of endodontic instrument fractured in the mandibular first incisor. Retroalveolar radiogram showed separated file segment, about 5 mm long, in the apical portion of the root canal (Fig. 1). Pulp chamber exploration showed presence of the second root canal and block in partially shaped first canal. Previously undiscovered canal was instrumented using reciprocating NiTi files and the septum between canals was removed using Gates–Glidden burs. Then, endodontic ultrasonic tip was used to loosen up and remove the broken file (Fig. 2). A radiogram confirmed complete fragment removal (Fig. 3). Endodontic space preparation was finished using balanced force hand instrumentation and irrigation of 1% sodium hypochlorite and 10% citric acid. The canal was dried, filled with calcium hydroxide and temporarily sealed. In the next visit, a week later, medicament dressing was removed and canal obturated using gutta-percha cones and epoxy-based endodontic sealer. Control radiogram was taken to assess the quality of root canal filling (Fig. 4). The patient was referred to prosthodontic department for the final prosthetic bridge restoration.



Fig. 4. Post-obturation radiogram

DISCUSSION - Removal of a broken instrument should be performed with minimal root canal wall damage but it is not always possible to preserve the original canal shape. In our case an anatomical variation created the possibility to approach the fragment with relatively little removal of the dentin walls.

CLINICAL RELEVANCE - Proper assessment and consideration of each case individually, taking into account anatomical features and specific circumstances, can lead to rational solutions without the use of additional sophisticated equipment. Clinical experience and simple armamentarium enable successful management of some hard clinical cases.

REFERENCES

1. Terauchi Y, Sexton C, Bakland LK, Bogen G (2021) Factors Affecting the Removal Time of Separated Instruments. J Endod, 47(8), 1245-1252.

2. Arslan H, Doğanay Yıldız E, Taş G, Akbıyık N, Topçuoğlu HS (2020) Duration of ultrasonic activation causing secondary fractures during the removal of the separated instruments with different tapers. Clin Oral Investig, 24(1), 351-355.

3. Coelho MS, Rios MA, Bueno CEDS (2018) Separation of Nickel-Titanium Rotary and Reciprocating Instruments: A Mini-Review of Clinical Studies. Open Dent J, 12, 864-872.

.

GE048 | REPAIR OF ROOT PERFORATION CAUSED BY CAST POST AND CORE

Bojan Dželetović, Jovan Badnjar (presenting author), Ljiljana Đukić
School of Dental Medicine, University of Belgrade

AIM - To present successful conservative therapy of root perforation caused by cast post and core in first mandibular molar.

INTRODUCTION - Inadequate preparation for intracanal posts can cause root perforation with consequent microorganism infiltration and destruction of surrounding tissues. Also, post removal can be challenging depending on the post/cement type and can lead to additional iatrogenic errors such as root fracture or excessive dentin removal.

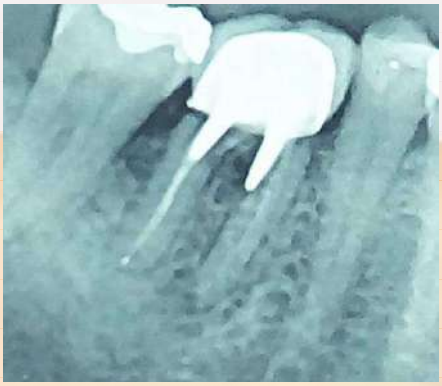

Fig. 1. Preoperative radiogram



Fig. 2. Perforation defect



Fig. 3. Calcium silicate material placement

CASE PRESENTATION - Patient was referred to our department for endodontic retreatment of mandibular right first molar with iatrogenic root perforation caused by inadequate preparation for cast post. Furcal and periapical lesions were incidental finding on panoramic radiogram but the patient was without sensitivity to percussion or palpation (Fig. 1). Treatment started by crown cutting and separation of mesial and distal parts of cast core using carbide burs. Cast posts were retrieved using an ultrasonic vibration under coolant irrigation with 15 seconds breaks to avoid significant rase of temperature. After post removal perforation defect and the destruction of adjacent tissues were clinically visible. Old canal filling was removed with the aid of Gates-Glidden drills and reciprocating file system. Working length was established with the use of an electronic apex locator and instrumentation done using reciprocating files. During shaping, canals were copiously irrigated with 1% sodium hypochlorite and smear layer removed with citric acid. Calcium hydroxide paste as a medicament was placed for two weeks. At the second visit, after removing intracanal dressing root canals were obturated with epoxy-based sealer and gutta-percha cone (Fig. 2). Afterwards perforation defect was sealed with calcium silicate-based material inserted by hand instrument and condensed using fat end of a paper point (Fig. 3). The quality of obturation and sealing material placement was checked by X-ray (Fig. 4). Control clinical examination, after four years and eight months, showed absence of any symptoms and radiography confirmed good outcome and lesions healing (Fig. 5).

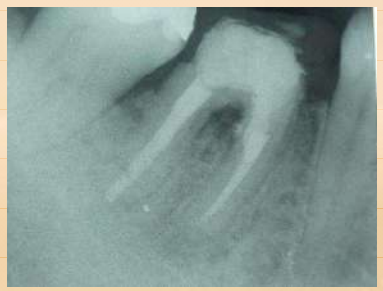

Fig. 4. Post-obturation radiography



Fig. 5 Control radiography after four years and eight months

DISCUSSION - There are many techniques used for post and core removal, like traction-based appliances or ultrasonic vibration. Ultrasonic vibration facilitates post removal by cement disruption and allows conservative and safe retrieval. Calcium silicate-based cements are materials of choice and desirable outcome can be achieved with simple armamentarium and careful clinical technique.

CLINICAL RELEVANCE - For root perforation therapy, elimination of microorganisms from the endodontic space is the most important factor for the healing of adjacent periodontal tissues. If the post removal is successfully achieved, favorable outcome is possible even in cases of neglected, large root perforations with persistent infection and surrounding tissues destruction.

REFERENCES

Garça IAA, Sponchiado Jùnior EC, Marques AAF, de Moura Martins L, Garrido ADB (2017) Assessment of a Cavity to Optimize Ultrasonic Efficiency to Remove Intraradicular Posts. J Endod. 43(8), 1350-3.

Kim JJ, Alapati S, Knoernschild KL, Jeong YH, Kim DG, Lee DJ (2017) Micro-Computed Tomography of Tooth Volume Changes Following Post Removal. J Prosthodont. 26(6), 522-528.

Clauder T (2022) Present status and future directions - Managing perforations. Int Endod J. 55(4), 872-891.

GE049 | RETRIEVAL OF SEPARATED INSTRUMENT EXTRUDED OVER THE APEX USING HAND FILES AND XP-ENDO FINISHER

Bojan Dželetović, Snežana Bošnjak (presenting author), Jelena Nešković
School of Dental Medicine, University of Belgrade

AIM - To report a case of combined use of hand and rotary files to remove endodontic instrument separated in root canal of upper lateral incisor.

INTRODUCTION - Separation of endodontic instrument in root canal compromises outcome and prognosis of treatment, thus removal would be ideal solution. The file fracture occurs when it binds against the root canal walls and continuous stress is applied to an already weakened instrument.



Fig. 1. Pre-operative radiogram



Fig. 2. Fragment displaced periapically and gutta-percha for odontometry

CASE PRESENTATION - Patient was referred to our department for retrieval of endodontic instrument separated in the upper lateral incisor. Radiogram showed inconsistent old canal filling with a fragment at its tip that might be a fractured endodontic instrument in the middle part of the root canal (Fig. 1). After previous endodontic filling was removed using Gates–Glidden burs and hand K-files, the block was found in the canal. Straight-line access to the fragment was improved and hand files were introduced between dentinal wall and broken instrument. The fragment was bypassed and partial instrumentation of the canal performed. Retrieval was tried by manipulating hand Hedström instrument along the fragment that was loosened up but displaced to the apex. New position of the fragment was revealed by radiography with inserted gutta-percha as electronic apex-locator showed periapical extrusion (Fig. 2). The separated fragment was finally grasped and removed using XP-endo Finisher (FKG Dentaire, Switzerland) in repetitive coronal traction motion (Fig. 3). A radiography confirmed complete removal (Fig. 4). Endodontic instrumentation was finished using reciprocating file system, irrigation with a 1% sodium hypochlorite and 10% citric acid. The canal was filled with calcium hydroxide and in the next visit, a week later, obturated using single gutta-percha cone technique and epoxy resin-based endodontic sealer. Radiogram was taken to assess the quality of root canal filling (Fig. 5).



Fig. 3. Removed fragment of the lentulo spiral



Fig. 4 Radiogram after file removal



Fig. 5. Post-obturation radiogram

DISCUSSION - Different techniques and devices developed for removal of fractured instruments have been described in the literature. Having in mind individual circumstances and features there could be more than one way to achieve clinical success.

CLINICAL RELEVANCE - Proper experience, relatively simple armamentarium and combination of appropriate techniques could enable successful management of separated files in a conservative, simple and low-cost approach.

REFERENCES

1. Y.Terauchi, WT Ali, MM Abielhassan (2022) Present status and future directions: Removal of fractured instruments. Int Endod J, 55, (3), 685-709.

2. Adl, A., Shahravan, A., Farshad, M. & Honar, S (2017) Success rate and time for bypassing the fractured segments of four NiTi rotary instruments. Iranian Endodontic Journal, 12, 349– 353.

3. Shen Y, Peng B, Cheung GS (2004) Factors associated with the removal of fractured NiTi instruments from root canal sys-tems. Oral Surg Oral Med Oral Pathol Oral Radiol Endod, 98(5), 605-10.

GE051 | EVALUATION OF THE DENTAL PULP STEM CELLS

G. KANDEMIR DEMIRCI [1]

[1] *Ege University Faculty of Dentistry, Izmir, TURKEY*

AIM: The purpose of the presentation is to evaluate and discuss dental pulp stem cells in terms of tissue regeneration and regenerative medicine applications.

Methodology: Dental tissues are a rich source of mesenchymal stem cells for tissue engineering applications. Five types of dental mesenchymal stem cells have been identified, including dental pulp, shed primary teeth, apical papilla, periodontal ligament, and dental follicle stem cells. These stem cells can differentiate into odontoblasts, neural progenitor cells, osteoblasts, chondrocytes, and fat cells. Therefore, it is thought that dental tissues have the potential to be used in tissue engineering applications such as regeneration of nerve and bone tissue. Stem cell biology and tissue engineering provide significant innovations in tissue regeneration applications in dentistry and in the development of clinical materials. Dental pulp is an important source of stem cells that has been recently emphasized and used in various stem cell researches. It has been shown that human dental pulp stem cells obtained from third molars can differentiate into odontoblasts, osteoblasts, fat cells, skeletal and smooth muscle cells, endothelial cells, cartilage cells and nerve cells. Current literature has reported that dental pulp stem cells have significant potential for use in clinical applications for the repair of dentin, periodontal tissue, bone cartilage tissues, immune system, muscle diseases and connective tissue damage.

Results: Dental pulp stem cell studies, which will offer tissue regeneration as a treatment option for dental practice by combining clinical dentistry and basic biology, especially target the formation of tissues such as dentin, pulp, cementum and periodontal ligament and thus the repair of damaged tissue.
. The high viability rates obtained by dissolving dental pulp stem cells obtained from healthy human teeth after cryopreservation have revealed that these cells can also be stored in sample storage banks for use when necessary.

GE052 | EVALUATION OF THE RETREATABILITY OF AH PLUS BIOCERAMIC SEALER WITH ULTRASONIC TIPS DURING ROOT CANAL RETREATMENT USING MICRO-COMPUTED TOMOGRAPHY

A. KIZILTAS GUL [1], S. MICOOGULLARI [1], M. KAVAL [1]

[1] *Ege University Faculty of Dentistry, Department of Endodontics, IZMIR, TURKEY*

AIM: The aim of this study is to evaluate the removability of root canal filling completed with AH Plus Bioceramic Sealer using different ultrasonic tips, compared with a resin-based root canal sealer (AH Plus Jet) using micro-computed tomography (micro-CT) imaging.

Methodology: In this study, the samples were divided into two groups (n=21). After root canal shaping, the root canal fillings were performed using AH Plus Bioceramic and AH Plus Jet. Post-obturation images were obtained using micro-CT scanning. Following this, retreatment was initiated, and root canal filling removal and reshaping were performed using R50 files. After reshaping, the samples were randomly assigned to 6 subgroups (n=7) based on the two-root canal filling materials. In the R50 group, no further procedure was applied after the R50 file. In the E5-ultrasonic and E4D-ultrasonic groups, E5 and E4D ultrasonic tips were used, respectively, following the R50 file. Then, the second micro-CT images were obtained from the samples to measure the volume of residual filling material in the root canal and statistical analyses were conducted. The results showed that the amount of remaining filling material in the AH Plus Bioceramic group is statistically significantly lower than in the AH Plus Jet group ($p=0.012$). A statistically significant difference was observed for both root canal systems between the R50 group-E5 ultrasonic group and the R50 group-E4D ultrasonic group ($p=0.0025$ and $p=0.0022$, respectively).

Results: • The AH Plus Bioceramic root canal sealer can be more effectively removed from the root canals compared to AH Plus Jet.
• In the present study, the results showed that ultrasonic tips are effective in reducing the amount of filling material during root canal retreatment.
• According to the results of this study, AH Plus Bioceramic root canal sealer can be effectively removed from the root canal when necessary.

GE053 | NON-SURGICAL RETREATMENT OF FAILED ROOT RESECTION: CLINICAL OUTCOME STUDIES

M. SOBOLIVSKA [1]

[1] *Symbiotyka Dental Clinic, Lviv, UKRAINE*

AIM: The treatment choice of failed apex resection is always a dilemma for the clinicians.
In this poster the potential of orthograde retreatment after unsuccessful teeth resection with the use of hydraulic calcium silicate cement is demonstrated.

Methodology: A study of Mario Dioguardi (Medicina, 2022) shows failures after surgical endodontic retreatments 10 years after treatment in the form of vertical root fractures (in 2 cases) and non-healing (in 7 cases). In all these cases, the apical part was filled with gutta percha.
Instead, another study of Azzaldeen Abdulgani (Journal of Dental and Medical Sciences · January 2016) shows a healing success rate of about 81% after MTa filling.
Teeth undergone apicoectomy with the presence of persistent apical periodontitis can be retreated with endodontic microsurgery or combination of non-surgical and surgical retreatment.
Despite the fact that the modern microsurgery has a high success rate, patients often reject any surgical procedures.
It is often impossible to perform apical surgery and non-surgical treatment may be the only method to save the tooth using the apexification technique.
Conclusion and Clinical Relevance
The use of hydraulic calcium silicate cements (MTA/Bioceramics) as an apical barrier in cases of orthograde retreatment after failed apicoectomy is a promising solution in microinvasive endodontics interventions.

Results: Teeth with previous failed apical resection are usually retreated surgically or with the combination of non-surgical and surgical retreatment. Alternatively, the non-surgical ortograde treatment of failed resection can be performed using the apical barrier technique used for apical closure with bioceramic putty. Bioceramic putty is a material of choice in such cases due to its excellent biocompatibility, sealing ability, osteoinductive and antibacterial properties.

GE055 | TREATMENT OF ROOT CANAL CALCIFICATION : A CASE REPORT

Research Assist. Elif YILDIZ*, Prof. Dr. Emre BODRUMLU*

*Department of Endodontics, Zonguldak Bülent Ecevit University Faculty of Dentistry, Zonguldak/TURKEY

AIM- The objective of this study is to present a treatment strategy involving of apical resection and retrograde obturation of a central tooth afflicted with periapical pathology, characterised by calcification in the coronal and middle triple region of the root canal. This condition is not amenable to treatment through the orthagrad approach. The utilisation of ultrasonic tips in this particular instance has been demonstrated to yield a more favourable prognosis in the management of periapical pathology [1].

INTRODUCTION- Teeth with pulp canal calcifications that require root canal treatment present particular diagnostic and therapeutic difficulties for clinicians. Cone Beam Computed Tomography (CBCT) is capable of visualising the root canal anatomy and detecting calcifications, thereby facilitating an accurate diagnosis. Orthograde root canal treatment complicates the management of teeth with periradicular lesions and root canal calcifications. The main reason for this is that root canal calcifications create dense mineral deposits and narrowing within the canal, hindering proper access to the root canal system. This makes it difficult to effectively clean the infected tissues and complicates the post-treatment healing process. Under these conditions, surgical alternatives such as retrograde root canal treatment can increase treatment success by providing direct access to the root apex and allowing for effective cleaning of the infected areas [2,3].

CASE PRESENTATION- A 22-year-old female patient with a healthy systemic profile presented at the endodontic clinic with sinus tract complaints. Following periapical radiography, a diagnosis of chronic apical abscess and pulp necrosis involving the right lateral and central teeth was made. It was determined that the root canal was calcified in the central tooth. CBCT imaging obtained from the patient showed calcification in the coronal and middle triple region of the root canal. The root canal was observed in the apical triple region (Fig. 1). The patient's lateral tooth exhibited a negative response to the electrical vitality test, thus indicating the necessity for orthograde root canal treatment, which was initiated under rubber dam isolation. The treatment plan involved the application of calcium hydroxide (Ca(OH)2) as a medication. The root canal treatment was completed after a duration of two weeks, as illustrated in (Fig. 2). The patient had a surgical procedure on the same day. The flap was then opened, and granulation tissue was removed. Following this, 3 mm root tip resection was performed on two teeth using burs. The third of the canal from the apex was cleansed using ultrasonic tips from the end that had been resected, and the retrograde cavity was prepared. Retrograde obturation was achieved using MTA (Bio MTA, Cerkamed). In the central tooth, retrograde filling was performed up to the calcified mass of the root canal (Figures 2 and 3). The patient was recalled after one week for suture removal. At the 5-month follow-up, no objective or subjective symptoms were detected during the clinical examination. Furthermore, radiographic analysis demonstrated a reduction in the radiolucent area. (Fig.4).

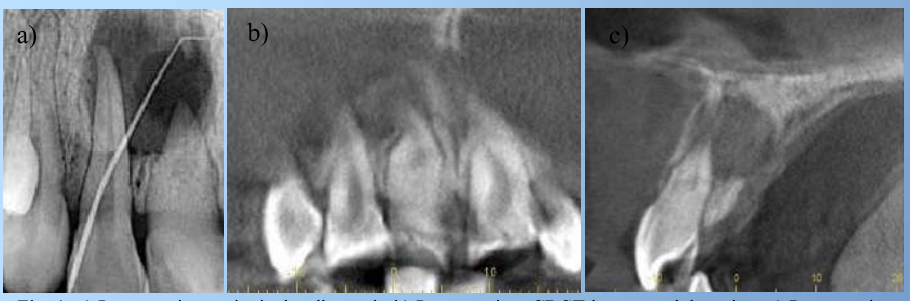

Fig. 1: a) Preoperative periapical radiograph, b) Preoperative CBCT images axial section, c) Preoperative CBCT sagital section

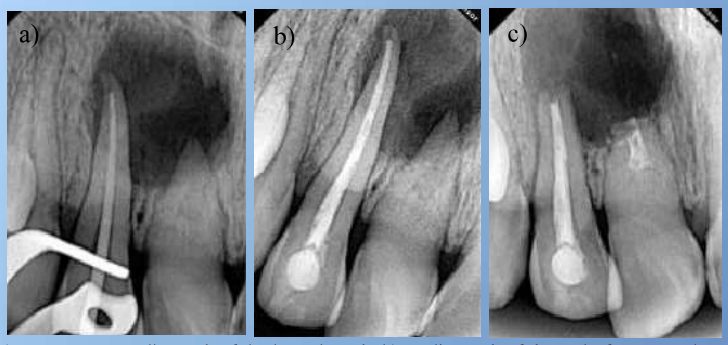

Fig. 2: a) Master cone radiograph of the lateral tooth, b) Radiograph of the end of root canal treatment of the lateral tooth, c) Control radiograph after surgery and obturation of retrograde cavities with MTA

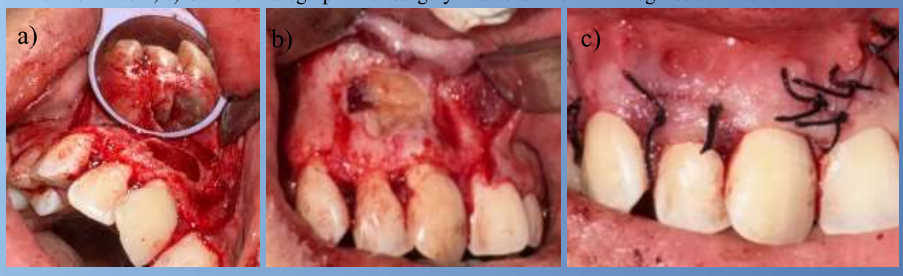

Fig. 3: a) Surgical operation and retrograde obturation with MTA, b) PRF placement at the surgical site, c) Closure of flap

DISCUSSION- The effectiveness of endodontic therapy is dependent on effective disinfection and obturation of the root canal system. This process can be difficult in cases where the pulpal cavity is calcified. The formation of mineral deposits within the root canal and the narrowing of the canal system make access to treatment more difficult. Although orthograde root canal therapy aims to clean the canal system and remove infected tissues, the inability to fully access the canal due to calcifications complicates the success of the treatment. In cases where calcifications and periapical lesions are detected in the coronal and middle thirds of the root canal through advanced radiological analysis, and when it is not possible to clean and fill the root canal orthogradely, alternative endodontic surgical methods are applied [4].

In a similar case reported by Moura et al.[5], a retrograde filling was placed via apical surgery as an alternative to conventional endodontic treatment. The use of ultrasonic devices in endodontic treatment provides a safer opportunity. For this reason, various ultrasonic tips have been designed to perform the grooving required to locate and enter calcified pulp chambers and canals and to prepare the retro cavity. Chaniotis and Zapata[6] found that ultrasonic tips made cleaner and deeper root tip cavity preparations, abraded dentin less, helped retain root tip filling material, and provided disinfection by removing infected dentin. In this case, ultrasonic retro tips were utilised. Biocompatible and leak-proof filling of the created retro cavity is of great importance for clinical success. MTA, a calcium silicate-based material, has been demonstrated to exhibit high bioactivity and biocompatibility, making it a suitable material for use as a canal filling material and root tip filling material, was selected obturation.

CONCLUSION- Retrograde root canal obturation is a reliable alternative for calcified teeth with limited orthograde access to root canals.



Fig.4: 5-months follow-up periapical radiography

REFERENCES-

1. Rodrigues V, Scamardi I, Schacht Junior CF, Bortolotto M, Manhaes Junior LR, Tomazinho LF, Boschini S. Prevalence of pulp stones in cone beam computed tomography. Dent Press Endod. 2014;4:57-62.
2. Satheeshkumar PS, Mohan MP, Sweta S, Sudheesh S, George G. "Idiopathic dental pulp calcifications in a tertiary care setting in South India". J Conserv Dent. 2003;16: 50-55.
3. Jonasson P, Lennholm C, Kvist T. Retrograde root canal treatment: a prospective case series. Int End J. 2017;50(6), 515-521.
4. Pietrzycka K, Pawlicka H. Clinical aspects of pulp stones: A case report series. Dent Med Probl. 2020;5:213-220.
5. Moura LB, Velasques BD, Silveira LFM, Martos J, Xavier CB.Therapeutic approach to pulp canal calcification as sequelae of dental avulsion. Eur Endod J. 2017; 2(1), 1-5.
6. Chaniotis A, Ordinola Zapata R. Present status and future directions: Management of curved and calcified root canals. Int Endod J. 2022;*55*:656-684.

GE057 | NON-SURGICAL ENDODONTIC TREATMENT OF AN EXTRAORAL FISTULA OF ODONTOGENIC ORIGIN

A. DOGAN [1], MUGEM ASLI EKICI[2]

[1] *Gazi University, Ankara, TURKEY*
[2] *Department of Endodontics, Faculty of Dentistry, Gazi University, Ankara, TURKEY*

AIM: This case report highlights the importance of the endodontic approach in treating extraoral fistulas and complex endodontic cases.

Methodology: A 40-year-old female patient was referred to the clinic with complaints of ulcerative tissue, swelling and pain in the right lower jaw. Extraoral examination revealed an extraoral fistula at the inferior border of the mandible. Intraoral examination showed swelling in the buccal mucosa at the teeth region 35 and 36. Tooth 36 was tender on percussion. It was learned that tooth 35 had previously undergone root canal treatment, and the root canal filling had been exposed to the oral environment for a long time. A comprehensive medical history revealed no systemic diseases. Under a rubber dam isolation, the root canals of tooth 36 were prepared using ProTaper files from Sx to F2 and S to F3, respectively. Concurrently, retreatment was initiated for tooth 35. Root canal filling materials were removed using H-type files. The root canal was prepared up to a #50 K file with a step-back technique. The canals were irrigated %2,5 NaOCl - %17 EDTA, and activated using a sonic system. Calcium hydroxide was used as the intracanal medicament. The patient was scheduled for weekly appointments over three months. After three months, intraoral swelling and symptoms had fully resolved. The root canals were obturated with appropriate gutta-percha cones and resin-based root canal sealer. At the 6-month follow-up, the extraoral fistula was completely closed with significant healing and the teeth remained asymptomatic.

Results: 1. A careful intraoral and extraoral examinations are necessary for an extraoral fistula.
2. Prolonged exposure of the canal opening can lead to complications such as infection.
3. Sonic activation of irrigation solutions is effective in cleaning infected canals.
4. Calcium hydroxide plays an important role in the healing process of infected canals.
5. Regular follow-up and control sessions are essential in treatment.

GE058 | NON-TRAUMATIC TOOTH CRACKS AND FRACTURES – CASE REPORT AND EXISTING GUIDELINES FOR DIAGNOSTIC AND THERAPEUTIC PROCEDURES

Ida Mihalj, DMD, Specialist in Endodontics and Restorative Dentistry

Dental Clinic Zagreb, Croatia

AIM: The purpose of this poster is to present a case report of a cracked tooth from clinical practice and provide a systematic overview of existing guidelines for diagnostic and therapeutic procedures in the case of tooth cracks.

INTRODUCTION: Tooth fractures are the third most common cause of tooth loss, after caries and periodontal diseases. They are becoming more common due to modern lifestyle factors. If unrecognized, they can progress and invade the dental pulp, causing pathological changes. However, recent research shows that such teeth can have a good prognosis with appropriate therapy and timely placement of suitable restorations.

CASE PRESENTATION: A 62-year-old patient was referred to the Department of Endodontics for an opinion related to tooth 15. The patient experienced pain after biting into a stone in rice, which led to difficulty chewing on the right side. Clinical examination revealed a crack on the distal half of the occlusal surface of tooth 15. The tooth had no carious lesions or previous restorations. Minimally invasive therapeutic procedures were performed to stabilize the crack and prevent its progression. The patient reported no pain during a follow-up visit, and a recall is planned after six months.



Figure 1: clinically visible crack, transillumination, final restoration

DISCUSSION: Cracks and fractures affect both restored and intact teeth, primarily in adults aged 30 to 60. Lower molars and upper premolars and molars are most commonly affected. The etiology is multifactorial, and understanding risk factors is crucial for prevention and early intervention. Diagnostic and therapeutic procedures should be tailored to preserve tooth vitality and prevent crack progression.

CLINICAL RELEVANCE: Cracks and fractures are increasingly common in dental practice. They can remain asymptomatic for a long time, making diagnosis challenging. Early diagnosis and appropriate therapy are essential for tooth survival. Minimally invasive procedures, such as direct composite splints, are recommended to preserve hard tissue and maintain pulp vitality.

REFERENCES:
Banerji S, Mehta SB, Millar BJ. The management of cracked tooth syndrome in dental practice. Br Dent J. 2017 May 12;222(9):659–66.
Davis MC, Shariff SS. Success and Survival of Endodontically Treated Cracked Teeth with Radicular Extensions: A 2- to 4-year Prospective Cohort. J Endod. 2019 Jul;45(7):848–55.
Ricucci D, Siqueira JF, Loghin S, Berman LH. The cracked tooth: histopathologic and histobacteriologic aspects. J Endod. 2015 Mar;41(3):343–52.

GE060 | MANAGING POOR PROGNOSIS TEETH IN ONCOLOGY PATIENTS – HIGHLIGHTING THE BENEFITS OF ENDODONTIC TREATMENT TO MINIMISE THE RISKS OF OSTEORADIONECROSIS

M. DUQUE VASQUEZ [1], R. Virdi [1], P. Wilson [1]

[1] *John Radcliffe, Oxford university Hospital, Oxford, UNITED KINGDOM*

AIM: This presentation highlights the challenges faced by this vulnerable patient population and demonstrates how endodontic management can help enhance their treatment outcomes. There is a pressing need for further research and collaboration among dental and maxillofacial colleagues to support patients with head and neck oncology.

Methodology: The John Radcliffe Hospital in Oxford serves as a tertiary centre for the management of patients with head and neck oncology, supported by a multidisciplinary team that includes Oral and Maxillofacial Surgery (OMFS) and Restorative Dentistry.

A comprehensive assessment prior to the initiation of radiotherapy or other oncological treatments is important to minimise the impact on oral health including xerostomia, increased caries rates, trismus, and osteoradionecrosis (ORN).

Despite the complications of trismus, prolonged treatment duration, the impact of impaired vascularity on apical healing within irradiated jaws, Endodontic treatments have proven effective for patients with a history of radiotherapy.

There have been favourable results in patients with active ORN with evidence of periapical bone loss around vital teeth that have necessitated endodontic management. The objective in these cases would include preservation of the affected teeth by addressing, ensure patient comfort where possible by addressing the endodontic symptoms and allow these to naturally exfoliate which have lower incidences of ORN when compared with dental extractions.

Results: Endodontic Treatment should be considered more routinely on patients at high risk of ORN

To Provide a brief outline of the patient journey undergoing radiotherapy and the impact on ORN.

Allowing the tooth to exfoliate helps to minimise ORN and its associated risks.

Limited literature shows promising results.

Suggestions on how to navigate this cohort.

GENERAL ENDODONTIC POSTERS 02

GE061 | MANAGEMENT OF A ALVEOLAR LATERAL LUXATION WITH A CONCURRENT NON-COMPLICATED CROWN FRACTURE IN A MAXILLARY CENTRAL INCISOR.

E. AGUILAR MACIEL [1], M. TEULÉ TRULL [1]

[1] *Universitat Internacional de Catalunya, Barcelona, SPAIN*

AIM: To describe the clinical management of a 38-year-old female patient with alveolar lateral luxation and an alveolar fracture involving maxillary incisors. This case follows the International Association of Dental Traumatology (IADT) guidelines and highlights the importance of early intervention, splinting, root canal treatment (RCT), and long-term follow-up to promote periodontal and alveolar healing while preventing complications

Methodology: A traumatic dental injury resulted in the lateral luxation of tooth 11, a non-complicated crown fracture of the same tooth, and an alveolar fracture involving teeth 21 and 22. Clinical and radiographic assessments confirmed displacement and alveolar fracture. Immediate stabilization using a flexible splint for four weeks was performed to promote periodontal and bone healing. Given the high risk of pulp necrosis in mature teeth, RCT was performed for teeth 11, 21, and 22. The patient underwent regular clinical and radiographic follow-ups over six months. At the final evaluation, the treated teeth demonstrated periodontal stability, absence of infection or external root resorption, and radiographic evidence of bone healing. This case reinforces literature findings that mature permanent teeth are more susceptible to pulp necrosis post-luxation compared to younger teeth with greater revascularization potential

Results: Early Intervention and Stabilization – Immediate splinting of luxated teeth is crucial for optimal healing and stability.
2. High Risk of Pulp Necrosis in Mature Teeth – Unlike younger teeth, mature teeth have a limited capacity for revascularization, increasing the likelihood of pulp necrosis.
3. Evidence-Based Treatment – Adhering to IADT protocols ensures the best clinical outcomes in traumatic dental injuries.
4. Long-Term Follow-Up is Essential – Regular monitoring helps detect complications like infection or root resorption.
5. Multidisciplinary Management – Coordinated care between endodontics, periodontics, and restorative dentistry is key for functional and aesthetic rehabilitation

GE062 | RETREATMENT: A VICTORY

H. BUCH [1]

[1] *Sanjivani Centre Of Advanced Implant And Microscopic Dentistry, Rajkot, INDIA*

AIM: RETREATMENT of a failing root canal treatment is a challenging treatment for any endodontist, but with the help of dental operating microscope ,ultrasonics and proper rubber dam isolation this treatment can be having predictable success rate. This case report aims to show the treatment steps for retreatment with retrieval of broken files and follow up of 10 years. Retreatment is a victory in itself.

Methodology: This case report shows the steps of retreatment of failing root canal treatment with negotiation of missed canals and broken instrument retrievals with the help of dental microscope and ultrasonics

Results: 1. Retreatment steps
2. Ultrasonic file retrieval
3. Minimal invasive technique
4. Missed canal negotiation

GE063 | MULTIDISCIPLINARY APPROACH IN LATERAL LUXATION AND HORIZONTAL ROOT FRACTURE: A CASE REPORT

Gizem Pelin YOLDAŞ[1] ,Tülin Doğan ÇANKAYA[1]

[1] *Alanya Alaaddin Keykubat University, Faculty of Dentistry, Department of Endodontics*

Aim: The aim of this study is to present the successful treatment process of a tooth with lateral luxation and horizontal root fracture using a multidisciplinary approach, contributing to clinical management strategies for similar cases.

İntroduction: Dental trauma, especially complicated injuries like lateral luxation and horizontal root fractures, are emergencies that require early and accurate intervention. These types of trauma can lead to functional and aesthetic losses by affecting the periodontal ligament, pulp, and surrounding bone tissue. A multidisciplinary approach plays a critical role in ensuring the long-term survival of the tooth by evaluating both conservative and surgical treatment options.

Case Presentation: A 42-year-old male patient presented to our clinic 15 days after a traffic accident, reporting displacement of his teeth. Clinical and radiographic (CBCT and periapical radiography) examination revealed concussion in teeth 11 and 12, a horizontal root fracture in the middle third of tooth 21, and lateral luxation of tooth 22. On clinical examination, no pain was observed upon palpation or percussion. Vitality test confirmed TEŞHİS EDİLDİ YAZALIM that teeth 12, 11, and 22 were vital, while tooth 21 was non-vital with mobility and 2 mm pocket depth. Tooth 22 was surgically repositioned, and tooth 21 was repositioned using finger pressure. Following repositioning, a non-rigid fiber splint was applied between teeth 23 and 13. In the first session, after extirpation of tooth 21, calcium hydroxide was placed as an intracanal medication. In the second session, the coronal part of the fractured root was filled with bioceramics and gutta percha, and composite resin restoration was applied. After a 4-week follow-up, the splint was removed. Due to the loss of vitality in tooth 22, root canal therapy was initiated. Tooth 22 was filled with resin-based root canal sealer and gutta-percha. HASTAYA TAKİP RANDEVUS VERİLDİ. The patient was placed under follow-up care.

Discussion: The treatment of lateral luxation and horizontal root fractures requires repositioning of the tooth, appropriate splinting for a suitable period, and conservative or endodontic treatment depending on the level of the root fracture. The success after root fractures depends on the degree of pulp damage. If the pulp is necrotic, root canal therapy is necessary for repair. This case demonstrates that a multidisciplinary approach and early intervention can lead to successful outcomes.

Clinical Relevance: This case demonstrates the critical role of timely and accurate treatment of lateral luxation and horizontal root fractures through a multidisciplinary approach in maintaining the long- term functional and aesthetic success of the tooth. Factors such as vitality, fracture location, and mobility are crucial in determining the treatment for horizontal root fractures. Despite a poor prognosis, it is essential to regularly monitor the symptoms and the condition of the tooth to preserve it for as long as possible.

1.Hovland EJ. Horizontal root fractures: treatment and repair. Dental Clinics of North America. 1992;36(2):509-25.

GE065 | MANAGEMENT OF LARGE ENDODONTIC- PERIODONTAL LESION ON TOOTH WITH NECROTIC PULP

Dt.Betül Göl[1], Assoc. Prof. Dr. Gözde Kandemir Demirci[1]

[1]Ege University, Faculty of Dentistry, Department of Endodontics, İzmir, Turkey.

AIM

The aim of this case report was to evaluate the efficacy of completing orthograde root canal treatment following calcium hydroxide medication in a tooth with necrotic pulp with an extensive endo-perio lesion .

INTRODUCTION:

Pulpal disease and bacterial invasion within the pulp space can lead to the development of periapical lesions.[1] Endodontic-periodontal disease involves pathological conditions affecting both the pulp and periodontal tissues of a tooth. Inadequate treatment of these lesions and failure to achieve complete disinfection and sealing of the root canal may allow residual bacteria to persist, potentially leading to further endodontic-periodontal complications or reinfection.[2] The primary objective of endodontic treatment should be to restore the affected tooth to a healthy and functional state without the need for surgical intervention.[1]

CASE PRESENTATION:

A 13-year-old female patient was referred to our endodontic clinic with a lesion on mandibuar first molar tooth that was noticed during routine radiologic examination. While the tooth was not sensitive to percussion and palpation tests, a negative response was obtained to the electric pulp test (Fig.1). In the first session, under rubber dam isolation, the canals were instrumented using a reciprocating file system. Following the completion of biomechanical preparation, the canals were irrigated with 2.5% sodium hypochlorite (NaOCl) and 17% ethylenediaminetetraacetic acid(EDTA) solutions. Intermittent passive ultrasonic irrigation (PUI) was then performed using an Endo 3 ultrasonic device (WOODPECKER, China). Subsequently, calcium hydroxide was applied as an intracanal medicament, and a temporary restoration was placed using zinc oxide eugenol cement.The patient underwent subgingival curettage and received oral hygiene instruction. After two weeks of calcium hydroxide treatment, the final irrigation in the second session was performed under rubber dam isolation using 5 mL of 17% EDTA, 5 mL of 2.5% NaOCl, 5 mL of distilled water, and 5 mL of 2% chlorhexidine. The mesial canals were obturated using the single-cone gutta-percha technique, while the distal canal was filled using cold lateral compaction technique with an epoxy resin-based endodontic sealer. (Fig .2) In the follow-up examination after five months later, a peripaical digital x-ray was taken and it was revealed that the periapical lesion was healing. (Fig. 3) and the clinical examination showed the absence of symptoms within a short follow-up period.



Figure1 : Preoperative radiography



Figure 2: Postoperative radiography

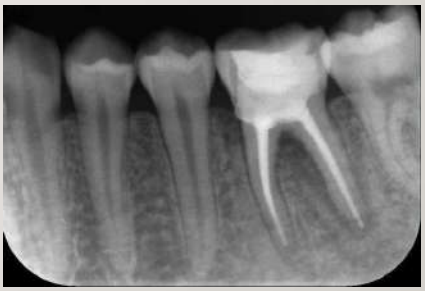

Figure 3: Follow-up radiography

DISCUSSION:

Teeth with endodontic-periodontal lesions have a necrotic, infected root canal system along with a periodontal defect due to the close relationship between the pulp and periodontium. In combined lesions, simultaneous treatment of both tissues is recommended to create the optimal environment for healing and success.

CLINICAL RELEVANCE :

Endodontic-periodontal lesions require a comprehensive approach to achieve optimal healing. Proper endodontic treatment, including thorough irrigation and effective intracanal medication, is essential for preventing reinfection and promoting healing of both pulpal and periodontal tissues. This case highlights the importance of simultaneous management of both tissues, as well as the role of calcium hydroxide and proper obturation techniques in achieving favorable outcomes in combined lesions.

REFERENCES:

1. Moshari A, Vatanpour M, Esna Ashari E, Zakershahrak M, Ara AJ. Nonsurgical management of an extensive endodontic periapical lesion: A case report. *Iran Endod* 2017;12(1):116-119.
2. Alshawwa H, Wang JF, Liu M, Sun SF. Successful management of a tooth with endodontic-periodontal lesion: A case report. *World J Clin Cases*. 2020;8(20):5049-5056.
3. Al-Fouzan KS. A new classification of endodontic-periodontal lesions. *Int J Dent*. 2014;2014.

GE067 | DIAGNOSIS OF TRIGEMINAL NEURALGIA: A CASE REPORT

E. ÇAKILKAYA [1], D. BILGILI [2], S. ALPAY [3]

[1] *ISTANBUL AYDIN UNIVERSITY DENTISTRY FACULTY ENDODONTIC DEPARTMENT, ISTANBUL, TURKEY*
[2] *ISTANBUL AYDIN UNIVERSITY DENTISTRY FACULTY ENDODONTIC DEPARTMENT, ISTANBUL, TURKEY*
[3] *ISTANBUL AYDIN UNIVERSITY DENTISTRY FACULTY ENDODONTIC DEPARTMENT, ISTANBUL, TURKEY*

AIM: The aim of this case report is to highlight the diagnostic challenges of trigeminal neuralgia (TN) and emphasize the importance of distinguishing it from odontogenic pain to prevent misdiagnosis and unnecessary dental interventions.

Methodology: Trigeminal neuralgia (TN) is a chronic neuropathic pain disorder characterized by sudden, severe, unilateral facial pain, often triggered by speaking, chewing, or touching the affected area. It primarily affects mandibular (V3) branch of the trigeminal nerve. Due to its similarity to odontogenic pain, TN is frequently misdiagnosed, leading to unnecessary dental treatments.
This case report describes a 51-year-old female with sharp, intermittent, electric shock-like pain localized to the right lower facial region. The pain was exacerbated by mastication and speech, with no relief from common analgesics. Clinical and radiographic examinations revealed no dental pathology, temporomandibular joint disorders, or sinus-related issues. The percussion test was negative, and no caries were present. The patient was initially referred to an otolaryngologist due to ear-related symptoms, but no diagnosis was made. Given the episodic nature and trigger-associated pain, a neurology consultation confirmed TN affecting the mandibular branch (V3).
Carbamazepine was prescribed as first-line treatment, leading to significant symptom relief. Management included patient education on trigger avoidance and periodic follow-ups. If symptoms persist and there is no response to medical treatment, a surgical operation will be considered.
This case underscores the importance of differentiating TN from dental pain to prevent unnecessary interventions. Clinicians should consider TN in patients with recurrent, severe unilateral facial pain without dental pathology, ensuring timely diagnosis and appropriate management.

Results: • Trigeminal neuralgia should be considered in cases where there is no odontogenic pathology especially in the lower jaw.
• In cases suspected of trigeminal neuralgia, a neurology consultation should always be considered.
• The diagnosis of trigeminal neuralgia is important because it prevents unnecessary dental procedures.

GE068 | MECHANICAL FILES WITH SMALL APICAL SIZE AND TAPER

D. JOFFE-SOKOLOVA [1]

[1] *Universitat Internacional de Catalunya (UIC), Barcelona, SPAIN*

AIM: The aim of the presentation is to focus on mechanical files with small apical size and taper. In the minimally invasive time of today, the industry is producing mechanical files with a final size of 25/.04. What do we know about such files, and what are the indications to use them?

Methodology: The presentation will start with a case presentation of a 66-year-old female with acute pain and ASA 3 because of prolonged bisphosphonate usage. Teeth 15 and 16 were in a bridge construction with cantilever on the place of tooth 14. Tooth 16 was endodontically treated and had apicectomy several years earlier.The clinical tests and periapical x-rays were not conclusive, and CBCT was taken. It revealed apical radiolucency of tooth 15 and the mesial root of tooth 16. Tooth 15 had 2 separate roots and thin root walls. Root canal treatment was started through the bridge in tooth 15, and selective retreatment was done in the mesial root of tooth 16. Because of the thin walls of tooth 15 and that cantilever construction, small taper files were chosen for the preparation. The final file was Slim Shaper from Zarc in size 25/.04. The final irrigation was performed with plastic tips 2 mm from the working length using NaOCl 3%, EDTA 17%, and sonic activation. The obturation was performed with bioceramic sealer and a single cone in tooth 15 and MTA in the mesial root of tooth 16. Evaluation after 10 months revealed successful healing of both teeth.
The presentation will further focus on the literature for mechanical preparation, in particular the apical sizes and taper of the files. The advantages and disadvantages of files with smaller size and taper will be discussed, as well as the indications for usage.

Results: Apical size and taper by apical periodontitis
Zarc Slim Shaper files

GE069 | Apical Barrier Formation with Mineral Trioxide Aggregate in a Retreatment Case

Burak YILMAZ[1], Ayşe Nur KUŞUÇAR[2], Ahmet Demirhan UYGUN[3]
Departmant of Endodotics Faculty of Dentistry, Afyonkarahisar Health Science University

Aim - This case report aims to present the management of a root canal-treated tooth with apical periodontitis, along with the obtained clinical and radiographic outcomes.

Introduction - In retreatment cases, apical constriction may be compromised, and the anatomical structure may be disrupted during the removal of the previous root canal filling. This can result in inadequate compaction of gutta-percha at the apical region and the absence of a *tug-back* sensation. Therefore, mineral trioxide aggregate (MTA) (PD MTA White, Produits Dentaires, Vevey, Switzerland) was chosen to create an apical barrier due to its biocompatibility.



Case Report - A 37-year-old male patient presented to the Department of Endodontics, Faculty of Dentistry, Afyonkarahisar Health Sciences University, due to the failure of a previous root canal treatment on tooth #12. Clinical and radiographic evaluations revealed the presence of apical periodontitis, and retreatment was planned.

The previous root canal filling was removed using a NiTi retreatment rotary system, and the working length was determined as 22 mm with a #50 K-file under radiographic guidance. The canal was irrigated with 2.5% sodium hypochlorite after each file change and was enlarged up to a #80 K-file. After ensuring adequate cleaning and disinfection, calcium hydroxide was applied as an intracanal medicament.

Two weeks later, the canal was irrigated with 2.5% sodium hypochlorite and saline solution, followed by drying. A 4 mm thick layer of MTA was placed in the apical region, and its placement was confirmed with a periapical radiograph. To maintain moisture for MTA setting, a saline-moistened cotton pellet was placed, and a temporary restoration was applied. The following day, the canal was obturated using the cold lateral condensation technique. At the six-month follow-up, the tooth remained asymptomatic, and radiographic evaluation showed healing of the periapical lesion.



a-) Initial Periapical Radiograph



b-) Working Length Determination Radiograph



c-) MTA Verification Radiograph



d-) Final Radiogarph



e-) Six-Month Follow-Up Radiograph

Discussion

Traditional apexification relies on long-term calcium hydroxide application to induce the formation of a calcified barrier. Although it is a predictable method, it has disadvantages such as requiring multiple visits and increasing the risk of cervical fracture (1,2). As an alternative, artificial apical barriers have been proposed, with mineral trioxide aggregate (MTA) being particularly preferred due to its biocompatibility and superior sealing properties (3,4). Published reports suggest that in cases of pulp necrosis with open apices, MTA supports the maintenance of normal periradicular architecture, promotes continued root maturation, and functions as an effective sealing material (5-7).

Clinical Relevance – This approach provides a reliable option for managing teeth with compromised apical narrowing, facilitating apical barrier formation and promoting periapical healing.

1. Andreasen, J.O., Farik, B. & Munksgaard, E.C. (2002) Long-term calciumhydroxide as a root canal dressing may increase risk of rootfracture. *Dental Traumatology*,18(3),134–137.

2. Sahebi, S., Moazami, F. & Abbott, P. (2010) The effects of short-termcalcium hydroxide application on the strength of dentine. *Dental Traumatology*,26(1),43–46.

3. Mitchell, P.J., Pitt Ford, T.R., Torabinejad, M. & McDonald, F. (1999) Osteoblast biocompatibility of mineral trioxide aggregate. *Biomaterials*,20(2),167–173.

4. Al-Kahtani, A., Shostad, S., Schifferle, R., & Bhambhani, S. (2005) In-vitro evaluation of microleakage of an orthograde apical plug of mineral trioxide aggregate in permanent teeth with simulated immature apices. *Journal of Endodontics*, *31*(2), 117-119.

5. Holden, D. T., Schwartz, S. A., Kirkpatrick, T. C., & Schindler, W. G. (2008) Clinical outcomes of artificial root-end barriers with mineral trioxide aggregate in teeth with immature apices. *Journal of Endodontics*, *34*(7), 812-817.

6. Cehreli, Z. C., Sara, S., Uysal, S., & Turgut, M. D. (2011) MTA apical plugs in the treatment of traumatized immature teeth with large periapical lesions. *Dental Traumatology*, *27*(1), 59-62.

7. Aricioglu, B., Gunacar, D. N., Kosar, T., Sanal Cikman, A., Pertek Hatipoglu, F., & Maras, E. (2022) Assessment of bone quality of apical periodontitis treated with MTA plug and regenerative endodontic techniques. *Australian Endodontic Journal*, *48*(3), 444-450.

GE071 | REGENERATIVE TREATMENT WITH PRF FOR TEETH WITH IMMATURE APEXES AND PERIAPICAL LESIONS

H.T. YILDIZ [1], I. KAYA BUYUKBAYRAM [1]

[1] *Istanbul Aydin University Faculty Of Dentistry Department Of Endodontic, Istanbul, Turkey*

AIM: The objective of this study is to present the clinical and radiological follow-up of two cases that underwent regenerative endodontic treatment using platelet-rich fibrin (PRF).

Methodology: Two systemically healthy male patients were referred to the Department of Endodontics at Istanbul Aydin University, Faculty of Dentistry. Clinical and radiological examinations, including cone beam computed tomography (CBCT), were performed.
A 16-year-old patient presented with an immature apex, crown fracture, and a periapical lesion in tooth #21 due to trauma that had occurred 8 years prior.
A 25-year-old patient exhibited an immature apex, palatal swelling, and a periapical lesion in tooth #22 following trauma that had occurred 15 years prior.
Following disinfection with triple antibiotic paste, PRF was placed in the root canals before sealing the apexes with mineral trioxide aggregate (MTA). Rubber dam isolation was utilized during all visits.
Patients were scheduled for follow-up at 1, 3, 6, and 12 months. CBCT scans were performed at 6 and 12 months to assess changes in lesion volume and apex maturation.
Both cases demonstrated a reduction in periapical lesion size over time. Radiographic evaluation revealed hard tissue formation at the apex of the immature teeth, indicating successful regeneration.
PRF, in conjunction with regenerative endodontic protocols, demonstrated promising outcomes in the management of teeth with immature apices and periapical lesions. The use of CBCT allowed for precise evaluation of the healing process. Further studies with larger sample sizes are warranted to validate these findings.

Results: Platelet-rich fibrin, Regenerative endodontics, Triple antibiotic paste, CBCT, Immature apex.

GE072 | TREATMENT OF A MOLAR TOOTH WITH INTERNAL ROOT RESORPTION AND VERTICAL ROOT FRACTURE: A CASE REPORT

Zeynep Kacmaz DDS, Sevinç Aktemur Türker DDS,PhD,MSc
*Department of Endodontics, Faculty of Dentistry, Zonguldak Bülent Ecevit University, Zonguldak, Turkey

AIM

The aims of this case report are to present the endodontic treatment of a molar tooth with a non-perforating internal root resorption (IRR) associated with chronic apical periodontitis and the hemisection procedure after the occurance of vertical root fracture in the mesial root six months after the conclusion of the treatment.

INTRODUCTION

Internal root resorption is a form of root resorption which breaks down hard tissues of root canal walls as a result of a clastic activity. The irregular areas of internal root resorption make it difficult to properly prepare and fill the root canals during root canal treatment. After removal of the inflamed pulpal and granulation tissue, a hermetic obturation of the resorption cavity is essential in the treatment of internal root resorption cases (Lyroudia et al.).

Vertical root fractures (VRF) in endodontically treated teeth have been a subject of interest for some time and pose significant diagnostic challenges. A hemisection/root resection procedure is a definitive treatment option that removes the fractured fragments completely and retains a portion of the compromised tooth, offering a predictable outcome (Anitha et al., 2015).

This report demonstrates an alternative treatment to extraction of a whole tooth and salvation of healthy tooth structure in a patient who was unwilling for extraction.

CASE PRESENTATION

A 48-year-old male patient was admitted to Zonguldak Bülent Ecevit University Faculty of Dentistry for a routine check-up. The patient did not have any systemic diseases. A panoramic radiograph was taken, which demonstrated internal root resorption in tooth 36 (Figure 1). The tooth was asymptomatic. No erythema, swelling or sinus tract was detected. In the coronal third of the root, an internal root resorption was seen. On the radiograph, we could not find out if there is a perforation or not. For a precise diagnosis and a proper management of root canal treatment, it was mandatory to exclude the presence of a root perforation. In that respect, a CBCT examination (Morita, Japan) was recommended (Figures 2,3,4). The analysis of the transverse (Figure 4) and axial (Figure 2) slices showed no perforation of the canal walls. The patient underwent a root canal treatment, for which an infiltrative anaesthesia (Ultracaine DS Forte; Aventis, Turkiye) was administered. The access cavity was opened under rubber dam isolation.

The present study investigated the use of EndoArt Smart Gold files (Incidental, Turkiye) to expand root canals to a size of 30.04 (Figure 5). Following each file use, irrigation was performed with 2 ml of 2.5% NaOCl (Microvem, Turkiye) with a ultrasonic activation (DTE, Germany) device for the removal of the necrotic and inflamed pulp tissue in the resorption area. Following instrumentation, 2.5% NaOCl (Microvem, Turkiye) and 17% EDTA (Septodont, Poland) were used for final irrigation. The apical part of the distal canal was filled with single cone technique and the backilling was performed filled with gutta percha and epoxy resin canal filling paste (Dentac, Korea) using the thermoplastic enjection technique. The coronal restoration was completed with composite resin (Solarex, Japan). The rubber dam was removed and a postoperative digital radiograph was taken to verify the root canal filling (Figure 6).

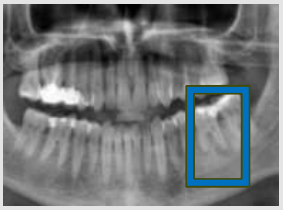
Figure 1:Panoramik radyography


Figure 2:Axial slice

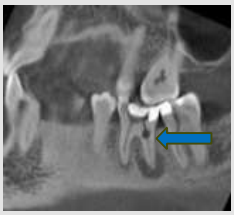
Figure 3:Sagittal slice

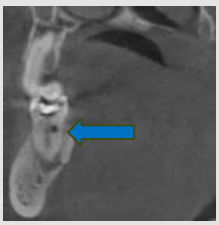
Figure 4:Transverse slice

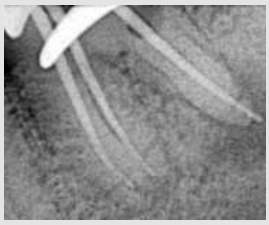
Figure 5: Gutta Perca Fitting

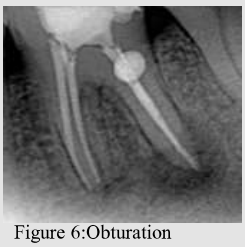
Figure 6:Obturation

At the six-month follow-up visit, the patient reported discomfort on percussion and signs of buccal sinus tract formation (Figure 7). Digital periapical radiographic examination showed a complete healing of the chronic apical periodontitis of the distal root and a J-type lesion related with mesial root (Figure 8). There was evidence of vertical fracture of the mesial root. Hemisectioning of the tooth was decided. The surgical procedure was explained and scheduled. Patient's consent was obtained. The tooth was carefully sectioned (Figure 9) and the fractured mesial fragment was removed (Figure 10). Any defects on the sound distal root were smoothened. Restoration of the remaining part completed under the rubber dam (Figure 11). The periapical radyography after hemisection is as it appears in Figure 12. Afterwards for the next phase of the treatment schedule involved the restoration of the hemisected tooth with a provisional crown, patient was referred to prosthodontist.


Figure 7:Sinus Tract Formation

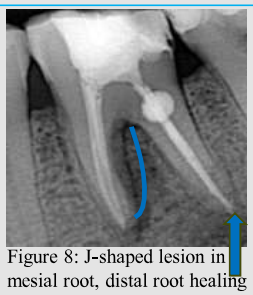
Figure 8: J-shaped lesion in mesial root, distal root healing


Figure 9: Sectioning


Figure 10: Remaining distal part


Figure 11: Restoration of the remaining part


Figure 12:Post operative

DISCUSSION

This case report shows how important it is to use a CBCT to correctly diagnose and manage root canal treatment in cases of internal root resorption associated with chronic apical periodontitis. Hemisection of the effected tooth allows the preservation of remaining tooth structure. Hemisection can be a relatively simple, conservative and inexpensive treatment with a high chance of success (Sharma et al.) Yuh et al. retrospectively analyzed the survival rates of a large cohort of root-resected molars and determined an overall survival rate of 91.1% in terms of demographic variables (Yuh et al).

CONCLUSION & CLINICAL REVELANCE

- ✓ The related tooth is asymptomatic and under follow-up.
- ✓ Hemisectioning was a treatment substitute to extraction in certain cases of VRF.
- ✓ CBCT is proving to be more reliable than conventional radiography in improving the diagnosis and management of internal root resorption.

REFERENCES

- Anitha S, Rao DS. (2015). Hemisection: A Treatment Option for an Endodontically treated Molar with Vertical Root Fracture. J Contemp Dent Pract. , 16(2), 163-5.
- Lyroudia KM, Dourou VI, Pantelidou OC, Labrianidis T, Pitas IK (2002). Internal root resorption studied by radiography, stereomicroscope, scanning electron microscope and com- puterized 3D reconstructive method. Dental Traumatology, 18(3), 148–5.
- Sharma S, Sharma R, Ahad A, Gupta ND, Mishra SK (2018). Hemisection as a conservative management of grossly carious permanent mandibular first molar. J Nat Sc Biol Med.,9(1), 97-99.
- Yuh DY, Lin FG, Fang WH, Chien WC, Chung CH, Mau LP, et al. (2014). The impact of medical institutions on the treatment decisions and outcome of root-resected molars: A retrospective claims analysis from a representative database. J Med Sci., 34(1),1–8.

GE073 | RETREATMENT OF A 1.1 IN A YOUNG PATIENT WITH AN OPEN APEX.

V. DUCEPT [1], G. LOROÑO [1], O. VALENCIA DE PABLO [1], A.J. CONDE VILLAR [1], R. PEREZ ALFAYATE [1]

[1] *Universidad europea de madrid. Faculty of Biomedical and Health Sciences. Department of clinical dentistry. Postgraduate, MADRID, SPAIN*

AIM: Highlight the importance of advanced techniques and biocompatible materials in the endodontic retreatment of open apices, demonstrating a successful clinical approach to ensuring long-term tooth preservation in young patients

Methodology: Open apices pose a significant challenge in root canal treatment and retreatment. Achieving a successful outcome is crucial for long-term tooth preservation in young patients. Magnification and advanced biocompatible materials optimize treatment success.

This case report presents an 11-year-old patient referred for endodontic retreatment before a potential surgical procedure. The patient had a history of dental trauma and prior root canal treatment on tooth 1.1. He presented with pain and swelling in the anterior maxillary region, with signs of acute apical abscess. Radiographic evaluation revealed an open apex, overextended root canal filling, and a large periapical lesion.

Retreatment was performed in one session using rotary files and sonic irrigant activation. Extruded gutta-percha was removed with pre-curved files under magnification. Final irrigation included 5.25% NaOCl, 17% EDTA, and sonic activation. An apical barrier was established with bioceramic material, followed by obturation with resin-based cement and injected gutta-percha.

At one month, the patient was asymptomatic. At nine months, radiographs showed periapical healing. At 19 months, CBCT confirmed significant healing of tooth 1.1. This case highlights the efficacy of advanced endodontic techniques in managing open apices.

Results: - Management of open apices in retreatment: The use of an apical barrier with biocompatible materials is an effective approach to manage open apices and promote periapical

-Importance of magnification and advanced instrumentation: The use of magnification facilitates the precise removal of extruded filling materials and ensures controlled instrumentation of the canal. Pre-curved files and adequate rotary systems, enhance the efficacy of retreatment in complex cases.

GE074 | Follow-up of a Radicular Cyst with Ultrasonography After Endodontic Treatment

[1]Yasemin Nur Şahin , [1]Evren Sarıyılmaz , [1]Hakan Eren

[1] Çanakkale Onsekiz Mart University, Faculty of Dentistry, Department of Endodontics

AIM-The aim of this case report is to evaluate the effectiveness of ultrasonography (USG), a non-invasive imaging method, in the follow-up of a radicular cyst after endodontic treatment. In addition to conventional radiographic methods, the role of USG in monitoring cystic lesions and its advantages will be assessed.

CASE PRESENTATION-A 56-year-old male patient presented to our faculty for a routine dental examination without any symptoms. Intraoral examination revealed fixed prosthetic restorations on teeth 11, 12, and 13.

CBCT examination showed a homogeneous radiolucent lesion measuring 19 × 14.7 × 12.8 mm, extending from the mesial aspect of tooth 11 to the region of tooth 14, with well-defined borders, slight palatal expansion, no resorption in the buccal cortical bone, and involving teeth 11, 12, and 13. The radiological preliminary diagnosis was radicular cyst.

Considering the asymptomatic condition of the patient and the size of the lesion, endodontic treatment was chosen as the primary approach. Teeth 11, 12, and 13 were found to be non-vital, and root canal treatment was indicated. Following this, the existing prosthetic restoration was removed. In the same session, root canals were shaped using a T-Must 40 reciprocating file, and calcium hydroxide dressing was applied twice at one-week intervals. In the third session, percussion and palpation tests revealed no symptoms, and the canals were filled with gutta-percha and a resin-based sealer using the lateral condensation technique.

This case demonstrates that radicular cysts may regress following endodontic treatment and can be monitored non-invasively using ultrasonography (USG). USG stands out as an alternative imaging method to conventional radiographic techniques in the evaluation of cystic lesions.



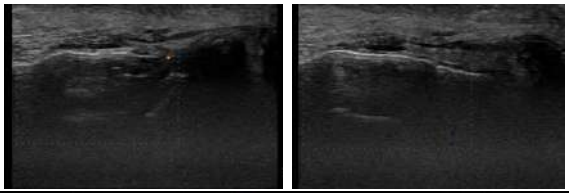

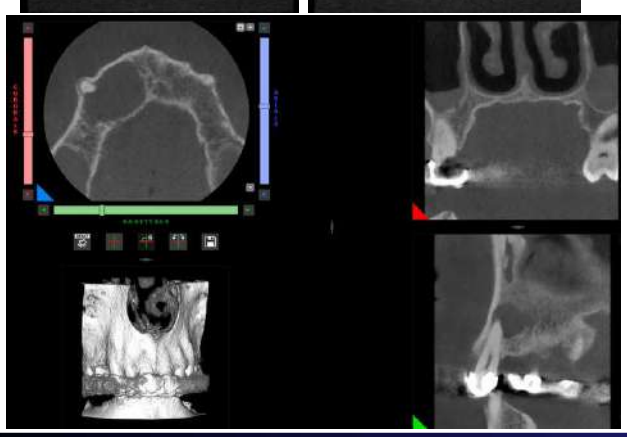

INTRODUCTION-

Radicular cysts are the most common odontogenic cystic lesions, developing as a result of chronic inflammation in the periapical region and often treatable through endodontic therapy. Conventional radiographs and CBCT are widely used imaging modalities for the diagnosis and follow-up of cystic lesions. However, ultrasonography (USG), which does not involve ionizing radiation, is gaining increasing importance as a non-invasive alternative that allows for the assessment of soft tissue content. The diagnostic accuracy of ultrasonography has been found to be 100% in cystic lesions. [1]. This case report presents a clinical case in which the healing process of a radicular cyst was evaluated using USG following endodontic treatment.

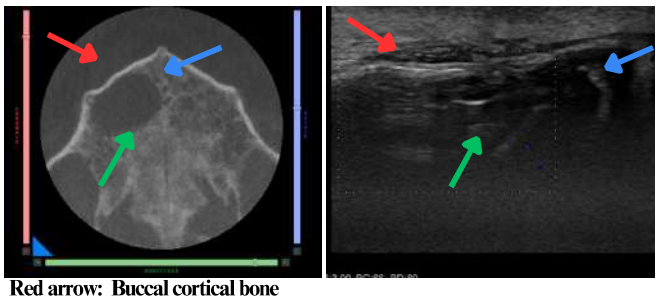

Red arrow: Buccal cortical bone
Green arrow:Palatal border
Blue arrow:Mesial border

DISCUSSION-Radicular cysts are asymptomatic odontogenic lesions that develop secondary to chronic periapical infections. Traditionally, they are treated with endodontic therapy or surgical enucleation. The commonly used diagnostic and follow-up methods, periapical radiography and CBCT, involve ionizing radiation, while ultrasonography (USG) offers a non-invasive and radiation-free alternative. USG has the advantage of distinguishing the fluid content of cystic lesions and evaluating the boundaries between soft tissue and bone structures. Literature suggests that it can detect early signs of healing in periapical lesions. USG is an effective tool for monitoring endodontic lesions, and further research is needed to encourage its wider use in follow-up.

CLINICAL RELEVANCE-This case highlights the effectiveness of endodontic approaches in the treatment of radicular cysts and demonstrates the advantages provided by ultrasonography in monitoring. This method offers a safer monitoring alternative by avoiding radiation exposure during the treatment process.

REFERENCES -

[1]Nidhi Puri, Upasana Sethi Ahuja, Manu Dhillon, Akshay Rathore (2018) Ultrasonography as a Diagnostic Aid in Evaluating Cystic Lesions, Benign Tumors and Malignancies of Maxillofacial Region: A Clinical Study, Open Dent J, 12, 1050-1058

Das S, Adhikari HD (2021) Reliability of Ultrasonography in differentially diagnosing periapical lesions of endodontic origin in comparison with Intra-oral periapical radiography and Cone-beam computed tomography: An in vivo study. J Conserv Dent, 24, 445-450.

GE075 | PULPAL HEALING AND ROOT MATURATION FOLLOWING DELAYED PARTIAL PULPOTOMY IN A COMPLICATED CROWN-ROOT FRACTURE WITH HYPERPLASTIC PULPITIS: A PAEDIATRIC TRAUMA CASE

A. OBEROI [1], A. BHATTACHARJEE [1], R.K. SINGH [1], R. KHANNA [1]

[1] *Faculty of Dental Sciences, KGMU- Department of Paediatric and Preventive Dentistry, Lucknow, INDIA*

AIM: To discuss a case of crown-root fracture managed with pulpotomy and fragment reattachment.

Methodology: An 8-year-old boy presented with a broken upper front tooth 14 days after the trauma. He had a complicated crown-root fracture in the permanent maxillary left central incisor. The fractured coronal fragment was palatally displaced with hyperplastic pulpal tissue protruding from the buccal fracture line in direct communication with the oral cavity. The tooth development stage at baseline was Nolla's stage 8 as viewed on an intraoral periapical radiograph. The displaced fragment was removed and meanwhile stored in normal saline. Partial pulpotomy was performed using a sharp spoon excavator and mineral trioxide aggregate as a pulp capping agent, followed by a glass ionomer cement coronal seal. Fragment reattachment was then performed. Follow-up was done at standard intervals as suggested by the International Association of Dental Traumatology guidelines in 2020. There were no signs of pathology, no patient-reported symptoms, and a change in development to Nolla's stage 9 by 6 months. Fragment reattachment failure was reported at 4th month due to re-injury. The patient is still under follow-ups.

Results: • Even after a long, 14-day delay in performing indicated endodontic therapy which is partial pulpotomy, the most gratifying aspect was its success marked by dentinal wall thickening and progression in root length.
• Fragment reattachment also was challenging owing to the fragment's sub-gingival extent in the palatal half of the tooth.
• A hyperplastic pulp, despite indicating an inflammatory reaction of the pulp, at the same time also reflects a positive pulp vitality. Pulpotomy proved to be successful in maintaining that vitality and bringing it to the benefit of the tooth as it continued the formation of the stunted root.
• A limitation in this case was the kid not being provided with protection from further trauma.

ÇANAKKALE ONSEKİZ MART UNIVERSITY,
FACULTY OF DENTISTRY, DEPARTMENT OF
ENDODONTICS, ÇANAKKALE,TÜRKİYE

GE076 | Endodontic Treatment of Mandibular Premolars with Different Root Canal Anatomy: Two Case Reports

Gamze Elif Han DDS, İrem Eren DDS, MSc

AIM: This study presents the endodontic treatment of two mandibular premolars with different root canal morphologies through two clinical cases.

INTRODUCTION: Mandibular premolars are commonly known for their single root canal anatomy; however, variations such as lateral canals or additional canals are not uncommon. These anatomical complexities can complicate diagnosis and treatment, potentially leading to failure if not managed properly. Advances in endodontic technology, such as dental operating microscopes and irrigation systems have improved the management of such cases.

CASE PRESENTATION: **Case 1:** A 33-year-old systemically healthy female patient presented with complaints of spontaneous pain and decay in the left mandibular first premolar. Clinical and radiographic examinations led to a diagnosis of symptomatic irreversible pulpitis. Periapical radiography revealed branching of the root canal in the middle third. Access cavity preparation was performed under rubber dam isolation and a dental operating microscope. The canal system was classified as Vertucci Type 3. The canals were instrumented using a reciprocating system. EDDY was used to activate the irrigants. The branched portion was obturated using the down-pack technique, while the coronal portion was filled with thermoplastic gutta-percha and a bioceramic sealer. A follow-up radiograph could not be taken due to pregnancy. After 3 months, the tooth remained asymptomatic.

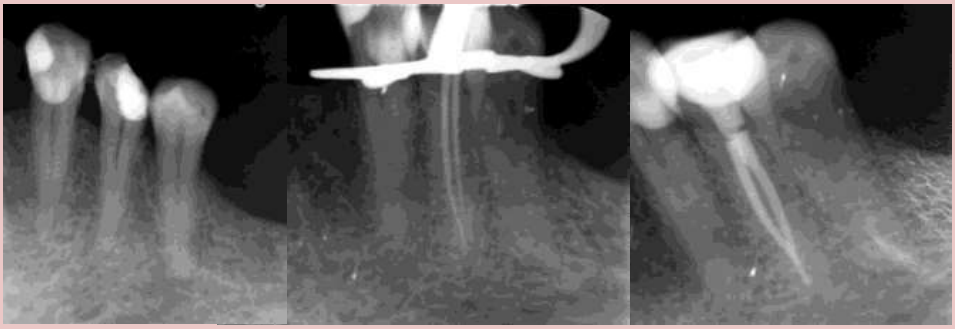

Fig. 1: Preoperative, Intraoperative, Postoperative periapical radiograph



Fig. 2: Preoperative, Intraoperative, Postoperative and 3-month follow-up periapical radiograph

Case 2: A 55-year-old systemically healthy male patient presented with decay in the right mandibular second premolar. Clinical and radiographic examinations led to a diagnosis of asymptomatic irreversible pulpitis. Periapical radiography revealed branching of the root canal in the middle third. Two canals were accessed under rubber dam isolation and a dental operating microscope, then instrumented using a reciprocating system. EDDY was used to activate the irrigants. During obturation, EDDY was also used to enhance sealer penetration. The branched portion was obturated using the down-pack technique, while the remaining portion was filled with thermoplastic gutta-percha. At the 3-month follow-up, the tooth remained asymptomatic. The follow-up process is ongoing.

DISCUSSION: Anatomical variations in mandibular premolars can complicate endodontic treatment. The Vertucci Type 3 configuration in Case 1 and the branching in Case 2 emphasize the necessity of thorough radiographic and clinical evaluation. Adapting treatment protocols to these complexities ensures effective cleaning, shaping, and obturation.

CLINICAL RELEVANCE: Clinicians should be aware of potential anatomical variations in mandibular premolars. Advanced tools, such as dental operating microscopes and irrigation systems, can significantly improve treatment outcomes. Individualized treatment plans tailored to each tooth's anatomy are essential for long-term success.

REFERENCES:

1.Vertucci, F. J. (1984). Root canal anatomy of the human permanent teeth. *Journal of Endodontics*, 10(3), 117-124.

2.De-Deus, G., et al. (2015). EDDY sonically activated irrigation for root canal disinfection: A micro-CT study. *Journal of Endodontics*, 41(5), 678-683.

GE077 | ROOT CANAL TREATMENT OF TOOTH 4.5 MANAGING A SEVERELY CURVED CANAL WITH ROOT PERFORATION

O. WEIL [1], A. CONDE VILLAR [1], R. ESTEVEZ [1], C. SANCHEZ PADILLA [1], R. PEREZ ALFAYATE [1]

[1] *Universidad Europea de Madrid. Faculty of Biomedical and Health sciences. Departement clinical dentistry . Postrgradate, Madrid, SPAIN*

AIM: Root canal treatment of tooth 4.5 with a doubled curvature and a perforation

Methodology: Despite advancements in technology, the intricate anatomy of dental pulp and root canals remains a significant challenge in endodontics. Managing cases with severe curvatures, particularly those with double curvatures, requires meticulous planning to prevent perforations and ensure effective cleaning and obturation. Historically, such cases were nearly impossible to treat successfully. However, the evolution of NiTi instruments has revolutionized endodontic practice, enabling clinicians to navigate complex canal anatomies with greater precision and safety. This presentation highlights the importance of understanding root morphology and the critical role of modern instrumentation in improving treatment outcomes.
A patient was referred the clinic after two unsuccessful treatment attempts, accompanied by an explanatory report detailing the diagnosis and previous procedures. The initial diagnosis at the referring clinic was pulpal necrosis with symptomatic apical periodontitis.

Radiographic examination revealed a radiolucency beyond the first curvature, indicating a perforation at this level. Given the complexity of the case, treatment was meticulously planned, and treated in three appointments. The first session focused on achieving apical patency, followed by careful instrumentation to navigate the severe curvature, and finally, a well-controlled obturation to ensure long-term success.
Additionally, a case review of at least 6 months was conducted to assess the treatment outcome and confirm long-term healing.
This case underscores the challenges of managing complex root anatomy and highlights the importance of precise planning in endodontic treatment.

Results: • Importance of a careful treatment approach: successfully managing difficult cases requires a well-planned method, ensuring thorough cleaning, shaping, and sealing of the canals.
• Be aware of the available tools: advances as CBCT, files with (Nickel-Titanium) etc. have made it possible to handle intricate root shapes more efficiently and with greater precision.

GE078 | Non-Surgical Management of a Crown Fracture with A Cyst-Like Periapical Lesion: A Case Report

~~Damla Erkal~~, Damla Kırıcı, Kürşat Er

Department of Endodontics, Faculty of Dentistry, Akdeniz University, Antalya, Türkiye

Aim

The aim of this case report is to present the successful treatment of a maxillary central incisor with a complicated crown fracture, and to emphasize the importance of modern endodontic techniques, the use of bioceramic filling materials and completing the patient's treatment with an esthetic filling to achieve positive clinical and radiographic results.

Introduction

Traumatic injuries to the teeth may result in damage to many dental and periradicular tissues. The most frequently affected teeth are the maxillary anteriors. A complicated crown fracture is a severe dental injury defined as a fracture involving enamel, dentine, and pulp. Early treatment of crown fractures seek to maintain pulp vitality. Nonetheless if the tooth is devitalized, root canal treatment should be considered as a treatment plan.

Case presentations

A 21-year-old female patient presented to the Faculty of Dentistry at Akdeniz University with an aesthetic complaint. The patient's medical history revealed no systemic diseases. Intraoral examination showed a crown fracture in tooth #21. Upon questioning the patient's dental history, it was learned that she had injured her anterior teeth two years prior. Electric pulp testing and cold testing on tooth #21 yielded no response. Although the tooth was asymptomatic, the patient reported occasional pain and swelling in the buccal mucosa. Radiographic examination revealed a periapical lesion at the apex of tooth #21.

Under rubber dam isolation an access cavity was made. After chemo-mechanical preparation up to ProTaper X5 file, the root canal was dried using sterile paper points, and calcium hydroxide paste was placed as an intracanal medicament. The canal orifice was sealed with a sterile Teflon tape and temporarily restored using resin-modified glass ionomer cement. The patient was scheduled for a follow-up appointment in two weeks.

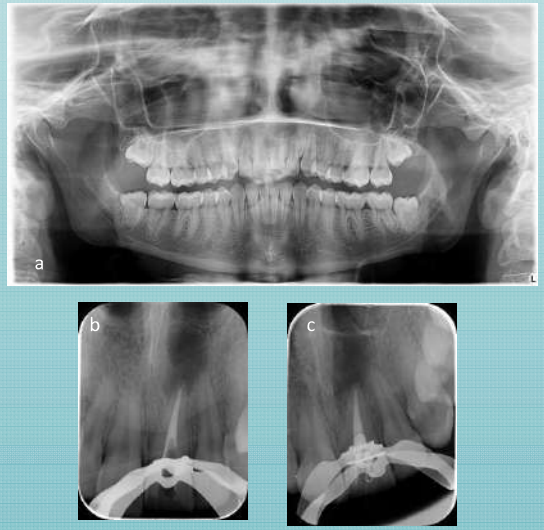

Figure 1. *Panoramic radiographof the patient taken before treatment (a), periapical radiographs taken from patient during treatment (b,c).*

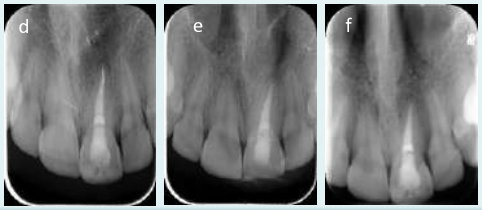

Figure 2. *Periapical radiographs of #21at 6 (d), 12 (e) and 24 (f) month control session.*

At the second appointment, calcium hydroxide paste was eliminated and mineral trioxide aggregate (MTA) was placed into the apical region using an MTA carrier, following the manufacturer's instructions. Apical sealing was achieved with 7–8 mm of condensed MTA using an endodontic plugger. A 12-minute setting time was allowed for the initial hardening of the MTA. The remaining root canal space was filled with a bioceramic sealer and obturated using the warm vertical compaction technique.. The root canal filling was confirmed radiographically, after which the whitening procedure was initiated to meet the patient's aesthetic expectations. The access cavity was filled with 35% hydrogen peroxide gel and temporarily restored with resin-modified glass ionomer cement.

At the three-day follow-up, significant color improvement in the tooth was observed. After rubber dam isolation, the bleaching agent was removed using sterile saline. dried. Following the application of bonding agent, the aesthetic restoration was completed using Estelite Asteria (Tokuyama Dental,Tokyo, Japan).

At the two-year follow-up, the patient reported no symptoms. Periapical radiographic examination revealed a significant reduction in lesion size and evidence of bone healing.

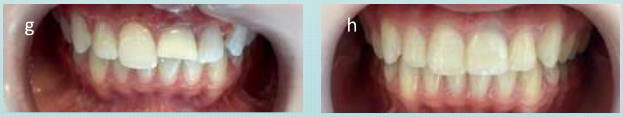

Figure 3. *Intraoral photographs of patient before (g) and after (h) treatment.*

Discussion

Trauma to the anterior teeth is a critical condition that requires immediate intervention, as it can have significant implications for both the patient's dentition and psychological well-being. Conventional approaches for the restoration of fractured teeth include partial coverage crowns, full coverage crowns, composite resin restorations, and laminate veneers. These treatment modalities aim to restore both the structural integrity and esthetic appearance of the affected tooth, ensuring long-term functionality and durability.

Clinical Relevence

Early intervention and proper endodontic treatment for complicated crown fractures, including the use of bioceramic materials and internal bleaching, are crucial in achieving long-term functional and esthetic success. This case emphasizes the importance of timely diagnosis and appropriate treatment planning in managing traumatic dental injuries.

References

Lakshmaiah D, Sr V, Ilango S, Sakthi N, Ps S. Management of Complex Crown Fractures: A Case Series. Cureus. 2023 ;15(4):e37907.

Patil M, Hegde V, Khan M, Kharbe N, Ghunawat D. Holistic management of complicated crown fracture: A case series. J Conserv Dent Endod.;26(6):719-723.

Address Information:
Damla ERKAL
Department of Endodontics, Faculty of Dentistry, Akdeniz University, Antalya, Türkiye
Dumlupınar Boulevard, Campus, Konyaalti, Antalya
Email: *damlaerkal@akdeniz.edu.tr*

GE079 | NITRATE-SIALIN PREVENTS PERIAPICAL LESION AND SYSTEMIC DISEASES BY MACROPHAGE REGULATION

S. LI [1], Y. LIU [1], X. WEN [1], Y. LIN [1], C. ZHANG [1], S. WANG [1]

[1] *Beijing stomatological hospital, Capital Medical University, Beijing, CHINA*

AIM: Oral health is closely linked to overall health. The incidence of immune-related diseases is increasing annually, affecting younger age groups every year. However, existing treatments such as corticosteroids have noticeable side effects and high rates of drug resistance. Efforts need to achieve better therapeutic approaches. Our research group has previously carried out extensive studies on nitrates, discovering that nitrate intake can increase Sialin expression in multiple models. Yet, whether nitrate-Sialin plays a role in immune regulation and the underlying mechanisms remain unclear. This study aims to investigate whether Sialin can modulate the immune system and potentially treat immune-related diseases.

Methodology: In Vivo Experiments: Using mouse periapical lesion and non-alcoholic liver disease models as representatives of oral and systemic immune-related diseases, we administered drinking water supplemented with nitrate and analyzed Sialin expression, inflammatory markers. etc. We also used bone marrow cells of Sialin-knockout mouse or normal mouse in transplantation into immunocompromised mice to establish a non-alcoholic fatty liver disease model, with or without nitrate supplementation, to examine relevant indicators. In Vitro Experiments: Stable overexpression of Sialin was established in macrophages, followed by exposure to differentiation stimuli, to measure immune-related factors.

Results: Sialin could upregulated by nitrate and prevented diseases. Following bone marrow transplantation with Sialin-knockout cells, nitrate lost its effects, showing significantly reduced regulations on macrophages. Overexpression of Sialin promoted apoptosis in pro-inflammatory macrophages while inhibiting apoptosis in anti-inflammatory macrophages.

Conclusions (mandatory): Nitrate-Sialin could regulate macrophages, providing evidence for the clinical prevention and treatment of immune-related diseases including periapical lesion and non-alcoholic liver disease.

Acknowledgements (optional): This work was supported by the National Natural Science Foundation of China (82201054).

GE080 | ROOT CANAL RETREATMENT OF TOOTH 11. MANAGEMENT OF A ROOT CANAL PERFORATION.

M.M. COLL ABRINES [1], A. CONDE VILLAR [1], G. LOROÑO GOIKOETXEA [1], R. PÉREZ ALFAYATE [1], R. ESTÉVEZ LUAÑA [1]

[1] *Universidad Europea de Madrid. Faculty of Biomedical and Health Sciences. Department of clinical dentistry ., Madrid, SPAIN*

AIM: Root canal retreatment of 11 with root canal perforation.

Methodology: A patient presented with pain in tooth 11, which had undergone root canal treatment six years earlier. CBCT confirmed a root canal perforation with gutta-percha extrusion through the buccal cortical bone, along with apical periodontitis, leading to a diagnosis of symptomatic apical periodontitis in a previously treated tooth. A non-surgical retreatment was performed in two sessions using a microscope for enhanced visualization. During the first session, the previous filling material in the canal was removed, disinfected, and instrumented with rotary files up to 25.04, while the extruded gutta-percha from the perforation was carefully removed, and calcium hydroxide was placed as intracanal medication. In the second session, the canal was thoroughly irrigated, and obturated with gutta-percha and epoxy resin-based sealer, while the perforation site was sealed with a bioceramic repair material. At the 24-month follow-up, radiographic examination confirmed complete healing, with the remaining extruded gutta-percha remaining stable without any clinical complications.

Results: • CBCT imaging provides a more accurate diagnosis, allowing for better treatment planning in complex cases.

• The use of a microscope significantly enhances visualization and precision, ensuring effective management of anatomical variations and procedural challenges.

• Proper sealing of root perforations with bioceramic repair materials plays a crucial role in successful long-term outcomes.

GE081 | THE IMPACT OF TEMPERATURE AND TOOTH TYPE ON PULP CHAMBER HEATING DURING ENDODONTIC THERMAL DIAGNOSTICS: AN IN VITRO STUDY

A. STRUKAN [1], A. IVICA [2], M. PAR [2], M. NARANCIC [3], I. MILETIC [2], S. JUKIC KRMEK [2]

[1] *PhD student, University of Zagreb, School of Dental Medicine, Zagreb, CROATIA*
[2] *University of Zagreb, School of Dental Medicine, Department of Endodontics and Restorative Dentistry, Zagreb, CROATIA*
[3] *Dental polyclinic Zagreb, Zagreb, CROATIA*

AIM: Thermal tests in endodontic diagnostics can increase pulp chamber temperature, potentially damaging vital pulp or periodontium. This in vitro study investigated the relationship between temperature output and tooth type in achieving a 5 C threshold increase.

Methodology: Forty-five extracted teeth (9 lower incisors, 9 canines, 13 premolars, 14 molars) were used. A thermal probe was placed in the pulp chamber through a 2 mm hole on the oral side, sealed with thermal paste, and teeth were fixed in a 37 C water bath. Heat from a Fast Pack (Eighteeth Co., China) was applied via a fine medium plugger (50/0.05) to the vestibular surface for 30 seconds at 250 C, 150 C, and 90 C. Temperature changes were recorded over 55 seconds using the Testo Smart App.

Results: At 90 C, 67% of lower incisors, 0% of canines, 23% of premolars, and 7% of molars reached the critical temperature. At 150 C, critical temperatures were achieved in 89% of lower incisors, 67% of canines, 77% of premolars, and 36% of molars. At 250 C, 100% of lower incisors, 89% of canines, 100% of premolars, and 71% of molars reached the threshold. The differences in the time required for the samples to heat up to the critical 5 C are statistically significant at a temperature of 250 C and 150 C ($p < 0.001$), but not at 90 C due to low number of specimens that reached critical temperature.

Conclusions (mandatory): These findings emphasize the need to consider tooth type and temperature settings in thermal diagnostics to reduce risks of pulp damage. Further research with larger samples is recommended to refine clinical guidelines.

GE082 | MICRO-COMPUTED TOMOGRAPHY COMPARISON OF THREE PREPARATION TECHNIQUES AND PERICERVICAL DENTIN PRESERVATION IN PREMOLARS WITH CONVENTIONAL VS. CONSERVATIVE ENDODONTIC ACCESS

A. GUSIYSKA [1], M. RAYKOVSKA [2], E. GYULBENKIYAN [3]

[1] *Medical University, Faculty of Dental Medicine, SOFIA, BULGARIA*
[2] *Institute for Information and Communication Technologies, Bulgarian Academy of Sciences, SOFIA, BULGARIA*
[3] *Medical University, Faculty of Dental Medicine, SOFIA, BULGARIA*

AIM: To evaluate the volume of remaining pericervical dentin (PCD) in teeth with conventional and conservative endodontic access and three preparation techniques in premolars by micro-computed tomography (micro-CT).

Methodology: Thirty-five human premolars were allocated in two main groups and one control group (n=35). Teeth in Group I (conventional access) and Group II (conservative access) were divided into three Subgroups with 5 premolars each (n=5). Subgroups 1 were prepared with XP-endo Shaper (XP), Subgroups 2 were prepared with hybrid Step back technique (SBT) and Subgroups 3 were prepared with ProTaper Next (PTN). After preparation, the premolars were scanned again, and the images were reconstructed with the NRecon v.1.7 (Bruker micro-CT) via filtered back projection and analysed with CTAn v.1.20.8 software (Bruker micro-CT) VG Studio 2023.4 (Hexagon, Heidelberg). Fisher tests and ANOVA were performed in this study.

Results: The average percentage reduction in pericervical dentin thickness in the studied specimens was 26.08 +/- 9.88% for Group I, 23.48 +/- 9.77% for Group II and 22.20 +/- 6.24% for Group III. The ratio of treated/untreated surface in the pericervical dentin area was established and analysed by micro-CT study in both types of endodontic access - conventional and conservative. The average value of dentin removal for the specimens with conventional endodontic access from Group I is LI=0.30, and for Group II, it is LII=0.216. Statistical analysis revealed a minimal statistically significant difference ($p<0.05$). In Group II Subgroups 1 and 2, the hard dental tissues are maximally preserved in the coronal and radicular zones of the pericervical dentin ($p>0.05$).

Conclusions (mandatory): While conservative endodontic access and preparation with XP would prevent excessive PCD removal, this would negatively affect maximum preparation efficiency through the root canal space.

GE084 | A RETROSPECTIVE EVALUATION OF THE HEALING PROCESS IN THE PERIAPICAL AREA OF TEETH OBTURATED WITH EPOXY SEALER AND VERTICAL COMPACTION OF WARM GUTTA-PERCHA

R. TODOROVA/MILCHEVA [1], A. GUSIISKA [2], S. GRANDINI [3]

[1] *Medical University, Faculty of dental medicine, Sofia, BULGARIA*
[2] *Medical University, Faculty of dental medicine, Sofia, BULGARIA*
[3] *University of Siena, School of dental medicine, Siena, ITALY*

AIM: The aim of this retrospective radiographic study is to monitor the postoperative healing process of teeth with periapical osteolytic bone defects. The preoperative and postoperative status was determined by Ørstavik's PAI score.

Methodology: The treated teeth (n=140) were divided into four groups based on the preoperative Ørstavik's PAI score: Group I - preoperative PAI 2 – (n=35); Group II - preoperative PAI 3 – (n=35); Group III - preoperative PAI 4 – (n=35) and Group IV - preoperative PAI 5- (n=35). In this study the quality of the root canal obturation was evaluated for sealer extrusion, gutta-percha extrusion, filling voids and root filling level. The postoperative assessment and determination of the PAI score after the treatment was done respectively for Groups I to IV by parallel digital radiographs. The same obturation(epoxy sealer AH plus- Dentsly Sirona and warm gutta-percha) and irrigation protocol is observed for all of the cases.

Results: In Group I all of the teeth demonstrate healing at one year follow up. In Group II two teeth were extracted. The success rate in this group is 94,28%. The analysis and assessment of the results in Group III showed that after one year, a successful periapical healing process was observed in 91.66% of cases using strict criteria- absence of clinical symptoms and complete resolution of periapical radiolucency. In 8,34 % of the cases in this group we have observed absence of clinical symptoms with periapical regeneration.
In Group IV two cases demonstrate symptoms and no decrease in size of apical radiolucency so they are planned for surgery. Four cases demonstrate symptoms resolution and satisfactory recovery process and two cases demonstrate complete healing.

Conclusions (mandatory): In the limitation of this investigation monitored clinical cases for the determined period show that the observance of exact clinical protocol leads to satisfactory recovery process in periapex.

GE085 | SELECTIVE PERIAPICAL MICROSURGERY OF THE MESIAL ROOT OF TOOTH 46

A. LETZELTER [1], B. TEJEDOR BAUTISTA [1], R. PEREZ ALAFAYATE [1], A.J. CONDE VILLAR [1], R. ESTEVEZ LUAÑA [1]

[1] *Universidad europea de madrid. Faculty of Biomedical and Health Sciences. Department of clinical dentistry. Postgraduate, MADRID, ESPAÑA*

AIM: The periapical surgery aims is to eliminate infection, resect the affected root apex (apicoectomy), and achieve a retrograde seal to prevent bacterial reinfection. Additionally, it seeks to preserve the tooth by promoting periapical healing and bone regeneration, thereby ensuring long-term functional and biological success.

Methodology: The patient presented to the clinic with masticatory pain in the fourth quadrant. A root canal treatment had been performed on the tooth 46 six years earlier. Radiographic examination revealed a periapical lesion affecting the mesial root of tooth 46.
In endodontics, diagnosis can be challenging when relying solely on two-dimensional radiographs. However, CBCT offers high-resolution three-dimensional imaging, which enhances diagnostic accuracy and aids in more effective treatment planning. The CBCT revealed stripping in the mesial canals and incomplete cleaning and obturation of the isthmus between the mesio-buccal and mesio-lingual canals. The distal root showed no signs of periapical lesions, but the mesial root exhibited external apical resorption due to apical periodontitis.
The diagnosis was symptomatic apical periodontitis in a tooth previously treated. The chosen treatment was periapical surgery. A full-thickness flap was elevated with an intra-sulcular design, preserving the papilla. Osteotomy and apicoectomy of 3mm were performed using piezoelectric instrumentation. The isthmus connecting the two canals was identified, and retropreparation was carried out to a depth of 3 mm, followed by retrograde filling with IRM.

Results: -The complex anatomy of the lower first molars, particularly the mesial root, poses significant challenges for endodontists due to the presence of numerous isthmuses connecting the root canals.

-The highest occurrence of RCI (87.9%) has been found in these molars, with isthmuses most commonly located in the mesial canals, particularly in the apical third.

-This anatomy complicates mechanical instrumentation and effective chemical disinfection.

GE086 | BIOCERAMIC MATERIALS IN DENTISTRY: A COMPARATIVE REVIEW OF PROPERTIES AND CLINICAL APPLICATIONS

M.I. COUTINHO [1], E. AYLLON [1]

[1] *Universitat internacional da Catalunya, Barcelona, SPAIN*
[2] *Universitat Internacional da Catalunya, Barcelona, SPAIN*

AIM: Bioceramics, known for their excellent bioactivity and biocompatibility, are widely used in dentistry, particularly in endodontics. Recently, new bioceramic materials have been developed, showing promising potential for endodontic treatments, and this paper reviews their characteristics and applications in various clinica cases.

Methodology: A search was conducted in PubMed, Google scholar using the keywords bioceramics endodontics, mineral trioxide aggregate, and the names of all bioceramics (BECs) studied in this paper. Additional terms such as resorption, perforation repair, root-end filling, pulp capping, regenerative endodontic treatment, and apexification were used to identify relevant clinical applications. Reference mining of selected articles was also performed, and only articles with pertinent information were included

Results: New bioceramics aim to overcome MTA limitations by offering shorter setting times, improved handling, and reduced discoloration, although their long-term performance still requires further validation. Biodentine and Iroot SPdemonstrate high compressive strength and bioactivity. Biodentine, MTA Repair HP, and Angelus MTA have the fastest setting times, while BioRoot RCS and BioAggregate exhibit high solubility. Biodentine and ProRoot MTA are excellent for vital pulp therapy due to their bioactivity and sealing ability. CeraSeal, TotalFill BC Sealer, and NeoSealer are ideal for canal obturation because of their flowability and minimal risk of discoloration. Angelus MTA and MTA Fillapex can cause discoloration, limiting their aesthetic applications. ProRoot MTA and Neoputty have high radiopacity, ensuring good visibility in radiographic evaluations.

Conclusions (mandatory): ProRoot MTA remains the gold standard due to strong clinical evidence supporting its effectiveness, but its long setting time, handling difficulty, discoloration, and high cost are significant drawbacks. New bioceramics offer improved properties and can be used in various clinical situations, yet further studies are needed to validate their long-term performance.

GE090 | AN INTERDISCIPLINARY APPROACH FOR RESTORING ENDODONTICALLY TREATED POSTERIOR TEETH WITH EXTENSIVE TOOTH LOSS—REPORT OF CASES.

M. VAKALIS [1]

[1] *Aristotle University of Thessaloniki-School of Dentistry- Department of Dental Surgery & Biomaterials, Thessaloniki, GREECE*

AIM: This presentation aims to provide a comprehensive, interdisciplinary approach to restoring endodontically treated posterior teeth with extensive tooth loss, ensuring long-term functional and aesthetic success.

Methodology: The talk discusses the challenges of restoring posterior teeth that have undergone significant tissue loss, especially when endodontic treatment is necessary. A thorough diagnostic evaluation is essential, considering factors like restorability, periodontal health, and masticatory function. Two case reports of mandibular molars demonstrate a step-by-step treatment approach incorporating periodontal therapy, endodontic treatment, and monolithic lithium disilicate ceramic restorations (e-max). The process includes careful case selection, proper material choice, and an interdisciplinary approach to ensure optimal outcomes. The three-year follow-up results suggest that these techniques offer promising long-term success. The presentation emphasises the importance of a flexible, case-specific treatment approach rather than a one-size-fits-all protocol, highlighting the need for adaptability and clinical judgment in complex cases.

Results: • The restoration of endodontically treated teeth requires a multifactorial assessment, considering periodontal health, restorability, and occlusal function.

• A holistic and interdisciplinary approach is necessary for cases with extensive tooth loss and periapical pathology.

• Monolithic lithium disilicate ceramic restorations (e-max) offer durable and aesthetic results in complex posterior restorations.

• No universal restoration protocol exists; individualised treatment planning is key to long-term success.

• The three-year follow-up of treated cases shows promising functional and aesthetic outcomes with the described approach.

MANCHESTER 1824
The University of Manchester
Dr Nicky Dehbonei
Dr Mitra Elli

GE091 | Regenerative Endodontic treatment on tooth UL1 at UDH Manchester

- 29 years old male patient referred by his GDP for RCT of tooth UL1 , with history of trauma during teenage time.
- Patient chief complaint: "I was referred by my dentist for my front tooth; I had a trauma on it when I was a teenager but I don't recall exactly when"
- Currently: patient is asymptomatic.
- Medical history : N/A ; patient smokes 4 cigarettes a week



Preoperative PA 21/06/2023

Clinical findings

UR2 and UL2 are missing / extracted due to previously failed RCTs / partial denture for replacing both teeth
Tooth UL1 : No pain/ tenderness on percussion of UL1
No swelling or sinus tract on either buccal/ palatal soft tissues surrounding UL1
No mobility/ No bleeding upon probing
Unresponsive to Endofrost cold test

Diagnosis

Pulpal necrosis of tooth UL1 caused by previous trauma, associated with chronic asymptomatic apical periodontitis.

Treatment options chosen by the patient:
Regenerative endodontic treatment attempt on tooth UL1.
If treatment fails, then RCT will be performed on the tooth.

Regenerative endodontic treatment

Treatment performed	Reflection/explanation
1rst Session • Consent form for both RET and RCT were signed by the patient • Anaesthesia in buccal infiltration of UL1 + palatal intraligamentary reinforcement with 1 cartridge of lignocaine 2% with adrenaline 1/80000 • Single tooth isolation with butterfly clamp and rubber dam • Tooth UL1 accessed and patency achieved • Only 1 canal and WL = 21mm • Irrigation with NaOCl 1% • Canal is prepared with MAF F2 Protaper Gold rotary file • Use of sterile water and final rinse with EDTA 17 % • Canal is dried using F2 sterile paper points • Tooth UL1 is dressed using calcium hydroxide • Periapical radiograph taken when tooth dressed • Postoperative instructions given to the patient  PA: UL1 dressed with calcium hydroxide 05/07/2023	• Patient's age is over 18 years old but the state of the apex and absence of symptoms allowed both the clinician and attempt RET (1) (2) • An effective bacterial load reduction is key for reduction of symptoms and periapical bone healing induction (2) • 8% conicity leads to an effective intracanal bacterial load reduction compared to 4% conicity. (3) • F2 Protaper Gold rotary file has an 8% taper at tip. (4) • Combination of NaOCl 1% and EDTA 17 % increase the alkalinity of periapical environment. (5) • Alkaline environment is hostile for root canal bacterial microbes. (5) (6) • Calcium hydroxide helps keeping a high level of alkalinity in the root canal. (7) • Inflammatory environment limit the retention of stem cells to the root canal walls , therefore it is important to provide the least inflammatory environment possible. (8)
2nd session • Since last visit, patient did not have any pain or discomfort upon tooth UL1 • Removal of Fuji IX GIC palatal temporary filling • Copious irrigation with use of NaOCl 1%, sterile water and EDTA 17% • Use of sterile F3 paper points to dry the canal • Tooth UL1 is re dressed using calcium hydroxide, cotton pellets and Fuji IX GIC temporary filling • This session was only a reirrigation and recleaning session, because of summer 2023 break, there has been a time lapse of 6 weeks between the current one and the previous one • Current session was shorter and clinician did not have enough time to perform stage II of RET treatment	• Long term calcium hydroxide dressing causes the root canal to be less resistant to fracture risk. (9) • Another cleaning session allows to make sure that pathogens haven't reproliferated inside the root canal (10) • Calcium hydroxide is the intracanal medication of choice since it is the one which affects cell viability/ survival the least (10) (11)
3rd session • Since last visit, patient did not have any discomfort or pain upon tooth UL1. • No signs of swelling, sinus tracts and abscesses on either buccal or palatal sides of tooth UL1 • Anaesthesia with mepivacaine 3% without vasoconstrictor • Isolation with rubber dam and premolar clamp • Palatal temporary filling removed • Irrigation with sterile water + EDTA 17% • Use of pre-curved 20 H files + XP finisher at 500 rpm and 1.6 torque beyond WL for bleeding induction • Bleeding induced after a few minutes, placement of hemocollagene + biodentine above • Use of light cure Fuji II GIC + composite for palatal access cavity  UL1 postoperative PA 25/10/2023	• Patient was without symptoms therefore it was possible to continue with the second stage of RET (5) • The use of non-vasoconstrictor local anaesthesia favours an adequate and controlled bleeding during blood clot induction (12) • Irrigation with EDTA 17% enhances migration and proliferation of periapical stem cells (10) • XP-finisher helps with debridement all the walls of the root canal and activation of irrigants. (11) • Pre-curved 20 H files are used for cautiously inducing bleeding , sometimes together with XP finisher , 2 mm past the apical foramen (12) • Collagen , in this case Hemocollagene sponge, is used as a scaffold to enhance cell adhesion and pulp-like tissue regeneration (13) • Biodentine is as efficient as MTA and prevents the tooth from further discolouration ; which is favourable in aesthetic areas. (14)(15)
Following sessions • Patient came for review on two different dates: only dates he could attend due to work commitment • Both session: ➢ No TTP ➢ No periodontal pockets ➢ No abscesses, swelling or sinus tracts ➢ Tooth is unresponsive to cold test ➢ Periapical lesion has reduced ➢ Apical closure is observed ➢ Patient has no discomfort or pain • Patient will continue being reviewed at the Dental Hospital of Manchester  Review PA April 2024 — Review PA October 2024	• Regenerative endodontics procedure has a success rate between 50% to 98% and survival rate between 94%-100% (1) • Apical closure, periapical lesion reduction, root lengthening with absence of symptoms are observed during both post operative review appointments, allowing the tooth to be functional. (16) • Pulp sensibility is not always regained after RET procedure, patient needs to keep coming for more review appointments (17)

References

1. Rojas-Gutiérrez WJ, Pineda-Vélez E, Agudelo-Suárez AA. Regenerative Endodontics Success Factors and their Overall Effectiveness: An Umbrella Review. Iran Endod J. 2022 Summer;17(3):90-105. doi: 10.22037/iej.v17i3.32703. PMID: 36704087; PMCID: PMC9869084.
2. Sellami R, Van Holm W, Meschi N, Van Den Heuvel S, Pauwels M, Verspecht T, Vandamme K, Teughels W, Lambrechts P. Regenerative endodontic procedures in immature permanent teeth with pulp necrosis: the impact of microbiology on clinical and radiographic outcome. Front Dent Med. 2023 Nov 14;4:1281337. doi: 10.3389/fdmed.2023.1281337. PMID: 39916917; PMCID: PMC11797765.
3. Paraskevopoulou MT, Khabbaz MG. Influence of Taper of Root Canal Shape on the Intracanal Bacterial Reduction. Open Dent J. 2016 Oct 31;10:568-574. doi: 10.2174/1874210601610010568. PMID: 27857818; PMCID: PMC5093865.
4. Singh, S. *et al.* (2023) 'An appraisal on newer endodontic file systems: A narrative review', *The Journal of Contemporary Dental Practice*, 23(9), pp. 944–952. doi:10.5005/jp-journals-10024-3398.
5. Wei X, Yang M, Yue L, Huang D, Zhou X, Wang X, Zhang Q, Qin L, Huang Z, Wang H, Meng L, Li H, Chen W, Zou X, Ling J. Expert consensus on regenerative endodontic procedures. Int J Oral Sci. 2022 Dec 1;14(1):55. doi: 10.1038/s41368-022-00206-z. PMID: 36450715; PMCID: PMC9712432.
6. Bucchi, C., Bucchi, A. and Martínez-Rodríguez, P. (2024) 'Biological properties of stem cells from the apical papilla exposed to lipopolysaccharides: An in vitro study', *Archives of Oral Biology*, 159, p. 105876. doi:10.1016/j.archoralbio.2023.105876.
7. Lee Y. Effect of calcium hydroxide application time on dentin. Restor Dent Endod. 2013 Aug;38(3):186. doi: 10.5395/rde.2013.38.3.186. PMID: 24010088; PMCID: PMC3761130.
8. Bhandi S, Patil S, Borzak N, Chohan H, AbuMelha AS, Alkahtany MF, Almadi KH, Vinothkumar TS, Raj AT, Testarelli L. Effect of Different Intracanal Medicaments on the Viability and Survival of Dental Pulp Stem Cells. J Pers Med. 2022 Apr 4;12(4):575. doi: 10.3390/jpm12040575. PMID: 35455691; PMCID: PMC9032254.
9. Lee, J.Y. *et al.* (2018) 'Regenerative endodontic procedures among endodontists: A web-based survey', *Journal of Endodontics*, 44(2), pp. 250–255. doi:10.1016/j.joen.2017.09.010.
10. Phothichailert, S. *et al.* (2023) 'Effects of ethylenediaminetetraacetic acid on stem cells from the apical papilla: In vitro study', *Journal of Dental Sciences*, 18(1), pp. 50–56. doi:10.1016/j.jds.2022.07.014.
11. Kim, S.G. *et al.* (2018) 'Regenerative Endodontics: A comprehensive review', *International Endodontic Journal*, 51(12), pp. 1367–1388. doi:10.1111/iej.12954.
12. 'AAE position statement: Scope of Endodontics: Regenerative endodontics' (2013) *Journal of Endodontics*, 39(4), pp. 561–563. doi:10.1016/s0099-2399(13)00231-8.
13. Jiang X, Liu H, Peng C. Clinical and Radiographic Assessment of the Efficacy of a Collagen Membrane in Regenerative Endodontics: A Randomized, Controlled Clinical Trial. J Endod. 2017 Sep;43(9):1465-1471. doi: 10.1016/j.joen.2017.04.011. Epub 2017 Jul 14. PMID: 28716215.
14. Staboseviciute M, Vasiliauskaite N, Drukteinis S, Martens L, Rajasekharan S. Discoloration Potential of Biodentine: A Systematic Review. Materials (Basel). 2021 Nov 14;14(22):6861. doi: 10.3390/ma14226861. PMID: 34832263; PMCID: PMC8619462.
15. Nabeel, M. *et al.* (2024) 'Biocompatibility of mineral trioxide aggregate and biodentine as root-end filling materials: An in vivo study', *Scientific Reports*, 14(1). doi:10.1038/s41598-024-53872-w.
16. Abu Zeid ST, Alamoudi RA, Alothmani OS, Mokeem Saleh AA, Siddiqui AY. A Prospective Study of Long-Term Regenerative Endodontics Outcomes of Necrotic Immature Permanent Teeth: An 8-Year Follow-Up. Healthcare (Basel). 2021 Dec 2;9(12):1670. doi: 10.3390/healthcare9121670. PMID: 34946396; PMCID: PMC8701996.
17. El-Kateb, N.M., Abdallah, A.M. and ElBackly, R.N. (2024) 'Correlation between pulp sensibility and magnetic resonance signal intensity following regenerative endodontic procedures in mature necrotic teeth- a retrospective cohort study', *BMC Oral Health*, 24(1). doi:10.1186/s12903-024-04095-y.

GE092 | USE OF A NEW BRAND ONE-FIL PUTTY AS BIOCERAMICS FOR PERFORATION ON A 1.4

Elena Ayllon[1], Fernando durán sindreu[2],Francesc abella[3],Anais Ramirez-Sebastia[4]
[1]Lifelong learning master's Degree Universitate international da Catalunya,[2]DDS PhD,[3]DDS PhD,[4]DDS PhD

AIM Evaluate the efficacity and healing of a new bioceramics one-fil putty as bioceramics for a perforation on a 1.4

Introduction

Perforations occurring during open access present a significant challenge, as they can severely compromise treatment outcomes if not managed properly. The introduction of bioceramic putty materials, such as One-Fil Putty, has revolutionized endodontic repair due to their bioactivity, ease of application, and sealing capabilities. This case study illustrates the successful use of One-Fil Putty in managing a perforation, highlighting its clinical advantages and effectiveness in preserving the tooth structure and ensuring optimal healing.

Clinical Cas

A 25-year-old female patient presented with spontaneous pain in tooth 1.4. Diagnosis revealed irreversible pulpitis with symptomatic apical periodontitis caused by caries, necessitating root canal treatment followed by a crown. During open access, a perforation occurred. Treatment was halted, and after one week, the patient returned with no pain or swelling.

The perforation was sealed using One Fil Putty following a standard protocol: isolation, irrigation, material application, condensation, and moisture control. The prognosis was favorable due to the small perforation size, timely intervention, and accessible location. A follow up after 3 month were made, she continues without pain on percussion test.











Follow up after 3 months :



Discussion

One Fil Putty is a premixed bioceramic cement composed of tricalcium silicate, zirconium oxide, and hydrophilic polymers. It requires moisture for activation and has a setting time of 130 minutes, shorter than traditional MTA.

This material has high radiopacity (5.82 ± 0.50 mmAl) for better radiographic visibility and an alkaline pH, supporting antibacterial effects and mineralization. Its microhardness (35.8 ± 3.6 VHN), lower than MTA, is sufficient to provide stability in clinical applications while maintaining adequate sealing properties.

Clinically, One Fil Putty is effective for perforation repair, pulp capping, and regenerative endodontics. Its easy handling and biocompatibility make it a strong alternative to MTA. In this case, early intervention and material selection led to a successful outcome after 3 month follow up. A 6 month ,1 year follow up is needed to confirm long-term efficacy.

Conclusion

One Fil Putty proved to be a reliable material for managing root perforations, ensuring effective sealing and biocompatibility. Its ease of use and favorable properties make it a valuable choice for modern endodontic treatments.

Reference : Song M, Lee SM, Bang JY, Kim RH, Kwak SW, Kim HC. Chemomechanical Properties and Biocompatibility of Various Premixed Putty-type Bioactive Ceramic Cements. J Endod. 2023 Dec;49(12):1713-1721. doi: 10.1016/j.joen.2023.09.005. Epub 2023 Sep 19. PMID: 37734586.
Clauder T. Present status and future directions - Managing perforations. Int Endod J. 2022 Oct;55 Suppl 4:872-891. doi: 10.1111/iej.13748. Epub 2022 Apr 28. PMID: 35403711.

GE093 | IN VITRO EVALUATION OF THE SEALING ABILITY OF NEOMTA AND ENDOSEQUENCE ROOT REPAIR MATERIAL PUTTY IN RETROGRADE FILLING

A.G. CARRILLO VARGUEZ [1], L.E. CARRILLO VARGUEZ [2], D.Y. MAGANA MANCILLAS [3], M.A. RAMIREZ HERRERA [4], E. VELAZQUEZ RODRIGUEZ [5], L.D. ACOSTA TORRES VERY [6], O. GONZALEZ CASTILLO [7], A. CASTELLANOS GONZALEZ [8]

[1] *AUTONOMOUS UNIVERSITY OF BAJA CALIFORNIA, TIJUANA, MEXICO*
[2] *AUTONOMOUS UNIVERSITY OF BAJA CALIFORNIA, TIJUANA, MEXICO*
[3] *AUTONOMOUS UNIVERSITY OF BAJA CALIFORNIA, TIJUANA, MEXICO*
[4] *AUTONOMOUS UNIVERSITY OF BAJA CALIFORNIA, TIJUANA, MEXICO*
[5] *AUTONOMOUS UNIVERSITY OF BAJA CALIFORNIA, TIJUANA, MEXICO*
[6] *AUTONOMOUS UNIVERSITY OF BAJA CALIFORNIA, TIJUANA, MEXICO*
[7] *AUTONOMOUS UNIVERSITY OF BAJA CALIFORNIA, TIJUANA, MEXICO*
[8] *AUTONOMOUS UNIVERSITY OF BAJA CALIFORNIA, TIJUANA, MEXICO*

AIM: To compare the sealing ability of the bioceramic cements NeoMTA and Endosequence Root Repair Material Putty (ERRM) in retrograde obturation by assessing microleakage and interfacial adaptation.

Methodology: A total of 50 extracted premolars were standardized and subjected to apicoectomy followed by retrograde cavity preparation. The specimens were randomly divided into two groups and obturated with either NeoMTA or ERRM. The sealing ability was assessed through a 1% methylene blue dye penetration test, followed by stereomicroscopic and scanning electron microscopy (SEM) analysis of the cement-dentin interface. The extent of microleakage was measured using ImageJ software. The statistical analysis was performed using ANOVA test to compare microleakage values between the two groups, with a p-value < 0.05 indicating statistical significance.

Results: NeoMTA demonstrated significantly lower microleakage compared to ERRM ($p < 0.05$), suggesting superior sealing ability. SEM-EDX analysis revealed a more homogeneous interface between NeoMTA and dentin, with fewer voids and gaps compared to ERRM.

Conclusions (mandatory): NeoMTA exhibited better adaptation and sealing performance than ERRM, making it a promising material for retrograde obturation in endodontic microsurgery. Further research is needed to validate these results under clinical conditions.

Acknowledgements (optional): This research was supported by a CONACYT grant and conducted in collaboration with the Instituto Tecnológico de Tijuana.

GE094 | Managing a Failed Root Canal Treatment in Type II Dens Invaginatus: A Retreatment Approach

*Dr.Sinem Buse OZVATAN *Asst.Prof.Feyza OZDEMIR KISACIK
Süleyman Demirel University Faculty of Dentistry, Department of Endodontics, Isparta, Turkey

Aim: This case report aims to describe the non-surgical retreatment of a maxillary lateral incisor with Type II Dens Invaginatus (DI), focusing on the removal of a previous bioceramic filling material and re-establishing an effective root canal seal.

Introduction: DI (dens in dente), is a developmental malformation caused by the invasion of the dental papilla by the enamel organ before the calcification of the tissue. According to Oehlers' classification, Type II DI extends beyond the enamel-cementum junction, reaching the dental pulp but without communication with the periodontal ligament. In cases where the primary treatment fails, retreatment poses an additional challenge due to altered canal anatomy and previous filling materials.

Case Report: A 30-year-old, systemically healthy male patient referred to our clinic with spontaneous pain in upper left lateral incisor. According to clinical examination, percussion and palpation responses were positive. Cone beam computed tomography (CBCT) demonstrated Type II DI (Fig.1a,1b,1c,1d). At the first appointment, under rubber-dam isolation, the bioceramic material in the invaginated canal was removed using an ultrasonic tip (Woodpecker, DTE s6) and reintegrated with the remaining root canal anatomy. The working length was determined radiographically and with an electronic apex locator (Fig.2). The canals were instrumented, disinfected, and medicated with Calciplus (Imicryl, USA). After two weeks at the second appointment, the root canal was obturated using MTA (MTA Plus; Prevest Dentpro Limited, Jammu City, India) (Fig.3), and restored with composite resin and zirconia crown prosthesis. There was no clinical symptom. Clinical/radiographic follow-up continues.


Fig.3


Preoperative radiograph


Postoperative photograph


Postoperative radiograph

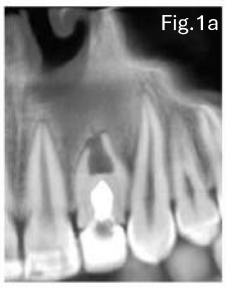
Fig.1a


Fig.1b

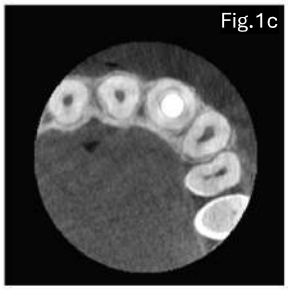
Fig.1c

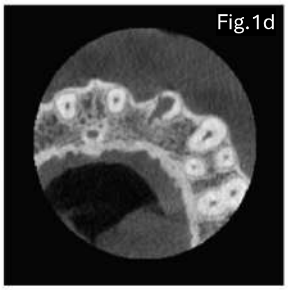
Fig.1d


Fig.2

Discussion: This case highlights the importance of CBCT in diagnosing complex canal configurations and guiding retreatment strategies. Ultrasonic system removal of bioceramic filling materials allowed for thorough reintegration of the canal system, ensuring proper disinfection and obturation.

Clinical Relevance : The successful retreatment of Type II DI with MTA obturation emphasizes the feasibility of non-surgical approaches. In some cases, reintegration can be performed between the invaginated area and the original canal system to obtain better cleaning efficiency.

REFERENCES
1.L. Chen, Y. Li, H. Wang Investigation of dens invaginatus in a Chinese subpopulation using Cone-beam computed tomography Oral Diseases, 27 (2021), pp. 1755-1760
2.Galli, M., Rossi, G., & Mancini, L. (2023). Successful nonsurgical treatment of type II dens invaginatus with five root canals using a self-adjusting file: A case report. Journal of Endodontics, 49(3), 451-457
3.Sübay, R. K., & Çolak, M. (2021). Bioceramic materials in endodontics: A . Journal of Endodontics, 47(9), 1365-1374.

GE095 | EVALUATION OF THE EFFICACY OF SILVER NANOPARTICLES SYNTHESIZED FROM RED CABBAGE EXTRACT ON VARIOUS ENDODONTIC PATHOGENSIN OUR STUDY, WE AIMED TO COMPARE THE ANTIBACTERIAL ACTIVITIES OF SILVER NANOPART

Y. USTUN [1], T. ASLAN [1], N. ILDIZ [2], I. OCSOY [3], O. KAHRAMAN [1]

[1] *Erciyes University, Faculty Of Dentistry, Endodontics Department, Kayseri, Turkey*
[2] *Bandirma Onyedi Eylul University, Health Services Vocational School, Balikesir, Turkey*
[3] *Erciyes University, Faculty Of Pharmacy, Kayseri, Turkey*

AIM: This study aimed to compare the antibacterial activities of Silver Nanoparticle (AgNP) solution obtained from red cabbage extract by biological synthesis on Enterococcus faecalis and Candida albicans microorganisms with irrigation solutions commonly used in endodontics.

Methodology: Eighty-eight freshly extracted single-rooted and single-canal human teeth were used. Three horizontal sections from the root middle third of each tooth were cut under water cooling, resulting in 264 sections. After removing the smear layer and sterilizing, sections were divided into two groups. One group formed a biofilm layer with E. faecalis, and the other with C. albicans. AgNPs (RC-AgNP) were synthesized using red cabbage extracts. Samples were divided into groups (n:26) and exposed to five different irrigation solutions: AgNP(PVP), RC-AgNP, 2% CHX, 5.25% NaOCl, and sterile saline (SS). The infected dentin discs were stained and visualized with a confocal laser microscope (CFLM).
Antibacterial tests, including minimum inhibition concentration (MIC) and disc diffusion (DD), were conducted.

Results: The results showed that the most effective solutions for E. faecalis and C. albicans were 5.25% NaOCl, RC-AgNP, CHX, AgNP, and SS, respectively. MIC results indicated that the most effective solutions on E. faecalis were CHX, 5.25% NaOCl, RC-AgNP, AgNP, and SS, respectively. Significant differences were observed in all groups ($P<0.05$), except between RC-AgNP and CHX ($P>0.05$).
When CFLM results were evaluated, 5.25% NaOCl was the most effective solution for both E. faecalis and C. albicans biofilms ($p<0.05$), followed by RC-AgNP, AgNP, CHX, and SS, respectively ($p<0.05$).

Conclusions (mandatory): In conclusion, RC-AgNP solution produced from red cabbage had stronger antimicrobial activity than AgNP solution, suggesting it could be an alternative in endodontic treatment.

GE096 | EXTERNAL CERVICAL RESORPTION: A CASE REPORT

Baris Urun PhD, T. Mert Gundogdu PhD, Z. Gokce Urun

AIM: This case report describes the treatment of external cervical resorption (ECR) of an upper canine and first upper premolar. Root canal treatment was performed on the involved teeth and the granulomatous tissue of the affected teeth was removed, the resorption area was repaired with biodentin.

INTRODUCTION: External cervical resorption consists of the loss of mineralized tissue (i.e., cementum and dentin) as a result of odontoclastic action (Patel & Ford 2007). Root resorption in the permanent dentition is a pathologic event; if left untreated, it may result in premature loss of the affected teeth. Correct diagnosis, location, and degree of tissue destruction, and treatment method play an important role in the management of these cases.

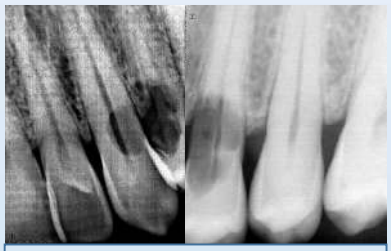

Fig. 1: preoperative radiograps

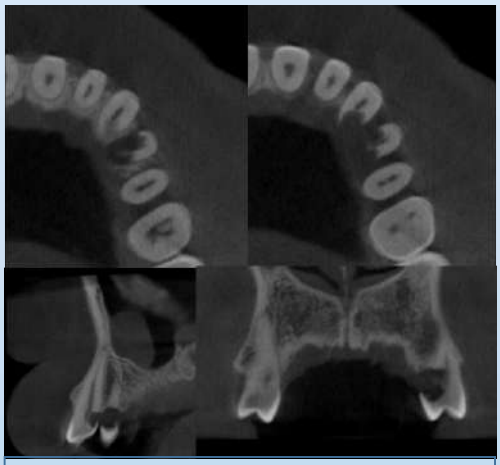

Fig. 2: preoperative CBCT



Fig. 3: postoperative radiographs

CASE PRESENTATION: A 31-year-old male patient, a non-smoker and healthy, reports that he suffers from bruxism. External cervical resorption in the maxillary left canine and first premolar was discovered during a routine radiographic examination. Cone-beam computed tomography (CBCT) images confirmed the presence of external cervical root resorption on palatinal surfaces of the roots. According to the Heithersay classification (Heithersay 1999), this lesion was considered to be Class 2 in canine and class 3 in premolar. On clinical examination, the patient had no complaints. Upper first premolar was slightly sensitive both percussion and palpation but without mobility. No symptoms found in the canine. Both teeth had no caries, previous filling, crack, anormal color or primer contact. There was no trauma history. It was decided to perform root canal treatment and surgical treatment. Single visit root canal treatment was applied to the canine. But excessive bleeding was noted in the premolar. Before surgery, tapered gutta-percha was placed into the canal and access cavity was sealed. An intrasulcular incision from lateral incisor to first molar was performed to expose the resorption cavity from the palatal aspect. Granulomatous tissue and undermined dentin were removed from the resorptive area with a bur in a high speed handpiece and checked with hand excavator. This area was filled with Biodentine and the flap was repositioned. Ten days later, the root canal cleaning and shaping were completed and the canal was obturated.

Discussion: ECR can begin and progress asymptomatically without the presence of any of the known etiological factors. If there is no pulpal involvement, endodontic treatment should not be applied. But in this case premolar required root canal treatment due to perforation of root canal wall. Although there was no pulpal perforation in canine, root canal treatment was performed due to the small distance between the resorption lesion and the root canal wall. CBCT is an important step in confirming the true extent of resorption and planning surgical treatment. The main goal of this treatment is to completely remove the resorptive tissue and seal the affected area. There are different tricalcium silicate-based materials used in resorption treatment, such as MTA, but since our operation area was in the cervical region and wanted to prevent discoloration, we preferred Biodentin. Biodentin is the current gold standard material in external resorption treatments because its superior physical properties, better handling, increased biocompatibility and wide range of clinical applications (Malkondu Kazandağ et al. 2014). After the treatment, patient was asymptomatic and the radiographic examinations showed no signs of periradicular pathology during follow-up period.

CLINICAL RELEVANCE: Successful management of ECR and long-term retention of tooth depends on early diagnosis, appropriate case selection and proper restorative material. Biodentine can be used in these cases because of its excellent characteristics. Following treatment, long-term monitoring of restored lesions, accompanied by regular clinical and radiographic evaluations, is essential for long term success.

REFERENCES:

Patel, S., & Ford, T. P. (2007). Is the resorption external or internal?. *Dental update*, *34*(4), 218-229.

Heithersay, G. S. (1999). Clinical, radiologic, and histopathologic features of invasive cervical resorption. *Quintessence International*, *30*(1).

Malkondu, Ö., Kazandağ, M. K., & Kazazoğlu, E. (2014). A review on biodentine, a contemporary dentine replacement and repair material. BioMed research international, 2014(1), 160951.

GE097 | ROOT CANAL TREATMENT OF TOOTH 2.1. HANDLING OF AN OBLITERATED CASE WITH GUIDED ENDODONTICS.

M. GRANONE [1], R. ESTÉVEZ LUAÑA [1], A.J. CONDE VILLAR [1], J.M. KOURY [1], R. PÉREZ ALFAYATE [1]

[1] *Universidad Europea de Madrid. Department of Clinical Dentistry. Postgraduate of Endodontics., MADRID, SPAIN*

AIM: To perform root canal treatment on tooth 2.1 using a static guide for enhanced accuracy and conservatism.

Methodology: Pulp canal obliteration presents a significant challenge in endodontic practice, often requiring the removal of substantial tooth structure in an effort to locate the canal. This can lead to complications such as perforations or deviations, ultimately weakening the tooth and reducing its lifespan. The advent of guided endodontics has provided a predictable and safe method for managing such cases, minimizing chair time and the likelihood of procedural complications.
A patient presented with severe pain during mastication in the anterior region, accompanied by extraoral edema that impeded buccal exploration. Clinical evaluation revealed intense pain on vertical percussion and palpation of tooth 2.1. Radiographic examination identified pulp canal obliteration in teeth 1.1, 2.1, and 2.2, with a periapical radiolucency evident in 2.1. The diagnosis was established as pulpal necrosis with symptomatic apical periodontitis. Accordingly, the recommended treatment was a static guide-assisted root canal treatment of tooth 2.1. At the 10-month revision the patient is asymptomatic and formation of bone is appreciated in the periapical area.

Results: • Technological advancements in guided endodontics enhance predictability, precision, and conservation of tooth structure.
• The use of a static guide facilitates more efficient canal shaping and disinfection, which is critical for long-term treatment success and the resolution of apical periodontitis.
• Although guided techniques reduce the reliance on operator experience, they require the integration of digital resources and are associated with increased treatment costs.

GE098

THE MULTIDISCIPLINARY APPROACH OF A MANDIBULAR MOLAR TOOTH WITH PERIO-ENDO LESION

Research Assistant Kübra Koç Yılmaz*, Research Assistant Buğra Varol**

(Süleyman Demirel University, Faculty Of Dentistry, Isparta, Turkey)

Aim

The aim of this case is to show how combined endodontic-periodontal lesions are treated in a multidisciplinary manner.

Introduction

Endo-perio lesions arise from the interrelationship between endodontic and periodontal infections, often leading to tooth mobility, abscess formation and potential tooth loss (1).

Case Presentation

A 57-year-old healthy female patient was referred to our Endodontics department with the complaint of abscess in her right lower molar. In the clinical and radiographic examination, there was an intraoral abscess in #47, percussion and palpation was positive. Pulp sensivity test was negative.There was a periodontal pocket 10 mm in buccal aspect. In radiograph, tooth had periapical index classification (PAI) 5 lesion. It was diagnosed endo-perio combined lesion.
In the first appointment, abscess drainage was obtained. After the working lenght determination, mechanical enstrumentation was performed using rubber dam isolation. The root canal was irrigated using 2.5% sodium hypochlorite (NAOCl), 17% Ethylenediaminetetraacetic acid (EDTA) and saline, subsequently, an intracanal medication (Calciplus, Imicryl, USA) was performed. After two weeks, in the second appointment, intracanal medicament was removed and final irrigation was activated with EDDY (VDW, Germany). The root canals were obturated using cold lateral condensation gutta-percha technique and epoxy resin-based root canal sealer (Endoplus,President Dental,Germany).The tooth was restored with composite resin (Dynamic Plus, President Dental, Germany). In the periodontology department, scaling and root planing (SRP) and curretage treatment were performed. After 4 weeks in follow-up session, periodontal pocket was healthy and tooth was asymptomatic.



Pre-op. intraoral image



Pre-op. periapical radiograph



One month follow-up periapical radiograph



Follow-up intraoral image

Discussion

In clinical practice, diagnosing an actual endo-periodontal lesion may seem complicated. With a detailed anamnesis, examination and multidisciplinary approach, we can improve the success and prognosis of treatment.

Clinical Relevance

At present, there is no consensual clinical protocol on the management of an actual combined endo-perio lesion. Due to the variation of lesions, therapeutic decisions would be clinical case-by-case.

References

1. Rotstein, I. & Simon, J. H. Diagnosis, prognosis and decision-making in the treatment of combined periodontal-endodontic lesions. *Periodontol 2000* 34, 165–203 (2004).

GE100 | BOND STRENGTH OF PREMIXED CALCIUM SILICATE-BASED CEMENT AFTER EXPOSURE TO DIFFERENT IRRIGATION PROTOCOLS

A. NIKITOVIC [1], D. PESIC [1], I. MELIH [1], V. KOLAK [1], M. LALOVIC [1], S. AVRAMOV [1]

[1] *Faculty of Stomatology in Pancevo, Serbia, Pancevo, SERBIA*

AIM: The aim of this study was to assess and compare the effect of three different irrigation protocols on the push-out bond strength of premixed calcium silicate-based cement.

Methodology: Twenty-four dentin discs (1 mm thick) were perforated with 1.2 mm diameter fissure bur (Dentsply, Switzerland). Three perforations were made on each disc at 2mm distance. All perforations were filled with tested material Well-Root PT (WRPT; Vericom Co., Korea). For the production of an acrylic irrigation model three extracted maxillary lateral incisors were used. The teeth were cut at cementoenamel junction, the root canals instrumented with BioRaCe system (FKG, Switzerland) and then immersed in acrylate (Simgal R, Serbia). Each dentin disc was placed on wax cube between the teeth and then subjected to an irrigation procedure. The specimens were assigned into four subgroups (n=18) according to the irrigation method used. First group was control, without irrigation. The next three groups were irrigated with 2% NaOCl + 17% EDTA: needle irrigation; passive ultrasonic irrigation (PUI) (Piezon® Master, Switzerland); laser-activated irrigation (LAI) (AT Fidelis, Fotona, Slovenia). A push-out bond strength test was performed, and the data were analyzed statistically using Kruskal-Wallis nonparametric analysis of variance. The significance was considered at $P < 0.05$.

Results: The highest mean push-out bond strength (16,466±3,444 MPa) was measured after exposure to laser-activated irrigation while the lowest was after exposure to needle irrigation (12,548±4,823 MPa). Compared to the control group PUI and needle irrigation reduced while LAI increased the bond strength of the material. Based on the Kruskal-Wallis analysis there were no significant difference in the bond strength between all groups ($P > 0.05$).

Conclusions (mandatory): The push-out bond strength of Well-Root PT was not adversely affected by irrigation. Applied irrigation protocols presented similar impact concerning the push-out bond strength of Well-Root PT.

GE101 | MULTIDISCIPLINARY MANAGEMENT OF TRAUMATIZED TOOTH WITH COMPLICATED CROWN FRACTURE AND CALCIFIC METAMORPHOSIS: A CASE REPORT

M. BULBUL [1], A. BOLUK [1], M.B. BURGAZLI [1]

[1] *Ankara University Dentistry Faculty Department of Endodontics, Ankara*

AIM: This presentation highlights an endodontically driven multidisciplinary approach for the preservation of traumatized teeth with complicated crown fractures and calcific metamorphosis, aiming to minimize the need for extraction.

Methodology: An 18-year-old female experienced trauma at age 10, resulting in a complicated crown fracture of tooth#11. The tooth was splinted for seven years. One year post-splint removal, the tooth exhibited mobility. Given the presence of calcific metamorphosis and the patient's aesthetic concerns, extraction was considered a last resort.

A sulcular flap was elevated for fracture assessment. The fractured coronal segment was removed and disinfected with saline. Piezosegment instrumentation facilitated the removal of calcified tissue and regaining access to the root canal. The canal was prepared using Revo-S(SC2) for initial shaping and Protaper-Gold-F3 for apical enlargement. The irrigation protocol included 5.25% NaOCl with passive ultrasonic activation, 17% EDTA for smear layer removal, and saline for final irrigation. Obturation was completed using F3 gutta-percha and AH-Plus sealer.

For orthodontic extrusion, space was created within the obturation using a Revo-S(SC1) file. An orthodontic chain was bonded at a 90-degree-angle to a wire, stabilized with a lingual splint. The coronal fragment was repositioned and bonded using a total-etch adhesive system, followed by flap closure. Occlusal equilibration was performed using glass-ionomer-cement on teeth.

One month later, the patient exhibited significant improvement in the apical lesion, despite inadequate orthodontic extrusion. Minimal decreases were observed in bone loss and the periodontal pocket between teeth#11 and #21. Curettage, followed by bone grafting and fiber post placement, was planned. The patient was scheduled for a 3-month follow-up appointment.

Results: Multidisciplinary-Approaches:Multidisciplinary methods can save teeth likely to be extracted.

Collaborative-Treatment:Multidisciplinary thinking can save many teeth without extraction.

Interdisciplinary-Contributions:Extraction decisions shouldn't rely solely on the endodontic department.

Future-of-Treatments:Promising future, further research needed.

Preservation-Potential:Innovative approaches can save teeth even if extraction seems the only option.

GE102 | SHOULD ALL APICECTOMY-ASSOCIATED PATHOLOGICAL TISSUE BE SUBMITTED FOR HISTOLOGICAL EXAMINATION?: A RESTROSPECTIVE STUDY

F. RODRIGUES [1], M. PATEL [1], H. COTTOM [1]

[1] *The Royal London Hospital, Barts NHS Trust, London, UNITED KINGDOM*

AIM: To assess whether local apicectomy protocol aligns with Royal College of Surgeons of England, Periradicular Surgery guidelines, regarding periapical tissue submission for histological analysis. To evaluate histological findings and determine if all apicectomy-associated tissue requires submission.

Methodology: This is a retrospective study of 108 patients who were electronically coded as having an apicectomy, within the Royal London Dental Hospital, over a 12-year period. The apicectomy coding assumes a surgical procedure was completed by the Endodontic or Oral Surgery department, with or without submission of pathological apical tissue for histological analysis by Oral & Maxillofacial Pathologists. Data was acquired from paper-based and electronic patient records records. Incorrectly coded procedures formed the exclusion criteria. The following parameters were recorded for each patient: patient age, gender, associated tooth, tissue submission status, and histological diagnosis of submitted tissue.

Results: After excluding 12 incorrectly coded cases, 96 patients remained (mean age 42.7, 50 females). Tissue was submitted in 46% (n = 44) of cases, with periapical granuloma (n = 20) and radicular cysts (n = 17) being the most common findings. The remaining diagnoses included granulation tissue (n = 4), periapical scars (n = 2), and a perio-endo lesion (n = 1), all benign.
In 54% (n = 52) of cases without tissue submission, 37 cases mentioned “removal” or “curettage” of tissue, without specifying tissue size or disposition. Four cases cited insufficient tissue. Three cases noted tissue submission, though histology reports were missing for two and one was accidentally discarded during a medical emergency. Eight cases lacked any mention of tissue or histopathology consideration.

Conclusions (mandatory): The local protocol does not mandate histological analysis of apical tissue. Submitted specimens were benign and did not affect further clinical management. Protocol revision should ensure selective tissue submission based on strong clinical and radiographic suspicion of non-benign or unusual pathology.

GE103 | Management of Intracanal Separated Instruments: Case Series

Assistant Professor Meltem Sümbüllü
Department of Endodontics, Faculty of Dentistry, Atatürk University, Erzurum, Türkiye

Introduction The presence of seperated endodontic instruments within the root canal system has a negative prognostic effect on orthograde endodontic treatment since they hinder the cleaning and shaping of the apical root canal.

The **aim** of this case series is to present the retrieval of seperated endodontic instruments from the root canal using various techniques.

Instrument retrieval using ultrasonics:

Case 1

- 26 years old male
- Tooth #16
- Seperated endodontic files at apical third
- Separated instruments were removed using an ultrasonic tip.



Thin ultrasonic tip is placed in the space between the seperated instrument and the inner wall. Loosening of the instrument is observed.

Case 2

- 42 years old male
- Tooth #21
- Seperated endodontic file at apical third
- Separated instrument was removed using an ultrasonic tip.

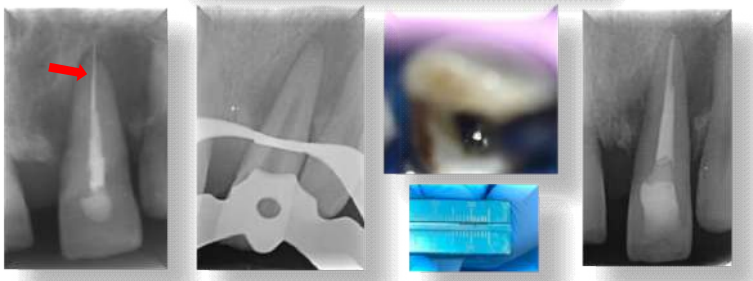

➢ Instrument retrieval using the loop system

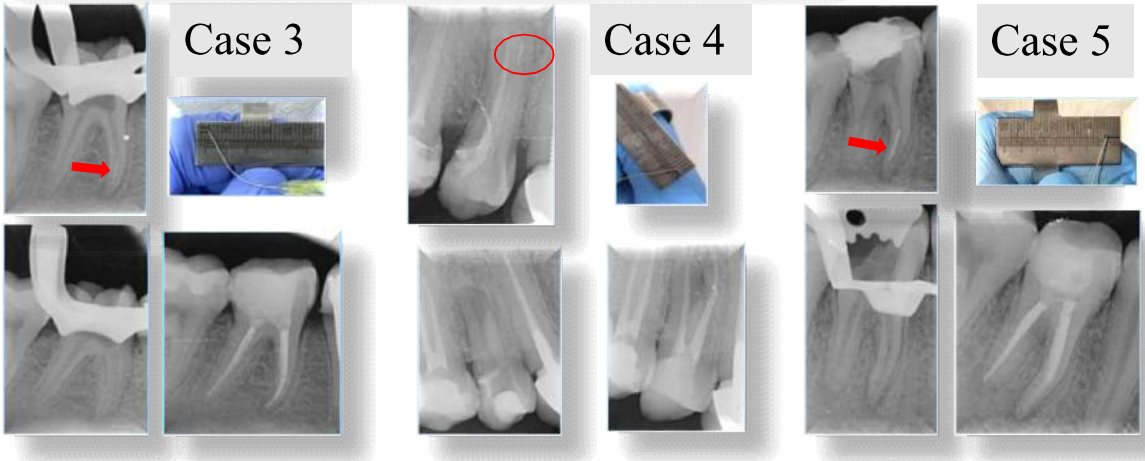

Loop is placed over the seperated instrument and tightened around it. Loop holding the seperated instrument is pulled out of the canal in several directions.

Case 3 to 5

- 42 years old male, tooth #36 (Case 3)
- 22 years old female, tooth #14 (Case 4)
- 35 years old female, tooth #36
- (Case 5)
- In each of the three cases, the separated instruments were positioned within the apical third of the root canal
- Separated instruments were removed using an ultrasonic tip and loop system.

➢ Instrument retrieval using the microtube technique

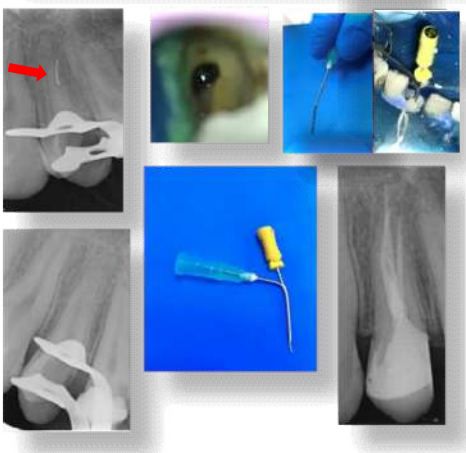

This technique ensures a secure mechanical interlocking between the seperated instrument, the tube, and the Hedström file.

Case 6

- 19 years old female
- Tooth #24
- Seperated endodontic files at apical third
- Separated instrument was removed using an ultrasonic tip and microtube technique.

Discussion

In this case report, separated instruments were removed using three different techniques. The outcome of separated instrument retrieval is significantly affected by multiple variables, such as fragment visibility, its dimensional characteristics, and the selected retrieval technique (Terauchi et al., 2022). Mechanical methods—particularly those involving ultrasonic systems—are associated with higher success rates, minimally invasive canal preparation, and quicker retrieval times (Terauchi et al., 2021).

Seperated instrument removal should be performed with minimal damage to the tooth structure and surrounding tissues. As the length of the separated fragment increases, retrieval becomes increasingly challenging. In general, ultrasonic systems are effective for removing instruments shorter than 5 mm. However, for fragments exceeding 5 mm in length, the microtube or loop techniques may be preferred. Moreover, when the seperated instrument is not directly visible, the use of a dental operating microscope is highly recommended.

Conclusion

Seperated instruments are among the common complications encountered during root canal treatment. Ultrasonics, loop system and microtube techniques are considered effective methods for the retrieval of seperated instruments from the root canal system.

Terauchi, Y., Sexton, C., Bakland, L.K. & Bogen, G. (2021) Factors affecting the removal time of separated instruments. Journal of Endodontics, 47, 1245–1252
Terauchi Y, Ali WT,Abielhassan MM. Present status and futuredirections: Removal of fractured instruments.International Endodontic Journal, 55(Suppl. 3),685–709.

Clinical Relevance: The retrieval of a seperated instrument can be achieved through the selection of the appropriate technique and the clinician's experience. Ultrasonic tips, the loop technique, and the microtube technique are all effective methods for the removal of seperated instruments from the root canal.

GE105 | EXTENSIVE INTERNAL ROOT RESORPTION IN MULTIPLE TEETH FOLLOWING ORTHODONTIC TREATMENT

R. ZANCAN [1], A. AL-TAIE [1]

[1] *University of Leeds, Leeds, UNITED KINGDOM*
[2] *University of Leeds, Leeds, UNITED KINGDOM*

Aim: This case underscores the importance of implementing regular patient follow- ups after orthodontic treatment for the earlier diagnosis of internal root resorption (IRR) of teeth.

Introduction: IRR is the progressive destruction of intraradicular dentin and dentinal tubules along the canal walls due to odontoclastic activities. Although rare and not fully understood, suggested etiological factors include infection, trauma to the pulp tissue, and orthodontic treatment.

Case presentation: A 46-year-old male was referred to the consultant clinics due to concerns regarding IRR affecting multiple teeth. The condition was asymptomatic and detected through routine radiographic examination. The patient reported that he used orthodontic fixed braces for approximately 12 months during his childhood. During treatment, the impacted maxillary canine (UR3) was orthodontically brought down. There was no associated history of dental trauma to the affected teeth and no family history of systemic or autoimmune diseases. A Cone Beam CT (CBCT) scan showed mainly internal and some external resorption extending to the mid-third of the root in UR3, LR3, and LR4. UL4 exhibited extensive internal resorption at the mid-third of the palatal root, with perforation of the palatal root surface. No apical pathology was observed, and all teeth, except UL3, responded normally to electric pulp and cold tests.

Discussion: It is plausible that orthodontic treatment initiated the resorptive process in this patient. The CBCT enhanced diagnostic capabilities by revealing the extent of mineralized tissue damage. There is a poor prognosis for UR3, UL4, LR3 and LR4 due to weakening of the remaining tooth structure, increasing the risk of fracture. Therapeutically, this condition represents a clinical challenge and normally requires a combined endodontic and surgical focus.
Clinical relevance: These findings highlight the importance of regular monitoring of patients with a history of orthodontic treatment to identify and manage potential IRR early, thereby improving the teeth's prognosis.

GE108 | EXTERNAL ROOT RESORPTION TREATMENT OF TEETH WITH DIFFERENT ETIOLOGICAL FACTORS USING MTA: 2 CASE REPORTS

Semih TOYKAR[1] , Elif AYKIN[1], M. Murat KOÇAK[1]*
Zonguldak Bülent Ecevit University Faculty of Dentistry Department of Endodontics

AIM

This case report demonstrates the treatment of root resorption of two teeth caused by different factors with a biocompatible material.

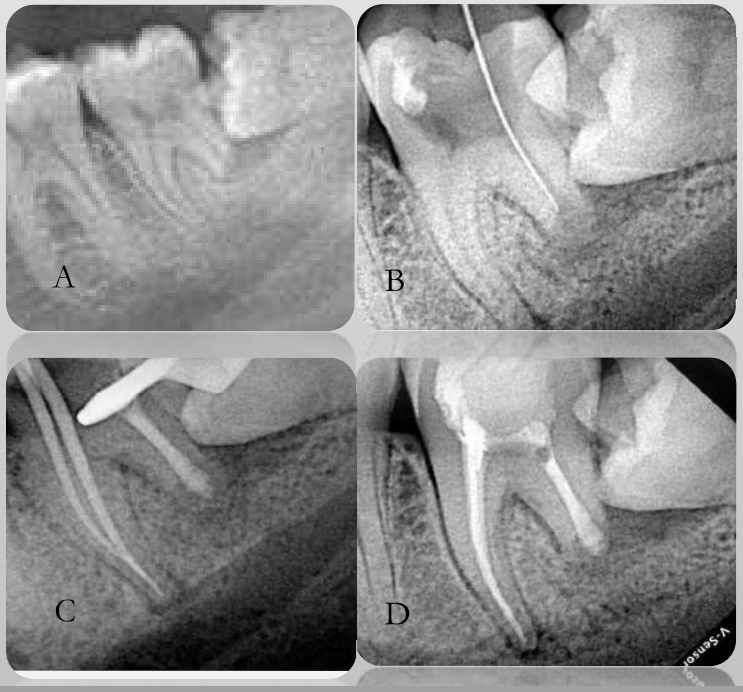

INTRODUCTION

External root resorption (ERR) is defined as the loss of mineralized dental tissue, such as cementum, dentin, and even alveolar bone, due to various factors leading to alterations in osteoclastic activity.1 Various factors such as, inflammation or infection and pressure caused by impacted teeth, masses (tumors or cysts), or orthodontic movement may cause resorption. Successful management of root resorption in the adult dentition depends on clinical and radiographic examination, which allows early detection and accurate diagnosis.

CASE 1;

A 28-year-old male patient, systemically healthy, was referred to our clinic with a complaint of pain in the lower left region. Upon clinical examination, tenderness to percussion and palpation was recorded, and a negative response was obtained to the electric pulp test in the lower left second molar(#37). Radiographic evaluation revealed an impacted lower left third molar, and resorption of the distal root of the second molar(Fig.1 A). In the first session, root canal therapy was initiated under local anesthesia and rubber dam isolation. After access cavity preparation, the mesial canals were negotiated using a #10 K-file with an apex locator, while the working length of the distal canal was determined radiographically with a #40 K-file(Fig.1 B). Preparation of the mesial canals was completed, intracanal medication with calcium hydroxide (Ca(OH)2) was applied for 4 weeks. In the second session, the tooth was asymptomatic. After removal of the temporary filling, Ca(OH)2 was removed from the root canal. Following the final irrigation, a teflon tape was placed at the orifice of the mesial canal, and the entire distal canal was filled with MTA(BioMTA,CERKAMED,Poland). The mesial canals were filled using a resin-based root canal sealer with cold lateral compaction technique(Fig.1 C,D). At the 6-month follow-up, the tooth remained asymptomatic and functional.

CASE 2;

A 22-year-old male patient, systemically healthy, was referred with a complaint of swelling in the upper left region. Clinical and radiographic examination revealed a previously performed root canal treatment on the upper left maxillary first molar(#26), with root resorption and a periapical lesion at the apex of the root. A CBCT scan was taken to assess the lesion and resorption. Retreatment was initiated. After several sessions of dressing, the root canals were dried in the final session, and the buccal canals were filled using gutta-percha and cold lateral compaction technique. The palatal canal was filled with MTA(BioMTA,CERKAMED,Poland). At the one-year follow-up, the tooth was asymptomatic, with no facial swelling or sinus tract observed. Radiographically, the lesion had completely healed.

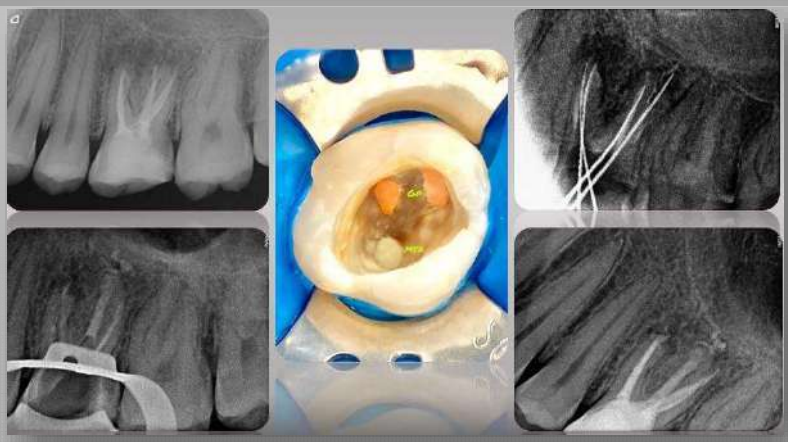

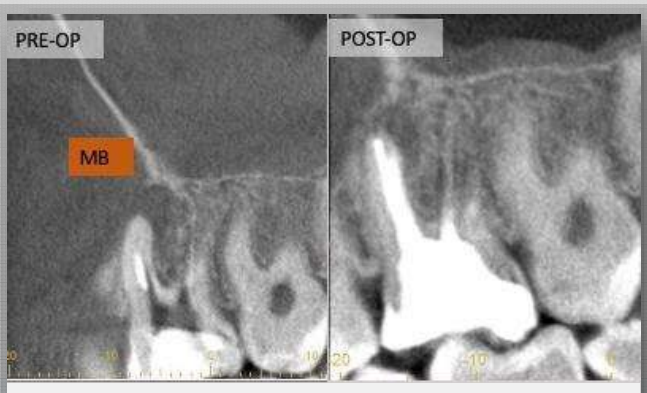

Mesiobuccal canal in sagittal section



Distal-palatinal canals in frontal section

DISCUSSION:

ERR is one of the dental diseases that can be difficult and complex to treat. Root resorption is generally asymptomatic, but clinical signs of pulpitis or apical periodontitis can be observed. In the first case, the root resorption in the second molar may be attributed to the mechanical forces arising during the eruption phase of the third molar. In the second case, inadequate endodontic treatment and a resorptive process were observed in the palatal canal. In both cases MTA was used as the filling material. The application of Ca(OH)2 as a temporary filling material increases disinfection effectiveness.

CLINICAL RELEVANCE:

CBCT imaging may be standardized for detection and size of resorptions. In the case of root canal perforation, MTA is considered to be the material of choice to seal the perforation as it is biocompatible, bioactive, and well-tolerated by periradicular tissues.

Fuss Z, Tsesis I, & Lin S. Root resorption–diagnosis, classification and treatment choices based on stimulation factors. *Dent traumatology*, 2003:*19*(4), 175-182.
Smailienė D, Trakinienė G, Beinorienė A, & Tutlienė U. (2019). Relationship between the position of impacted third molars and external root resorption of adjacent second molars: a retrospective CBCT study. *Medicina*, *55*(6), 305.

GE109 | Endodontic Treatment of a Tooth with Traumatic Horizontal Root Fracture: A Case Report

Elif Nur DINC DDS , Baran Can SAGLAM DDS,PhD,MSC
*Zonguldak Bulent Ecevit University Faculty of Dentistry Department of Endodontics

AIM:

The aim of this case report is to describe the clinical management of a tooth with a traumatic horizontal root fracture using mineral trioxide aggregate (MTA) and Biodentine.

INTRODUCTION:

Horizontal root fractures predominantly affect the permanent maxillary central incisors of 11- to 20-year-old male patients, (Caliskan 2008)(Cvek,2008)representing 0.5% to 7% of all traumatic dental injuries of permanent teeth.(Andreasen, 1994). The management of horizontal root fracture depends on the location of the fracture and mobility and the vitality of the tooth. Also the use of cone-beam computed tomography (CBCT), which provides a three dimensional assessment for precise visualization of the fracture fragments, will facilitate clinical decision-making for the clinician.

CASE PRESENTATION:

A 16-year-old female patient referred to our hospital with a complaint of dental trauma following a bicycle accident. After the initial intervention, the patient did not attend follow-up appointments. Two months after the accident, she returned to our hospital due to pain in the affected tooth; however, root canal treatment had already been performed on tooth #12 at another clinic. Clinical examination showed minimal mobility, tenderness to percussion-palpation and negative sensibility tests in tooth #11. Radiographic examination revealed horizontal root fracture in tooth #11 (fig. 1). In first appoitment the root canal filling of tooth #12 was removed and finished with calcium hydroxide dressing. The working length of the fracture line was established using a no. 80 K-file (Dentysply-Maillefer, Ballaigues) on Tooth #11 (fig 2) and finished with calcium hydroxide dressing. The teeth were splinted in a semi-rigid manner. In second appoitment the procedures were performed under split-dam isolation.(fig 3). To prevent complications from irrigant extrusion through the fracture, irrigation with 2.5% NaOCl(Microvem,Türkiye) and 17% EDTA (Septadont, Poland) were performed while using micro-suction to control its extrusion through the fracture line. Ultrasonic activation was carried out 1 mm short of the working length.Tooth #11 received a 2 mm MTA plug, allowed to set for 24 h and then back-filled with Biodentine (Septodont, St Maur-des-Fossés, France)(fig.4). For the tooth #12 the intracanal medication was eliminated with files and irrigation, and the canal was filled with gutta-percha and Adseal sealer (Meta Biomed, Cheongju, Korea). After 9 months there is no periapical lesion, pain, or percussion sensitivity was observed in the coronal fragment of tooth #11 and tooth #12. The tooth #11's mobility had significantly decreased. However, lesion formation was detected due to necrosis of the apical fragment. The patient was referred to the department of oral and maxillofacial surgery for the removal of the apical fragment.



Figure 1



Figure 2

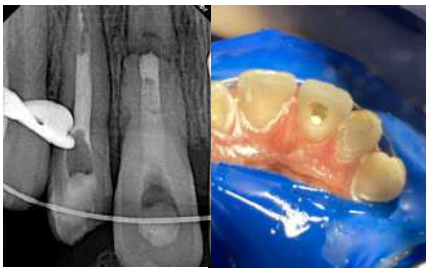

Figure 4



Figure 3



3 months follow up
Tooth #11 and #12

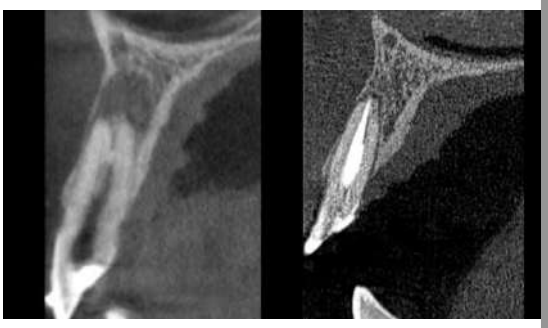

9 months follow up
tooth #12



9 months follow up
Tooth #11 and #12

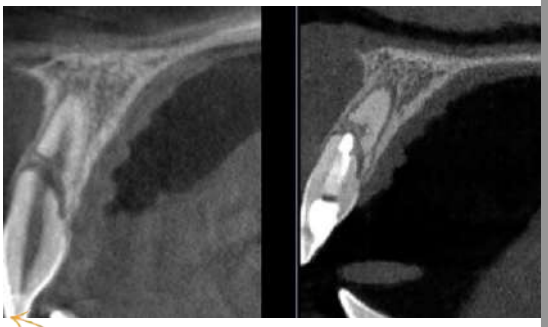

9 months follow up
tooth #11

DISCUSSIONS:

The proper diagnosis of a horizontal root fracture is difficult using conventional radiographs due the limited information available on a 2-dimensional image. Different types of healing can be observed in root-fractured teeth, including: calcific callus union; connective tissue healing; combination bone and connective tissue healing; and interposition of granulation tissue (nonhealing).(Andreasen,2004). After root canal treatment in teeth with pulp necrosis, several (Andreasen,2004)(Cvek,2008)(Cvek,2004) have shown healing of inflammation at a fracture line, predominantly (80%) by fibrous repair.

CLINICAL REVELANCE

This case demonstrates how the treatment of a horizontal root fracture using MTA and Biodentine has maintained long-term stability of the tooth, led to the resolution of symptoms and radiographic findings, and thus represents a viable treatment option for such cases.

REFERENCES
1.Caliskan MK, Pehlivan Y. Prognosis of root-fractured permanent incisors. Endod Dent Traumatol 1996;12:129-36
2.Cvek M, Tsilingaridis G, Andreasen JO. Survival of 534 incisors after intra-alveolar root fracture in patients aged 7-17 years. Dent Traumatol 2008;24:379-87.
3.Andreasen JO, Andreasen FM. Textbook and Color Atlas of Traumatic Injuries to the Teeth. 3rd ed. St. Louis, Mo: Mosby; 1994:279-311.
4. Andreasen JO, Andreasen FM, Mejàre I, Cvek M. Healing of 400 intra-alveolar root fractures. 1. Effect of pre-injury and injury factors such as sex, age, stage of root development, fracture type, location of fracture, and severity of dislocation. Dent Traumatol 2004;20:192-202
5. Cvek M, Mejàre I, Andreasen JO. Conservative endodontic treatment of teeth fractured in the middle or apical part of the root. Dent Traumatol 2004;20:261-9

GE110 |

Clinical management of mandibular incisors with Vertucci Type IV canal configuration: A Case Report

Research Assistant Hicran DURMUŞ*, Prof Dr. Emre BODRUMLU*
*Zonguldak Bulent Ecevit University Faculty of Dentistry,
Department of Endodontics, Zonguldak - Turkey

Aim

It was to describe the managament of two sinus tracts associated with mandibulary central and lateral teeth with Vertucci Type IV canal configuration.

Introduction

Failure to recognize and treat an extra canal might provide a constant source of irritation, thereby compromising the long-term success of the root canal therapy.(1)Vertucci has classified morphological patterns of the root canal systems into eight types. (2,3)

In general, the mandibular incisors have one root canal with one apical foramen (Vertucci Type I) or two root canals with one apical foramen (Vertucci Type II).However, Vertucci Type IV is 3% and 2% in mandibular central incisors and lateral incisors, respectively, and 6% in canines(3,4)

Case Presentation

A 21-year-old woman was referred to the Endodontics Clinic of the Faculty of Dentistry. Initial radiography was performed for diagnostic purposes. (Fig.1.) Her main complaint was consistent sinus tracts formation in the mandibular anterior region. (Fig.2.) Her medical history was unremarkable.Gutta-percha points were advanced through the sinus tract to diagnose which teeth were involved.(Fig.3.) Clinical examination revealed tenderness on percussion and no response to thermal and electrical pulp sensitivity tests. Chronic apical abscess was diagnosed in the mandibular central and lateral incisor.

Under local anesthesia administration and rubber dam isolation (Fig.5.), access cavity was modified to an oval shape in the first appointment. After copious irrigation with 5.25% sodium hypochlorite, biomechanical preparation was done with 20/04 Ni-Ti rotary instruments (Endoart, Incidental, Turkey) and calcium hydroxide intracanal medicament was placed inside the canal.

In the next appointment, the sinus tracts were observed to have improved (Fig.6.). Biomechanical preparation was performed with 30/04 Ni-Ti rotary instruments (Endoart, Incidental, Turkey)to remove calcium hydroxide intracanal medicament from the canal. Canals were sequentially irrigated using 5.25% sodium hypochlorite, distilled water, 17% ethylenediaminetetraacetic acid (EDTA), distilled water, 5.25% sodium hypochlorite during cleaning and shaping procedure. The canals were thoroughly dried, and master cone was inserted (Fig.7.) and obturation was done using standardized gutta-percha (Diadent, Cheongju, Korea). Postendodontic permanent restoration was completed with composite resin and final radiograph was made. After 6 months of follow-up (Fig.8.), the patient had no pain on percussion and the periapical lesion of the teeth decreased on radiographic examination.

Conclusion

In this case report, although the endodontic treatment of mandibular incisors is thought to be simple, the importance of extra canals is recognized. Extra canals are considered in the treatment of unhealed sinus tracts. Treatments performed with attention to the possibility of this variation will result in a successful outcome.


Fig.1. Initial Radiograph


Fig.2. Preoperative image


Fig.3. Radiograph with gutta percha


Fig.4. Working length determination


Fig.5. Rubber Dam and view of root canal orifices


Fig.6.Postoperative Image


Fig.7. Master cone radiograph


Fig.8. 6-month follow-up

References

- 1.Mohan AG, Rajesh EA, George L, Sujathan, Josy SA. Maxillary lateral incisors with two canals and two separate curved roots. Contemp Clin Dent. 2012;3:519-21.
- 2.Vertucci FJ. Root canal anatomy of the mandibular anterior teeth. J Am Dent Assoc. 1974;89:369-71.
- 3. Vertucci FJ. Root canal anatomy of the human permanent teeth. Oral Surg Oral Med Oral Pathol. 1984;58:589-99.
- 4. Tiku AM, Kalaskar RR, Damle SG. An unusual presentation of all the mandibular anterior teeth with two root canals – A case report. J Indian Soc Pedod Prev Dent. 2005;23:204-6.

GE113 | CONFOCAL LASER SCANNING AND MICROCT EVALUATION OF THE INTRATUBULAR PENETRATION AND SEALING ABILITY OF CALCIUM SILICATE AND EPOXY-RESIN ENDODONTIC SEALERS.

V. FENOGLIO [1], D. PASQUALINI [1], E. BERUTTI [1], F. FANELLI [1], A. COMBA [1], A. BALDI [1], N. SCOTTI [1], M. ALOVISI [1]

[1] *University of Turin, Department of Surgical Sciences, Dental School, Turin, ITALY*

AIM: The aim was to compare the sealing ability of different calcium silicate-based and epoxy-resin endodontic sealers through confocal laser scanning microscope (CLSM) and MicroCT analysis.

Methodology: Sixty-five single-rooted teeth with fully formed apex were collected. After root canal shaping the specimens were distributed in six different groups (n=10) and a control group (n=5). Group A: AH Plus epoxy resin sealer (Dentsply Sirona), Group B: AH Plus bioceramic sealer (Dentsply Sirona), Group C: BC Sealer (Brasseler), Group D: BC Sealer HiFlow sealer (Brasseler), Group E: BioRoot Flow sealer (Septodont), Group F:
experimental resin sealer (Dentsply Sirona). All canals were sealed with single cone technique with the addition of a fluorescent dye. The specimens were MicroCT scanned and, afterwards, sectioned at four different levels and evaluated with CLSM. Kruskall-Wallis and Mann-Whitney U tests were used for the statistical analysis ($P < 0.05$).

Results: A higher Delta volume was reported for group E (BioRoot flow sealer, Septodont), suggesting an overall higher presence of voids and empty spaces ($P < 0.001$). The CLMS analysis showed no statistical difference between the groups at all four different points of analysis. Nevertheless, at the apical level AH Plus epoxy resin (Dentsply Sirona) showed a higher rate of empty spaces ($P = 0.044$). No statistical difference was recorded for the overall gap area, but the highest percentage of voids was present in the coronal and middle sections among all samples ($P = 0.03$). In terms of depth of penetration inside dentinal tubules there was no statistical difference for each group and for any point of analysis ($P > 0.05$).

Conclusions (mandatory): All tested sealers showed acceptable sealing ability. However, the root canals are
anatomically ovoidal especially in the coronal and middle third and this may be detrimental for the single cone cold technique regardless the sealer used.

GE114 | SUCCESSFUL SINGLE-SESSION REGENERATIVE ENDODONTIC TREATMENT OF A RETAINED PRIMARY MOLAR WITH DEEP DENTIN CARIES AND APICAL LESION: A CASE REPORT

I.D. KILIC [1], M. BULBUL [1], A. BOLUK [1], M.B. BURGAZLI [1]

[1] *Ankara University Dentistry Faculty Department of Endodontics, Ankara, TURKEY*

AIM: This case report aims to present a single-session regenerative endodontic treatment for a retained primary molar with deep dentin caries, apical lesion, buccal swelling, and fistula, in the absence of a successor permanent tooth germ. The goal is to evaluate the efficacy of this treatment protocol in managing symptoms, promoting stem cell activity, and ensuring long-term clinical success through systematic follow-up assessments.

Methodology: A 16-year-old female presented with a retained primary molar (tooth #75) and no successor permanent tooth germ, experiencing deep dentin caries, pain, apical lesion, buccal swelling, and fistula. A single-session regenerative endodontic treatment was performed. Under local anesthesia and rubber dam isolation, the buccal swelling was incised, and canals were disinfected with 1.25% sodium hypochlorite and 17% EDTA. Apical instrumentation induced bleeding to stimulate stem cell activity. Angelus MTA was placed over the blood clot at the cementoenamel junction, followed by composite restorations. Post-operative care included antibiotics, pain management, and oral hygiene instructions. At the one-week follow-up, the fistula had significantly regressed, and swelling had subsided. Further follow-ups were scheduled at 1, 3, and 6 months to monitor healing.

Results: Retained primary teeth can be successfully treated with regenerative endodontic procedures, even without successor permanent tooth germs.

Single-session regenerative treatment effectively manages deep dentin caries, apical lesions, and associated symptoms.

Hemostasis and promoting stem cell activity via apical instrumentation are crucial for success.

Immediate postoperative improvements highlight the treatment's effectiveness.

Regular follow-ups are essential to monitor healing and ensure long-term success.

GE115 | REGENERATIVE ENDODONTIC TREATMENT OF AN IMMATURE MAXILLARY CENTRAL INCISOR WITH PLATELET-RICH FIBRIN: A CASE REPORT

M.B. BURGAZLI [1], M. BULBUL [1], A. BOLUK [1]

[1] *Ankara University Dentistry Faculty Department of Endodontics, Ankara*

AIM: This case report aims to present a single-session regenerative endodontic treatment for an immature maxillary central incisor with a necrotic pulp and open apex, utilizing Platelet-Rich Fibrin (PRF) to evaluate the clinical procedure, outcomes, and efficacy.

Methodology: A 28-year-old male presented with an immature maxillary central incisor (tooth #11) with a necrotic pulp and an open apex due to previous trauma. Clinical and radiographic examinations revealed a large periapical lesion. The selected treatment involved a single-session regenerative endodontic procedure using Platelet-Rich Fibrin (PRF) derived from the patient's blood. After achieving local anesthesia and rubber dam isolation, minimal canal instrumentation and thorough disinfection with 2.5% sodium hypochlorite and 17% EDTA were performed. Calcium hydroxide was placed in the canal for two weeks. Subsequently, PRF was prepared and placed in the canal after inducing apical bleeding to stimulate tissue regeneration. Mineral Trioxide Aggregate (MTA) was placed over the PRF, and the access cavity was restored with composite resin. Post-operative care included antibiotics, pain management, and oral hygiene instructions. At the six-month follow-up, the patient exhibited significant healing of the periapical lesion, and the tooth remained asymptomatic. Further follow-ups were scheduled at 1, 3, and 6 months to monitor the healing process and ensure long-term success.

Results: Regenerative endodontic treatment using PRF can effectively treat immature teeth with necrotic pulps and open apices, promoting apical closure and tissue regeneration.

The use of PRF, a biocompatible and patient-derived material, supports wound healing and reduces the risk of infection, enhancing the success of regenerative procedures.

Minimal canal instrumentation, combined with effective disinfection protocols, is crucial for successful regenerative endodontic outcomes.

Immediate postoperative improvements and significant healing of the periapical lesion highlight the treatment's effectiveness.

Long-term follow-up is essential to monitor the healing process and ensure the stability and success of the treatment.

GE116

Endodontic Management of Maxillary Molar Teeth with Five Canals: A Case Series

Berkay Akman[1], Dide Tekinarslan[1], Damla Erkal[1], Kürşat Er[1], Öznur Güçlüer[1]

[1]*Akdeniz University, Faculty of Dentistry, Department of Endodontics, Antalya, Turkey*

berkayakman@akdeniz.edu.tr

European Society Of Endodontology Congress, 3-6 September 2025,Paris, France

Objective

In the treatment of the root canal system, knowledge of canal anatomy and possible variations is one of the important factors affecting the success of treatment. Maxillary molars, which show wide variations in terms of root canal morphology, are mostly observed to have three canals, but they may also have more than three canals. In this case series, root canal treatment of maxillary molars with 5 canals is presented.

Case Presentations

Case 1: A 39-year-old female patient presented to our clinic with night pain. In the initial periapical film taken from tooth 26, which showed sensitivity and pain due to a previous deep restoration, five canals were observed. After anesthesia, tooth was isolated with a rubber dam. Acces cavity was prepared then the working lengths of the canals were determined with an electronic apex locator (DTE, Woodpecker) and confirmed with a periapical film. The canal preparation was completed with a Scope RS Narrow (25 0.4) file. The permanent restoration of the tooth was completed in the same session (Fig. 1.).

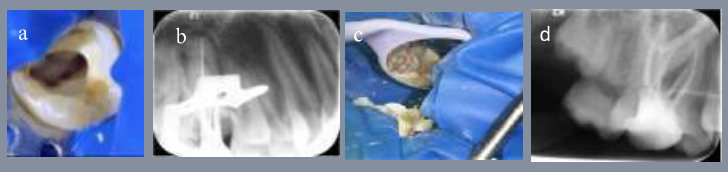

Figure 1. Access cavity (a), radiographic confirmation of master cones (b), after obturation (c), final radiograph (d)

Case 2: A 34-year-old female patient presented to our clinic with severe pain and percussion in tooth 16. It was learnt that the root canal treatment was completed one year ago but the spontaneous pain did not go away. In the first session, the previous root canal treatment was removed, canals were prepared with Endoart (30 0.4) and calcium hydroxide (CaOH) dressing was placed. At the second session, canals were irrigated, activated and obturated. The permanent restoration of the tooth was completed in the same session (Fig. 2.).



Figure 2. Initial radiograph (e), periapical film between sessions (f), after obturation (g), final radiograph (h)

Case 3: A 45-year-old female patient presented to our clinic for the treatment of tooth 26 with a periapical lesion in the posterior region of the maxilla. Isolation was provided with a rubber dam and the access cavity was prepared. Preparation was completed with Protaper Next (X2) file and permanent restoration was performed in the same session (Fig. 3.).

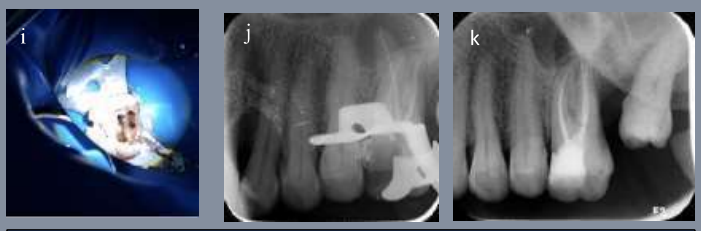

Figure 3. Access cavity (i), radiographic confirmation of master cones (j), final radiograph (k)

Result

During the follow-ups, it was observed that all the teeth were asymtomatic and still under control.

Discussion

For a successful root canal treatment, the infected pulp must be completely removed from the root canals and sealed. For this purpose, knowledge about root canal anatomy and variations should be obtained and necessary examinations should be performed before treatment.

References

1. *Vertucci FJ. Root canal anatomy of the human permanent teeth. Oral Surg Oral Med Oral Pathol 1984; 58: 589-99.*
2. *Ricucci D. Apical limit of root canal instrumentation and obturation, part 1. Literature review. Int Endod J 1998;31(6):384-93.*
3. *Zillich R, Dowson J. Root canal morphology of mandibular first and second premolars. Oral Surg Oral Med Oral Pathol 1973;36:738-44.*
4. *Alkaabi W, AlShwaimi E, Farooq I, Goodis HE, Chogle SM. A Micro-computed tomography study of the root canal morphology of mandibular first premolars in an Emirati population. Med Princ Pract 2017;26.2:118-24*

GE117 | EXPLORING VITAL PULP THERAPY, REGENERATIVE TREATMENT, AND ROOT CANAL THERAPY FOR OPTIMAL PATIENT OUTCOMES

M. BULBUL [1], M.B. BURGAZLI [1], A. BOLUK [1]

[1] *Ankara University Dentistry Faculty Department of Endodontics, Ankara*

AIM: This study aims to explore the critical decision of whether to preserve tooth vitality or perform a root canal treatment. Specifically, it evaluates the effectiveness of different methods—vital pulp therapy, regenerative treatment, and root canal treatment—on patient outcomes in endodontic practice.

Methodology: This presentation examines the biological, functional, and aesthetic considerations in deciding whether to keep a tooth alive or opt for root canal treatment. The materials and methods include radiographs, pulp vitality tests, dental microscopes, calcium hydroxide, biodentine, and glass ionomer cement for maintaining tooth vitality, as well as endodontic files, irrigation solutions, root canal sealers, and gutta-percha for root canal treatment. Findings show that vital pulp therapy and regenerative treatments preserve tooth vitality and function, while root canal treatment eliminates infection but sacrifices vitality. The study emphasizes selecting the appropriate treatment based on the tooth's condition and patient's needs. Future research should focus on larger sample sizes and extended follow-ups to enhance the efficacy and reliability of these methods, alongside advancements in dental materials and techniques.

Results: Diagnostic Tools: Radiographs, pulp vitality tests, and dental microscopes aid in selecting the appropriate treatment method.

Vitality Materials:Calcium hydroxide, biodentine, and glass ionomer cement protect and promote pulp healing.

Root Canal Materials:Endodontic files, irrigation solutions, root canal sealers, and gutta-percha remove infected pulp and clean root canals.

Vital Pulp Therapy: Removing coronal pulp, applying MTA, and using composite filling promotes healing and maintains tooth vitality.

Conclusions (mandatory): Regenerative Treatment: Calcium hydroxide, PRF (Platelet-Rich Fibrin), and MTA sealing achieve apex closure in necrotic teeth, effective in young and adult patients.

Root Canal Treatment:Involves removing infected pulp, cleaning and shaping root canals, and filling them with gutta-percha, eliminating infection but not preserving vitality.

Future Directions:Larger samples and extended follow-up periods are needed to improve these methods, with advancements in dental materials and techniques enhancing outcomes.

Acknowledgements (optional): Expressing Gratitude

GE118 | EVALUATION OF PUSH-OUT BOND STRENGTH AND ADHESIVE PATTERN OF THE EPOXYAMINE RESIN SEALER MODIFIED WITH BIOGLASS

P. DUIC [1], A. IVICA [2], I. SALINOVIC [2], S. JUKIC KRMEK [2], I. MILETIC [2]

[1] *Community Health Center Zagreb East, Zagreb, CROATIA*
[2] *University of Zagreb, School of Dental Medicine, Zagreb, CROATIA*

AIM: This study aimed to evaluate the effect of incorporating 5% (by mass) bioglass 45S5 particles into AH Plus Jet, an epoxy resin-based sealer, on the push-out bond strength and adhesive pattern of the sealer.

Methodology: Twenty single-rooted human teeth were instrumented using Reciproc R50 files, with 2% sodium hypochlorite as the irrigant, followed by 17% EDTA. The teeth were randomly divided into two groups (n=10 each): (1) an experimental group, in which AH Plus Jet was modified by adding 5% bioglass 45S5 particles, and (2) a control group, in which unmodified AH Plus Jet was used. All teeth were obturated with gutta-percha and the respective sealer using the single-cone technique. Each root was sectioned 3 mm from the apex to obtain 2-mm-thick slices. Push-out bond strength was measured using a universal testing machine at a crosshead speed of 1 mm/min with a 0.5 mm plunger. Adhesive patterns were evaluated using digital microscopy at 100× magnification. Data were analyzed using Student's t-test at a 5% significance level.

Results: The mean push-out bond strengths were statistically similar between the two groups ($p > 0.05$), with the control group exhibiting slightly higher values (35.6 MPa ± 2.75) compared to the experimental group (30.3 MPa ± 5.7). Analysis of the adhesive patterns revealed that the experimental group showed minimal sealer remaining on the dentinal walls after the push-out test, whereas the control group exhibited significantly more areas with residual sealer ($p < 0.05$).

Conclusions (mandatory): The addition of 5% bioglass 45S5 particles to AH Plus Jet did not significantly affect the push-out bond strength compared to the unmodified sealer. However, the unmodified sealer demonstrated a more pronounced adhesive pattern on the dentinal walls than the bioactive-modified sealer.

This work was supported by the Croatian Science Foundation under the project number HRZZ-IP-2022-10-6065.

GE119

COMBINED ROOT FRACTURE AND LUXATION DENTAL INJURY-A CASE REPORT

Pavićević Jelena [1], Jugoslav Ilić [1], Ognjan Pavlović [2]

[1] Department of Restorative Dentistry and Endodontics, School of Dental Medicine, University of Belgrade, Serbia

[2] Department of Maxillofacial surgery, School of Dental Medicine, University of Belgrade, Serbia



AIM – The aim of this case report is to present therapy of two combined complex dental injuries in one patient with favorable outcome.

INTRODUCTION – Although the vast majority of traumatic dental injuries (TDI) occur in children, it may happen in adults as well. Since the loss of a tooth has lifetime consequences, favorable treatment outcome is of great importance and depends of appropriate emergency management and a treatment plan. Crown fractures and luxation are the most common dental injuries, whereas the avulsions of permanent teeth are relatively rare and vary from 0.5% to 16% of all traumatic dental injuries [1,2].

CASE REPORT – A 50-year-old male patient was referred from Department of Maxillofacial Surgery, where he had received emergency treatment. The patient hit the floor due to loss of consciousness a night before, which led to avulsion of 21, root fracture in the middle third of 11, crown fracture of 12 without pulp exposure and lacerations of the lower lip. Suturing of the lower lip lacerations, replantation of the avulsed 21 and placement of a wire ligature splint were performed by a maxillofacial surgery resident. Patient came back only after 14 days. At that occasion the coronal fragment of tooth 11 with fractured root was dislocated in sagittal plane with significant luxation of both 11 and replanted 21. After access cavity preparation in 11, due to displaced coronal fragment, we placed K-file through coronal fragment to locate the canal in the apical fragment, and checked it radiographically(Fig.1,2).The mobile coronal segment was stabilized with a composite flexible splint while holding file inside both fragments to fixate them in exact position. Thereafter, standard root canal therapy (RCT) was performed on both incisors with special caution during irrigation of tooth 11. RCT was performed using a reciprocating file system. Sodium hypochlorite (1%) solution and 10% citric acid were used for irrigation and Ca(OH)2 medication for 4 weeks. Root canals were obturated with bioceramic sealer and gutta percha (Fig.3). All injured teeth including 12 were restored with composite filling(Fig.6,7).The composite splint was removed after two and a half months, according to constant clinical monitoring. Clinical and radiographic evaluations were done, following the protocol after 4 weeks, 8 weeks, 4 months, 6 months and a year (Fig.4,5,8.9). At the one-year follow-up, signs of bone repair were evident.



Fig.1- Radiography with inserted K-file



Fig.2 Clinical view



Fig.3 Obturation radiography



Fig.4 Control rdg after 4 months



Fig.5 One year follow-up rdg



Fig.6 Composite restoration of 12,11 and 21



Fig.7 Composite restorations



Fig.8 Control CBCT with signs of bone repair (2 years follow-up)



Fig.9 Control CBCT- sagital projection with signs of bone repair between two fragments of 11

DISCUSSION - Splinting is considered best practice in order to maintain the repositioned tooth in its correct position and to favor initial healing while providing comfort and controlled function. [1]. Since the luxation was significant, we decided to extand period of splinting up to 2,5 months This allows better healing of the marginal gingiva and bone. Mature permanent teeth that sustain a severe TDI, as in this case, after which pulp necrosis and infection is anticipated are amenable to preventive endodontic treatment. Additionally, regular and rigorous follow-ups of the traumatized teeth are essential for successful outcomes.

CLINICAL RELEVANCE – Dental trauma can significantly impact the quality of life by affecting oral function, appearance and emotional well-being. Thus immediate care, adequate treatment and constant follow-ups lead to restoring both functionality and esthetics, consequently enabling a better quality of life for trauma patients.

REFERENCES 1) Bourguignon C, Cohenca N, Lauridsen E, et al. International Association of Dental Traumatology guidelines for the management of traumatic dental injuries: 1. Fractures and luxations. Dent Traumatol 2020;36(4):314-330.

2) Fouad AF, Abbott PV, Tsilingaridis G, et all. International Association of Dental Traumatology guidelines for the management of traumatic dental injuries: 2. Avulsion of permanent teeth. Dent Traumatol. 2020 Aug;36(4):331-342.

GENERAL ENDODONTIC POSTERS 03

GE120 | THREE-ROOTED MAXILLARY PREMOLARS: A REPORT OF THREE CASES

M. RAHIMI [1], S. AL HAJAJ [1], T. YALÇIN [2], K. ERDEN [1]

[1] *Istanbul University, Institute of Graduate Students in Health Sciences, Istanbul, TURKEY*
[2] *Istanbul University, Institute of Graduate Students in Health Sciences, Istanbul, TURKEY*
[3] *Istanbul University, Faculty of Dentistry, Department of Endodontics, Istanbul, TURKEY*
[4] *Istanbul University, Institute of Graduate Students in Health Sciences, Istanbul, TURKEY*

AIM: Three-rooted maxillary premolars are rare anatomical variations that impact endodontic treatment. This presentation discusses three clinical cases, emphasizing diagnosis, treatment strategies, and clinical relevance (Vertucci & Gegauff, 1979; Kartal et al., 1998).

Methodology: Failure to recognize three-rooted premolars can lead to incomplete treatment and persistent infections (Weine et al., 1969; Cleghorn et al., 2006). Proper diagnosis and technique are crucial for successful management.

Case 1: A 25-year-old male presented with pain in the upper right first premolar. Radiographic examination revealed an unusual root morphology. RCT was performed using a modified access cavity and careful instrumentation and single cone thecnique obturation.

Case 2: A 30-year-old male was referred for RCT of the upper left second premolar. Preoperative radiographs suggested an extra root. Treatment was completed with single cone thecnique obturation.

Case 3: A 28-year-old male required RCT for the upper right second premolar. Initial radiographs did not clearly show additional roots, but clinical exploration and angulated X-rays revealed a trifurcated root system. Treatment was successful using a modified access cavity and single cone thecnique obturation.
Results: • Three-rooted maxillary premolars, though rare, should be considered in diagnosis (Vertucci & Gegauff, 1979).

• CBCT and angulated radiographs enhance detection (Hargreaves et al., 2011).

• Modified access cavity design and careful instrumentation improve outcomes (Pitt Ford, 2004).

• Recognizing anatomical variations prevents endodontic failure and enhances patient care.

GE121 | INTERNAL BLEACHING FOLLOWING NON-SURGICAL ENDODONTIC RE-TREATMENT: A CASE REPORT

HELYA JAVADI MOGHADDAM, MICHAEL DUQUE VASQUEZ

AIM

To demonstrate the successful use of internal bleaching following endodontic re-treatment of a discoloured maxillary central incisor.

INTRODUCTION

Discolouration of non-vital teeth is a common aesthetic concern. Internal bleaching provides a conservative solution, but prior endodontic evaluation is crucial for long-term success.

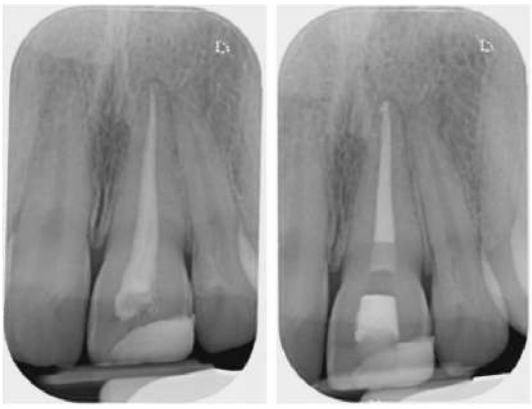

Figure 1 and Figure 2: Radiographs before and after re-root canal treatment

CASE PRESENTATION

A 25-year-old female presented with discolouration of UL1 after childhood root canal treatment. Additional staining was noted from an incisal composite. A re-treatment under rubber dam was completed by removing gutta-percha, disinfecting with sodium hypochlorite, and obturating using warm vertical condensation to 22mm with an apical size 50. The canal was sealed with GIC and PTFE to facilitate future bleaching. The patient was informed of the 70% success rate of secondary endodontic treatment and the need for follow-up. Endodontic re-treatment was referred.

CLINICAL MANAGEMENT

After healing, custom whitening trays with labial and open-palatal reservoirs were fabricated. Internal bleaching with 16% carbamide peroxide was performed for three days, followed by two weeks of external bleaching until a shade match had been achieved. The gel was changed every two hours, and the tray was worn overnight. One-week post-bleaching, the access cavity was sealed with composite and edge bonding was replaced. The patient was highly satisfied with the outcome.



Figure 3: Extraoral photograph before commencing re-root canal and internal bleaching



Figure 4: Extraoral photograph after re-treatment and internal bleaching. Edge composite has been replaced.

DISCUSSION

Internal bleaching is a minimally invasive alternative to restorations, preserving tooth structure and preventing further weakening. Success depends on adequate root sealing, controlled peroxide exposure, and patient compliance.

FOLLOW UP

Annual follow ups are required to ensure the absence of pain, swelling, sinus tract, loss of function and radiological evidence of a normal periodontal ligament space around the root. Periapical radiographs to be taken yearly for the first 5 years . Assess shade stability every 12 months.

CLINICAL RELEVANCE

Appropriate endodontic re-treatment and a structured bleaching protocol can achieve predictable aesthetic outcomes while maintaining tooth integrity.

BIBLIOGRAPHY:

Poyser, N.J., Kelleher, M.G.D. and Briggs, P.F.A. (2004) 'Managing discoloured non-vital teeth: The inside/outside bleaching technique', Dental Update, 31(4), pp. 204–214.

Ng, Y.-.-L., Mann, V. and Gulabivala, K. (2008), Outcome of secondary root canal treatment: a systematic review of the literature. International Endodontic Journal, 41: 1026-1046.

Löst, C. (2006) 'Quality guidelines for endodontic treatment: Consensus report of the European Society of Endodontology', *International Endodontic Journal*, 39(12), pp. 921–930. doi:10.1111/j.1365-2591.2006.01180.x.

GE122 | THE EFFICIENCY OF USING NEW BROKEN INSTRUMENT REMOVAL KIT DESIGNED BY DR. SIAVASH MOUSHEKHIAN (KAMAND).

S.W.T. AL HAJAJ [1], D.E. ÖZCAN [2], T.Y. YALÇIN [3]

[1] *Istanbul University, Instiute of Graduate Studies in Health Sciences, Istanbul, TURKEY*
[2] *Faculty of Dentistry, Department of Endodontics, Istanbul, TURKEY*
[3] *Faculty of Dentistry, Department of Endodontics, Istanbul, TURKEY*

AIM: The success of root canal treatment depend on many factors one of them is to fill the entire root canal system following cleaning and shaping of root canal system, a broken instrument could be an obstruction that could effect negatively on the prognosis of the treatment (1). That is why many different instruments and techniques are developed in order to remove these instruments. New removal kit by Dr. Slavish Moushekhian cooperated with Zumax (Suzhou, Jiangsu. China). Dr. Moushekhian developed a loop and claims that it is capable of holding and removing long separated instruments without facing secondary fracture. In these cases KAMAND (Zumax, Suzhou, China) was used to remove the separated instruments with the aid of ultrasonic.

Methodology: fracture instruments and how to mange long ones

Results: KAMAND
Broken instruments removal
cleaning and shaping

GE124 | EVALUATING THE USE OF SELF-CONDITIONING ADHESIVE COMBINED WITH DUAL CURING RESIN CEMENT AS AN ENDODONTIC SEALER: AN IN VITRO STUDY

C.I. ANTON Y OTERO [1], N. LIAUDET [2], E. Di BELLA [1], M. ABDELAZIZ [1], A. FEILZER [3], I. KREJCI [1], L. MARGER [1]

[1] *Division of Cariology and endodontology, CU mD - University Clinics of Dental medicine, Faculty of medicine, University, Geneva, SWITZERLAND*
[2] *Bioimaging Core Facility, University of Geneva, Geneva, SWITZERLAND*
[3] *Department of Dental Material Sciences, Academic Center of Dentistry,, Amsterdam, THE NETHERLANDS*

AIM: To compare infiltration, sealing and microleakage in root dentin with a self-conditioning adhesive system combined with dual curing resin (resin-based cement) to a conventional epoxy-resin-based sealer using confocal microscopy imaging.

Methodology: 26 roots were enlarged and disinfected. Dentin tubules of 24 teeth were labelled with a red fluorophore (Rhodamine B) (two samples served as controls). Root canal samples were sealed in group AH (n = 11) with a conventional sealer (AH Plus Root Canal Sealer, Dentsply DeTrey) and in group RC (n = 11) with a resin-based cement (Parabond combined with Paracore, Coltène). Roots were then sectioned horizontally and immersed in H2O2 to remove the Rhodamine B not fixed by the sealers. The empty dentin spaces were labeled with a green fluorophore (Fluorescein) enabling the evaluation of infiltration as well as microleakage by confocal microscopy. Two additional samples were fractured in vertical direction for observation under SEM.

Results: Group RC presented significantly more infiltration in the middle third than in the middle and apical thirds of group AH. Microleakage was significantly higher in group AH than in group RC. SEM images revealed more dentin plugs and a homogenous resin layer in group RC in contrast to group AH.

Conclusions (mandatory): The resin-based cement revealed promising outcomes compared to a traditional epoxy resin based sealer.

GE126 | Treatment of a Permanent Central Tooth with Horizontal Root Fracture Due to Trauma Using MTA: A Case Report

Hatice Büyüközer ÖZKAN[1], Tuğba GÖK[1]
[1]Alanya Alaaddin Keykubat University, Faculty of Dentistry, Department of Endodontics

Aim:

The aim of this case is to present the treatment of a permanent central tooth with a horizontal root fracture using Mineral Trioxide Aggregate (MTA).

Introduction:

Horizontal root fractures typically occur in the middle-third of the root, with rare cases in the apical-third. Fractures in the coronal-third have a poorer prognosis(1).

Case Presentation:

A 16-year-old male patient presented with sensitivity in the upper left incisor. His medical history revealed a traffic accident 3 months prior. During examination, a non-complicated enamel-dentin fracture was found on teeth 11, 12, 21, and 22, with percussion and palpation pain in tooth 21. Periapical radiographs showed a horizontal root fracture in the middle third of tooth 21. Vitality tests confirmed that teeth 11, 12, and 22 were vital, while tooth 21 was non-vital, with mobility and a 5 mm pocket depth. In the first session, extirpation was performed on tooth 21, and calcium hydroxide was placed as intracanal medication. In the second session, the fracture was filled with MTA, and a composite resin restoration was applied. Non-rigid splinting was used before curettage to address the deep pocket in tooth 21, and the patient was monitored. At the 1-month follow-up, pain reduced, though percussion sensitivity persisted, the sinus tract had partially healed, and no discoloration was noted.



Fig.1 preoprative



Fig.2 postoperative one month follow –up

Discussion:

Success following root fractures depends on the extent of pulp injury. If the pulp is necrotic, root canal treatment is necessary for repair(2). MTA is a suitable material for filling horizontal root fractures, though further studies on alternative materials and prognostic factors are needed to understand its long-term effectiveness.

Clinical Relevance:

Factors such as vitality, fracture location, and mobility are crucial in determining treatment for horizontal root fractures. Continuous monitoring of symptoms and the condition of the tooth is essential, even when the prognosis is poor, to retain the tooth for as long as possible.

REFERENCES

1. FitzGerald L. Treatment of intra-alveolar root fractures. General Dentistry. 1988;36(5):412-3.
2. Hovland EJ. Horizontal root fractures: treatment and repair. Dental Clinics of North America. 1992;36(2):509-25.

GE128 | EVALUATING THE ADEQUACY OF 2D VS 3D RADIOGRAPHS IN ENDODONTIC DIAGNOSIS AND TREATMENT: A CASE REPORT

A.N. GUMUS GENCER [1], A. AKCAKOCA [2]

[1] *Acibadem Health Group Dental Clinic, istanbul, TURKEY*
[2] *Acibadem Health Group Dental Clinic, istanbul, TURKEY*

AIM: This study aims to evaluate the diagnostic and management efficacy of panoramic and periapical radiography in comparison to cone beam computed tomography (CBCT) in routine endodontic cases.

Methodology: A 29-year-old female patient presented with a periapical lesion at the root apex of tooth #27, which had previously undergone root canal therapy. Initial radiographic examinations, including periapical and panoramic radiographs, revealed a periapical lesion. Root canal retreatment was performed; however, after three weeks, the sinus tract reappeared. Subsequently, CBCT was employed, revealing a large periapical lesion extending to tooth #26, a finding not visible on 2D radiographs. A cold test indicated a devitalized response in tooth #26, necessitating root canal therapy. Despite no reduction in the lesion after three months and the persistence of the sinus tract, a surgical consultation was sought. Apical resection and grafting were deemed necessary. Follow-up at three and six months demonstrated complete resolution of the sinus tract and periapical healing.

Results: Conventional radiographs, including periapical and panoramic images, are commonly used for the diagnosis of periapical lesions. However, CBCT offers superior diagnostic accuracy, particularly for large lesions or complex cases. While periapical radiographs are more detailed in the periapical region, they may fail to reveal the full extent of the lesion. Although CBCT provides more comprehensive information, its use is limited by higher radiation exposure compared to conventional radiographs.

Conclusions (mandatory): This case highlights the critical role of advanced imaging modalities, such as CBCT, in the accurate diagnosis and management of complex endodontic cases. CBCT can significantly enhance clinical decision-making, particularly in situations where conventional radiographs fail to provide a complete assessment, ultimately improving treatment outcomes.

GE129 | RETREATMENT AND LONG-TERM FOLLOW-UP OF A ROOT CANAL-TREATED RIGHT MAXILLARY LATERAL INCISOR WITH APICAL LESION SUSPECTED TO BE A RADICULAR CYST

Authors Cagri Cakmakci, DDS, MSc, Specialist in Endodontics

Affiliations Private Practice

INTRODUCTION

Although primary endodontic treatments have high success rates (78–91%), failures may still occur (1). In such cases, contemporary nonsurgical retreatment should be attempted before considering surgical interventions (2).

Figure 1: Healing process of the tooth

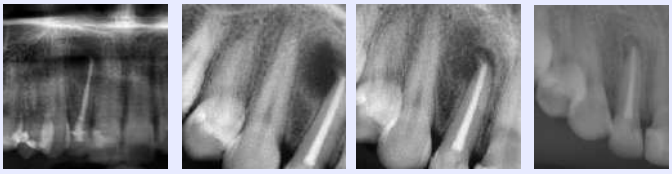

Initial | 4 months | 11 months | 24 months

DISCUSSION

Previous studies have reported success rates of 78–87% for apical healing following retreatment (1). Compared to other treatment options, nonsurgical retreatment is a more conservative and well-tolerated approach (2).

Figure 2: Coronal restoration



Ribbond usage | Post-op | 24 months

CLINICAL RELEVANCE

Given the high success and healing rates of root canal-treated teeth with apical lesions, nonsurgical retreatment should be considered the first-line treatment option (3).

AIM

The aim of this study is to observe the healing of large apical lesions in root canal-treated teeth following retreatment and long-term follow-up.

CASE PRESENTATION

In November 2022, a 25-year-old female patient presented to our clinic for the replacement of a filling in her right maxillary lateral incisor. Radiographic examination revealed a large periapical lesion. The existing restoration was removed under rubber dam isolation, followed by the removal of the root canal filling using retreatment files. During working length determination, it was observed that the main canal bifurcated into two separate canals in the apical third. The canal was shaped and irrigated with 2.5% NaOCl and ultrasonic activation. A temporary restoration was placed after dressing the root canals with calcium hydroxide. Unfortunately, during the second appointment, a manual hand file fractured in the branching area while examining the apical region. Due to anatomical complexity, presence of a second apex, and previous intracanal irrigation and medication, the decision was made not to remove the fractured instrument. The root canal treatment was completed using a bioceramic sealer and gutta-percha. The final restoration was performed with composite resin, reinforced with a fiber post system.

At the 4-month and 11-month follow-ups, the apical lesion showed significant regression. By the 24-month follow-up, complete healing was observed, and the restoration remained stable.

REFERENCES

1- Ng YL, Mann V, Gulabivala K. A prospective study of the factors affecting outcomes of non-surgical root canal treatment: part 1: periapical health. J Endod 2009;35(5): 623-30. https://doi.org/10.1016/j.joen.2009.04.023

2- Sjogren U, Hagglund B, Sundqvist G, Wing K. Factors affecting the long-term results of endodontic treatment. J Endod 1990;16(10): 498-504. https://doi.org/10.1016/S0099-2399(99)80304-5

3- Nair PN. Pathogenesis of apical periodontitis and the causes of endodontic failures. Oral Surg Oral Med Oral Pathol Oral Radiol Endod 2006;102(1): 87-93. https://doi.org/10.1016/j.tripleo.2004.09.014

GE130 | SHAPING ABILITY OF MTWO, ZENFLEXTM, E-FLEX ONE AND E-FLEX EDGE NICKEL TITANIUM ROTARY INSTRUMENT IN PREPARATION OF CURVED CANALS USING MICRO-COMPUTED TOMOGRAPHY

P. PHUMPATRAKOM [1], P. METTASAT [2], A. CHELOH [3], P. SURIYAKRAINGKAI [4]

[1] *Division of Endodontics, Faculty of Dentistry, Thammasat University, Bangkok, THAILAND*
[2] *Division of Endodontics, Faculty of Dentistry, Thammasat University, Bangkok, THAILAND*
[3] *Division of Endodontics, Faculty of Dentistry, Thammasat University, Bangkok, THAILAND*
[4] *Division of Endodontics, Faculty of Dentistry, Thammasat University, Bangkok, THAILAND*

AIM: Nickel-Titanium rotary files have been widely used in root canal preparation. The heat treatment process has been used to improve the mechanical properties, especially to increase the flexibility of these files. This study aimed to compare the centering ability, canal transportation, and dentin volume change using four different Nickel-Titanium files.

Methodology: Forty-four canals were randomly divided into four groups. An image of each canal was captured before and after root canal preparation using a micro-CT. Dataviewer was used to superimpose pre- and post-instrumentation photos. Then the centering ratio, canal transportation, and volume change were measured. By CTAn application.

Results: E-FLEX EDGE showed the highest centering ratio in apical and middle parts of the root canal but in the cervical part E-FLEX ONE is the highest. Moreover, E-FLEX EDGE revealed the least canal transportation in the apical and middle parts. In contrast, ZenFlexTM exhibited the least amount of canal transportation at the cervical level. Lastly, the total amount of dentin volume change was found the highest removal in E-FLEX EDGE whereas Mtwo was found the lowest dentin volume change.

Conclusions (mandatory): E-FLEX EDGE was a good candidate for root canal preparation in terms of centering ability and canal transportation. ZenFlexTM was found to be the most appropriate systems in severely curved canals.

GE131 |Microscope-Assisted Endodontic Retreatment and Digital Biomimetic Approach in Posterior Teeth

Celal AKTAY, Burcu DAĞDELEN, M. Çağlar BURSA PHD, Süha ALPAY PHD

AIM - This study aims to present the endodontic retreatment of an 18-year-old female patient with pain in the mandibular left first molar (tooth #36). The case focuses on the removal of a screw post and non-surgical retreatment under rubber dam isolation, followed by biomimetic restoration using digital workflows to achieve a successful clinical outcome.

INTRODUCTION - Endodontic retreatment is needed when previous therapy fails due to infection, inadequate filling, or structural issues like a screw post. Advances in digital dentistry and biomimetic restorations improve treatment success and efficiency.

This case reports the retreatment of an 18-year-old female with pain in the mandibular left first molar, involving screw post removal, non-surgical retreatment, and biomimetic restoration using digital workflows.

CASE PRESENTATION - An 18-year-old female patient presented with pain in the mandibular left first molar (tooth #36). Clinical and radiographic examinations revealed the presence of a screw post and inadequate root canal filling. Under a microscope, rubber dam isolation was established, and the screw post was carefully removed. Non-surgical retreatment was performed using ProTaper Universal Retreatment files. Ultrasonic activation was utilized for irrigation. Final irrigation included 5 ml of 5.25% sodium hypochlorite, 5 ml of 17% EDTA, and 5 ml of distilled water, applied 2 mm shorter than the working length. Following the completion of root canal treatment, tooth preparation was performed while preserving the ferrule, in accordance with the principles of the biomimetic approach. A digital impression was obtained using an intraoral scanner (CEREC Primescan), and the restoration was subsequently designed using exocad software. The restoration was fabricated through additive manufacturing techniques. Specifically, the endocrown was printed using a permanent crown resin (Permanent Crown Resin, Triniq Varseo Smile) with a 3D printer (Phrozen Sonic Mini 4K). Post-printing, the endocrown was cleaned in isopropyl alcohol for three minutes, followed by a curing process to complete polymerization. Finally, the endocrown was cemented using a dual-cure resin cement.







DISCUSSION - This case demonstrates the successful retreatment of a mandibular first molar complicated by a screw post and inadequate root canal filling[1]. Microscope-assisted post removal ensured safe and thorough debridement, highlighting the value of enhanced visualization in complex retreatments. Ultrasonic activation of irrigants optimized disinfection, aligning with evidence that improved irrigant penetration enhances clinical outcomes[2]. By integrating modern endodontic and restorative techniques, this treatment approach not only addressed the immediate symptoms but also promoted a sustainable and patient-centered outcome[3].

CLINICAL RELEVANCE - Modern techniques enhance endodontic retreatment by improving precision, disinfection, and efficiency. Digital workflows enable durable, biomimetic restorations, optimizing outcomes and patient satisfaction.

REFERENCES –

1- 1- Bitter, K., & Kielbassa, A. M. (2007). Post-endodontic restorations with adhesively luted fiber-reinforced composite post systems: a review. *American journal of dentistry*, *20*(6), 353.
2- Plotino G, Pameijer CH, Maria GD, Somma F. Ultrasonics in endodontics: a review of the literature. **J Endod.** 2007;33(2):81-95.
3- Murty, S. (2024). Minimally Invasive Endodontic Techniques: Balancing Tooth Preservation and Treatment Outcomes. *Journal of dental care*, *1*(2), 12-21.

Case Report, Surgical Management of a Foreign Body Infection With the Use of PRF as a Conjunctive Regenerative Agent.

Chulalongkorn University

GE132

Saranya Vongsrisuchon D.D.S

Aim: To present an interesting case of a confusing diagnosis due to an unknown foreign body infection resulting from a previous dental treatment.

Introduction: Pulpal infections are typically successfully treated with non-surgical root canal therapy. However, in some cases, the expected outcome is not achieved, presenting a challenge for endodontists in identifying and managing the true source of infection. In this case, the patient exhibited extensive pus and swelling that did not correlate with a typical pulp infection. This contradictory finding posed a challenge for the dentist in determining the most appropriate treatment.

Case present: A 19-year-old female presented with swelling and pain in her right cheek. She had undergone an emergency pulp removal on tooth 11 five years ago but never completed the root canal treatment

Examination revealed multiple sinus openings with pus drainage and a large radiolucent lesion extending from teeth 11 to 15. NS-RCT was initiated, however, the infection persisted, requiring surgical intervention.

During surgery, a rubber dam roll was unexpectedly discovered inside the lesion, likely left from a previous drainage attempt, contributing to the chronic infection. The granulation tissue was carefully removed, and apical surgery was performed on tooth 11. A blood sample was processed to prepare platelet-rich fibrin (PRF), which was placed in the bone cavity to promote healing and regeneration. The lesion also involved teeth 12 and 13, necessitating further treatment.

The patient was followed up at 1, 4, and 8 years post-treatment, with no signs of infection or symptoms. Radiographic evaluation confirmed complete healing of the lesion.

Discussion: The severe infection in this case resulted from a leftover rubber dam acted as a foreign object for four years, leading to an intense inflammatory process that significantly complicated the treatment.
And PRF was chosen for used in this large defect cavity for promoting completed bone healing.

Clinical Relevance: Unintended infections in patients sometimes result from the actions of the dentist and could be avoided through clear and accurate communication.

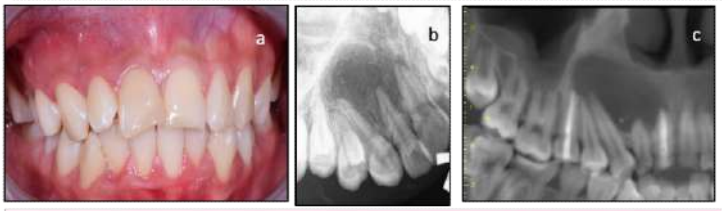

Figure 1: (a) The oral examination shows a buccal gingival swelling with a sinus opening in the area of tooth 13-14. (b) The topographic radiograph shows a large radiolucent area covering the apex of teeth 11-15. (c) Cone Beam Computed Tomography (CBCT) images reveal that the center of the lesion is located at tooth 12-13, which still responds to the vitality test.

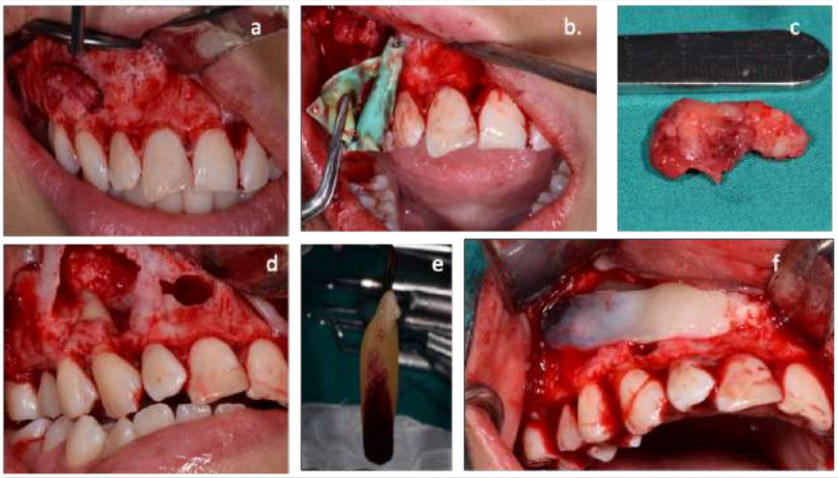

Figure 2: (a) After flap elevation, a buccal bone perforation site was observed at tooth 13-14. The bone defect was filled with granulation tissue. (b) A Rubber dam roll was found inserted in the bone cavity along with a piece of granulation tissue. (c) The entire piece of granulation tissue was enucleated. Pathology diagnosis revealed it to be a Radicular cyst. (d) The bone defect involved the root tip of teeth 12-13 which needs further treatment. A 5*5 mm bone window at the apical area of tooth 11 was created in order to perform apicoectomy and retrofilling. (e) The Platelet-Rich Fibrin (PRF) is obtained from the patient's own blood through centrifugation. The red part of the Red Blood Cells (RBC) will be removed, and only the fibrin clot part will be used. (f) A piece of fibrin clot will be pressed until it becomes a whitish-gray membrane. It will be placed on the labial bone to serve as a Guided Tissue Regeneration (GTR) membrane.



Figure 3 : Follow up 8 year Completed healing

Reference : Arshad, S., Sohaib, T., Fatima, R., Khan, M., Ahmed, F., Marya, A., Karobari, M. I., & Isaqali, M. (2021). Platelet-rich fibrin used in regenerative endodontics and dentistry: Current uses, limitations, and future recommendations for application. Int. J. Dent., 2021,

GE136 | TREATMENT OPTIONS FOR SEVERELY CALCIFIED CANALS

A. KROKIDIS [1]

[1] *NATIONAL AND KAPODISTRIAN UNIVERSITY OF ATHENS, ATHENS, GREECE*

AIM: The primary objective of this lecture is to compare the two techniques and emphasise the significance of each approach. Additionally, it will present a method for effectively managing obliterated canals.

Methodology: The success of root canal therapy hinges on the utilisation of appropriate access cavity, cleaning, shaping, and root filling techniques. Pulp canal calcification arises from the deposition of calcified tissue in the canal walls due to trauma and other factors. Consequently, the root canal space can be partially or completely occluded. In this context, endodontic treatments of severely calcified teeth are regarded as exceptionally challenging and intricate.
For several years, clinicians have endeavoured to resolve these intricate treatments employing “freehand” techniques. However, these techniques encounter significant challenges in canal localization and treatment, potentially resulting in damage to the tooth’s initial anatomy. Consequently, the freehand technique has been restricted to the expertise of a select few experienced clinicians.
Presently, with the advancement of digital enhancements in endodontic therapy, guided navigation of the root canal (both static and dynamic) has become an integral component of the daily clinical approach to this challenging and unpredictable procedure. This approach offers a safer methodology and more predictable outcomes, irrespective of the clinician’s level of experience.

Results: Conversely, these techniques for success are time-consuming, the overall cost of the therapy increases substantially, and necessitate meticulous planning by experienced clinicians.
The most pertinent question arises regarding the most effective treatment approach for calcified canals and the optimal technique to employ in each case.

Conclusions (mandatory): The primary objective of this lecture is to compare the two techniques and emphasise the significance of each approach. Additionally, it will present a method for effectively managing obliterated canals.

GE137

THE INFLUENCE OF TEMPOROMANDIBULAR JOINT DYSFUNCTION ON ENDODONTIC TREATMENT



Author: Zivar İbragimli
The Faculty of Dentistry Teaching Clinic of Azerbaijan Medical University,
Department of Endodontics

Keywords:
Endodontic treatment, temporomandibular joint dysfunction, mouth opening limitation, rubber dam application, bruxism, splint therapy

AIM/OBJECTIVE

To investigate the effects of temporomandibular joint dysfunction (TMJD) on endodontic treatment outcomes using a clinical case.

INTRODUCTION

Temporomandibular joint dysfunction (TMJD) affects 20–30% of the population and poses significant challenges in endodontic treatment. Limited mouth opening and muscle tension complicate root canal procedures and increase the risk of complications. Prolonged dental procedures may further aggravate existing TMJD, making it essential to consider joint health when planning treatment.

CASE PRESENTATION

A 24-year-old female patient presented with the need for endodontic treatment on tooth 37. The treatment was postponed due to symptoms of TMJD. Key clinical details include:

- Symptoms: Joint clicking for three years; pain radiating to the head, neck, and ears.
- Mouth Opening: Limited to 37 mm and painful.
- MRI Findings: Joint space narrowing, presence of osteophytes, restricted lateral movement, and abnormal jaw trajectories.

An additional treatment plan was developed to manage occlusion and address tooth height loss.

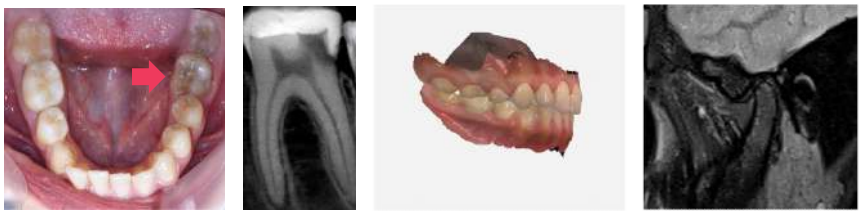

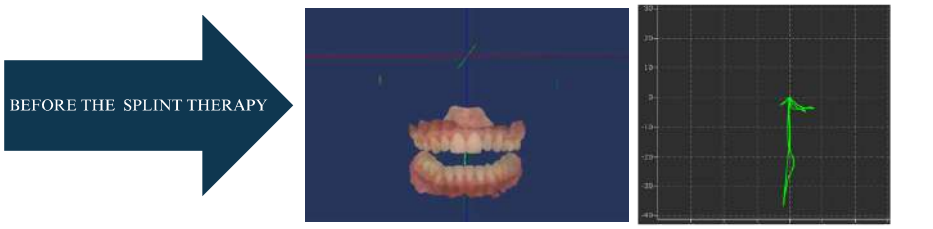

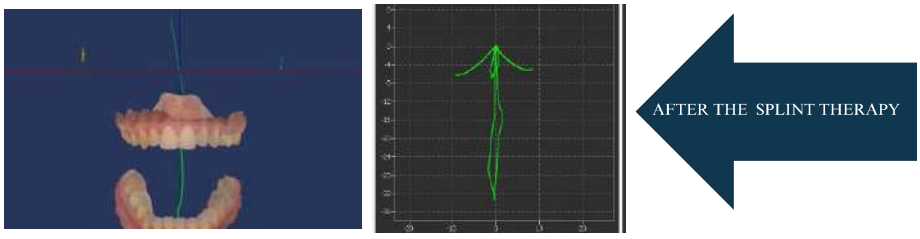

CLINICAL RELEVANCE

An integrated approach combining splint therapy with occlusal restoration improves access and treatment outcomes in TMJD patients by facilitating better rubber dam placement and reducing procedural complications.

CONCLUSION

Integrating splint therapy and occlusal management into endodontic protocols significantly enhances treatment efficacy for patients with TMJD.



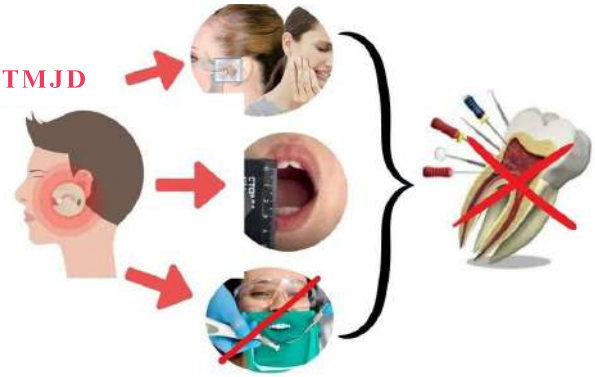

DISCUSSION

TMJD posed challenges, primarily by hindering proper rubber dam application due to limited mouth opening. To address these difficulties, a combined therapeutic approach was adopted. Splint therapy was initiated to restore occlusal balance and reduce TMJ strain, thereby promoting muscle relaxation. The endodontic treatment was performed using the Reciprocal One File system to minimize complications. After treatment, splint therapy continued alongside the use of Inlay/Onlay tabs to stabilize bite height and further reduce TMJ load.



GE138 | Fractured Instrument Retrieval with Minimal Dentin Loss: A Case report

Eylem Fergül Akay[1], Hasan Öksüzoğlu[1], Özgür Topuz[1]
[1]Department of Endodontics, Faculty of Dentistry, Gazi University

AIM

To present a step-by-step protocol for the conservative management of a fractured endodontic instrument, emphasizing bypassing techniques and selective use of ultrasonics to preserve dentin and achieve successful retrieval.

CASE PRESENTATION

A 52-year-old male patient presented with severe pain and percussion sensitivity in tooth #16. Clinical and radiographic evaluation confirmed symptomatic apical periodontitis. *(Fig. 1)*

During canal instrumentation, a 5 mm S2 rotary file fractured in the distobuccal canal, from the coronal portion to the middle third, where the curvature begins. *(Fig. 2)*

Initial Attempt: A Maseran retrieval kit was used, but the fragment could not be securely grasped.

Conservative Approach: To avoid excessive dentin removal, EDTA was applied to facilitate bypassing after the failed attempt with the Maseran kit.

Ultrasonic Activation: The fragment was loosened using Eighteeth Ultra X (blue tip).

Successful Bypass: A K-file was used to bypass the fragment, and ultrasonic activation allowed for safe retrieval. *(Fig. 3)* *(Fig.4)*

Post-Treatment: The canal was disinfected, dressed with calcium hydroxide, and the patient was recalled. At the second appointment, the canal was obturated using gutta-percha and a resin-based sealer. *(Fig. 5)* *(Fig.6)*

INTRODUCTION

Fractured instruments are among the most complex challenges in endodontics, particularly when located in curved or narrow canals. Traditional removal methods can compromise root integrity due to unnecessary dentin removal[1].



Fig. 1.



Fig. 2



Fig. 3



Fig.4





Fig.5



Fig.6

DISCUSSION

Fractured instrument retrieval requires balancing effective intervention with dentin preservation.. Bypassing, aided by EDTA and ultrasonic activation, offers a conservative alternative. This stepwise approach minimizes dentin loss and reduces the risk of root fracture. Adapting the strategy to each case improves prognosis by preserving structural integrity.

CLINICAL RELEVANCE

Effective management of separated instruments relies on minimally invasive techniques that protect the remaining tooth structure. This case illustrates how combining bypassing with ultrasonics can enable successful retrieval while maintaining dentin integrity and long-term tooth viability.

References

1. **Terauchi Y, Ali WT, Abielhassan MM.** Present status and future directions: Removal of fractured instruments. *Int Endod J.* 2022;55:688–702.

GE139 | INVESTIGATION OF THE EFFECT OF POTENTIAL DENTINE CONDITIONING SOLUTION ON THE PUSH-OUT BOND STRENGTH OF CALCIUM SILICATE-BASED SEALER WITH DENTINE; AN INVITRO STUDY

F. ALKHATEEB [1], A. ATMEH [1], M. JAMAL [1]

[1] *Mohammed Bin Rashid University Of Medicine And Health Sciences, Dubai, UNITED ARAB EMIRATES*

AIM: Hydraulic calcium silicate-based sealers (HCSS) have gained popularity recently due to their favourable properties. However, as with other sealers, adaptation to radicular dentine remains a considerable challenge. This study aimed to evaluate the effect of soluble silicate (SS) solutions on dentine and on the push-put bond strength of an HCSS to radicular dentine.

Methodology: Sixty extracted human mandibular premolars were decoronated, and canals were chemo-mechanically prepared using NiTi rotary files and 2% NaOCl, followed by a final rinse of 17% ethylenediaminetetraacetic acid, 2% NaOCl, and 5ml deionised water. Samples were divided into four groups (n=15) based on the final irrigation with SS solutions: 12.5%, 6.25%, 3.125%, and a control group. Canals were filled with an HCSS (BioRoot RCS), and teeth were stored in phosphate-buffered saline at 37°C for a week. Roots were horizontally cut into 1.5mm sections at the apical, middle, and coronal thirds, and the push-out test was performed using a universal testing machine with a tip speed of 0.5mm/min. The maximum load at failure (N) was recorded for each section, and the failure mode was assessed under magnification. Additional palatal roots of twelve molars (n=3) were prepared as above. Roots were dried and fractured before imaging with scanning electron (SEM) microscopy and energy-dispersive X-ray (EDX) spectroscopy.

Results: Kruskal-Wallis test revealed a significant effect of concentration on bond strength ($p<0.001$), with significantly higher values in the 12% group ($p<0.0001$). Significant differences based on the location were noted in all the groups except 12% ($p=0.17$). Cohesive and mixed failure modes were predominant in all the groups except the 6% group. The SEM/EDX images confirmed surface alteration of conditioned dentine with chemical changes that involved the detection of Si compared to the non-conditioned dentine.

Conclusions (mandatory): Using soluble silicate solutions as a dentine conditioning agent may improve the adaptation of HCSS to radicular dentine.

GE140 | MANAGING ANTERIOR TOOTH TRAUMA WITH DYSCHROMIA AND OPEN APICES: A COMPREHENSIVE CLINICAL APPROACH

B. DOUMARI [1], K. LASLAMI [1], S. DHOUM [1], M. JABRI [1]

[1] Department of Conservative Dentistry and Endodontics - University of Hassan II, Faculty of Dental Medicine, Casablanca,, CASABLANCA, MOROCCO

Aim: This presentation aims to explore the management strategies for anterior teeth affected by trauma resulting in dyschromia and open apices. It will discuss the challenges of treating these conditions and highlight the importance of apexification and aesthetic restoration techniques in achieving optimal outcomes.

Introduction: Trauma to anterior teeth, especially in young patients, can lead to both functional and esthetic complications. Anterior teeth with open apices are particularly vulnerable to pulp necrosis, periapical pathology, and dental discoloration (dyschromia). The management of such cases involves a combination of endodontic and restorative treatments, aiming to restore both the health and appearance of the affected teeth. The challenge lies in effectively combining techniques to address these multifaceted issues.

Case Presentation: A 19-year-old male patient presented with pain in the maxillary anterior region. His medical history revealed no significant systemic concerns, and clinically, he showed mild gingivitis. On occlusal examination, the patient exhibited Class I skeletal occlusion and Class I Angle occlusion with both canine and molar relationships bilaterally.

Radiographic images revealed recurrent acute periapical abscesses in the maxillary central incisors (teeth 11 and 21), with open apices and signs of pulp necrosis. Given the patient's esthetic concerns and functional impairment, a treatment plan was formulated, including **apexification using Biodentine** (apical plug), **internal bleaching (Power Whitening with 37% Carbamide Peroxide)**, and **aesthetic restorations** for teeth 11 and 21.

Discussion: pexification is an effective treatment for teeth with open apices resulting from trauma. Using materials like Biodentine, an apical plug is placed to induce root canal closure and prevent further complications like root resorption. Alongside apexification, internal bleaching addresses the discoloration caused by trauma, restoring the natural appearance of the teeth. The combination of these treatments improves both tooth vitality and esthetics, helping to restore function and the patient’s smile.

Clinical Relevance: Managing anterior tooth trauma with dyschromia and open apices requires an integrated treatment approach. Apexification plays a crucial role in achieving apex closure, while aesthetic treatments restore the tooth’s appearance. This case emphasizes the importance of personalized treatment planning, as each traumatic case presents unique challenges. Long- term follow-up is essential to ensure that the treated teeth remain functional and esthetically acceptable.

Term follow-up is essential to ensure that the treated teeth remain functional and esthetically acceptable.

GE141 | Diagnosis and Endodontic Management of Accessory Cusps: A Case Series

UNIVERSITY OF LIVERPOOL

Sanapar Phadungcharoen[1], Ahmed Elmatary[1], Nicholas Longridge[1], Emad Moawad[1], Fadi Jarad[1]

[1] Department of Restorative Dentistry, School of Dentistry, University of Liverpool, Liverpool, United Kingdom

Aim: To present two clinical cases highlighting the diagnosis and management of accessory cusps, emphasising the varied endodontic considerations.

Introduction: Accessory cusps and supernumerary roots are rare dental anomalies. These anatomical variations can lead to diagnostic challenges and clinical complications such as aesthetic concerns, increased caries risk and difficulties in endodontic management.

Case 1: A 34-year-old female presented with aesthetic concerns and cold sensitivity in the upper right second premolar (#15). Clinical examination revealed a disto-buccal accessory cusp, and CBCT confirmed the presence of an additional pulp horn within the cusp. As the accessory cusp extended subgingivally toward the crestal bone, a surgical approach was required for adequate access. A small 2 sided flap was raised to fully visualise the accessory cusp, and the cusp was resected. Vital pulp therapy are then performed to maintain pulpal vitality following resection.

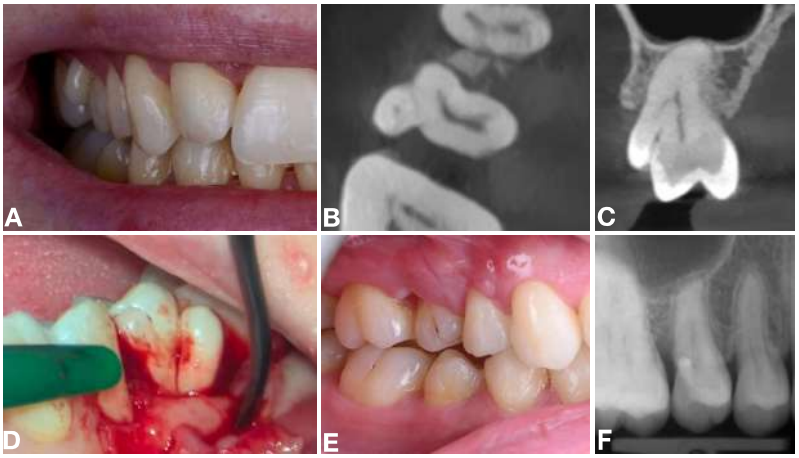

Fig. 1: Preoperative intraoral photograph of the upper right second premolar (#15) (A), preoperative CBCT (B & C), raised two-sided flap to visualise the accessory cusp on tooth (D), 2-week postoperative photograph (E), and postoperative radiograph (F).

Case 2: A 15-year-old female presented with spontaneous pain in the lower left second molar (#37), indicating symptoms of irreversible pulpitis. CBCT revealed a pulp horn extending into a mesio-buccal accessory cusp with a supernumerary root and adjacent caries. The imaging also demonstrated close proximity of the root apices to the inferior alveolar nerve. As the pulp tissue at the canal orifices appeared healthy on access, full pulpotomy with biodentine XP was carried out to preserve pulp vitality, thereby reducing the risk of iatrogenic injury to the inferior alveolar nerve that would be associated with root canal treatment.

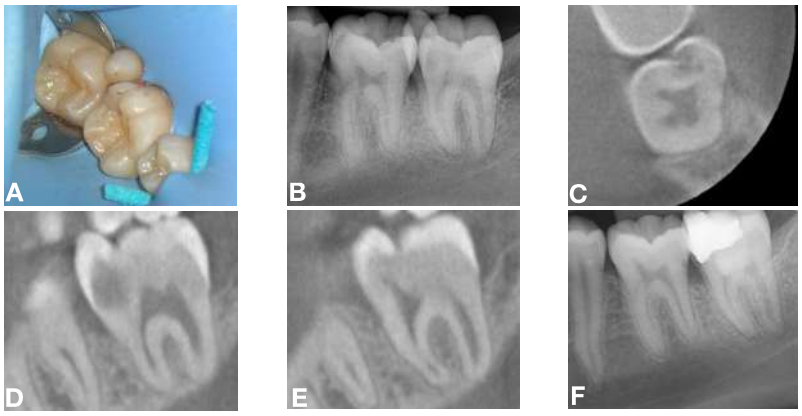

Fig. 2: Preoperative intraoral photograph of the lower left second molar (#37) (A), preoperative radiograph (B), preoperative CBCT (C-E) and postoperative radiograph (F).

Discussion: Accessory cusps with independent root development present unique challenges in endodontic treatment. While most paramolar tubercles do not contain pulp or form additional roots, some may be associated with supernumerary roots, as demonstrated in Case 2. Despite differences in location and anatomical complexity, both cases required CBCT for accurate diagnosis and were successfully managed with vital pulp therapy based on the clinical appearance of the pulp on access.

Conclusion & Clinical relevance: Accessory cusps may conceal pulpal extension, complicating diagnosis and treatment. These cases highlight the importance of CBCT imaging and individualised treatment strategies in managing accessory cusps and their anatomical variations.

References: 1. AAE Position Statement on Vital Pulp Therapy. J Endod. 2021;47(9):1340-4. 2. Patel S, Brown J, Semper M, Abella F, Mannocci F. European Society of Endodontology position statement: Use of cone beam computed tomography in Endodontics: European Society of Endodontology (ESE) developed by. Int Endod J. 2019;52(12):1675-8. 3. Kazak M, Çolakoğlu G, Mehmet, Elçin M, Somturk E, Gunal S. Examination of Paramolar Tubercles in Turkish Population Using Cone Beam Computed Tomography Estudio de los Tuberculos Paramolares en una Población Turca Mediante Tomografía Computarizada de Haz Cónico. International Journal Of Morphology. 2017;35:1416-14211416.

GE142 | COMPARISON OF DIFFERENT TECHNIQUES FOR REMOVAL OF CALCIUM HYDROXIDE FROM STRAIGHT ROOT CANALS: AN IN VITRO STUDY

N. REVAZISHVILI [1], E. FARMAKIS [2]

[1] *Department of Endodontics, Dental School of Athens, Athens, GREECE*
[2] *Department of Endodontics, Dental School of Athens, Athens, GREECE*

AIM: Aim: This study investigates the effectiveness of various techniques for the removal of calcium hydroxide from straight root canals in an in vitro setting. Calcium hydroxide is widely used as an intracanal medicament during endodontic treatments due to its antimicrobial properties, but its complete removal before obturation remains a challenge. The research compares manual, mechanical, sonic, and ultrasonic activation methods, including Passive Ultrasonic Irrigation (PUI), Eddy, EndoActivator, UC One, XP-Endo Finisher and the Master Apical File (MAF) technique in removing calcium hydroxide. Three different calcium hydroxide formulations were used pure powder, Calasept and Ultracal XS

Methodology: Methodology: Endodontic resin blocks with standardized grooves apically were used to simulate clinical conditions and allow controlled assessment. Residual material was quantitatively evaluated using digital image processing and statistical modeling

Results: Results: The findings indicate that PUI, Eddy, and UC One were the most effective in removing calcium hydroxide from the apical third, whereas EndoActivator, MAF, XP-Endo Finisher demonstrated lower efficiency. Statistical analysis revealed significant differences between methods and materials, emphasizing the impact of calcium hydroxide formulation on removal efficacy

Conclusions (mandatory): Conclusion: Despite the enhanced efficacy of ultrasonic and sonic activation methods, none of the tested techniques achieved complete removal, reinforcing the need for improved irrigation activation strategies. The study identifies limitations, including the use of in vitro artificial models that may not fully replicate clinical conditions, and suggests further in vivo studies to validate findings. Future research should explore optimized activation times, alternative irrigants, and combined approaches to enhance calcium hydroxide removal efficiency and improve clinical outcomes in root canal therapy.

GE143 | EFFECT OF TWO DUAL-ACTION IRRIGATING SOLUTIONS FOR CONTINUOUS CHELATION ON DENTINE MICROHARDNESS.

R. CASTAGNOLA [1], G. PLOTINO [2], L. SCALA [1], N.M. GRANDE [1], F. DELL' AQUILA [1], L. MARIGO [1, 3]

[1] *Department of Head and Neck and Sensory Organs, Università Cattolica del Sacro Cuore, 00168 Rome, Italy., Rome, ITALY*
[2] *Private practice, Via Calabria 25, 00187, Rome, Italy, Rome, ITALY*
[3] *UOC of Dental Clinic, Department of Neurosciences, Sensory Organs and Chest, Fondazione Policlinico Universitario A. Gem, Rome, ITALY*

AIM: This study aimed to compare the effect on the dentine microhardness of three different endodontic irrigation protocols (NaOCl+EDTA, Dual Rinse, Triton).

Methodology: 12 single-rooted and single-canal teeth were selected for this study. After access cavity preparation, a size #10 K-file was used to confirm apical patency. The working length (WL) was established by withdrawing 1 mm from the apical foramen. In all experimental groups, a glide path was accomplished by scouting a size #15 K-file up to the WL.
For the mechanical preparation, Reciproc R25 and R40 instruments were used according to the manufacturer's instructions. During instrumentation, 2,5 mL of saline solution was used. Each samples were sectioned and three dentin discs of 3 mm (apical, medium and coronal parts) were obtained.
Then, the discs were irrigated as follows:
Group 1 (n=12): 10 ml of 5.25% NaOCl for 5 min and + 5 mL of 17% EDTA for 2 min.
Group 2 (n=12): 15 ml of Dual Rinse for 7 min.
Group 3 (n=12): 15 ml of Triton for 7 min

The dentine microhardness of discs was measured with a Vickers indenter at x50 magnification, with a load of 50g, slope of 10 gf/s and a dwell time of 15 seconds before and after irrigation. Three indentations were performed on each sample. Then, the discs were observed using an electronic scanning microscope. The data were analysed using the Wilcoxon, Kruskal-Wallis, Mann-Whitney and Friedman tests.

Results: In general, there was a statistically significant reduction of microhardness before and after irrigation in all the groups ($p<0.05$). Statistically significant difference was found between Group 1 and 3 and Group 1 and 2 ($p<0.05$). There were no statistically significant differences among apical, medium and coronal discs ($p>0.05$).

Conclusions (mandatory): The dual-action irrigating solutions showed a reduced effect on dentine microhardness compared with traditional irrigation protocol.

GE145 | MANAGEMENT OF A TOOTH DIAGNOSED WITH OEHLERS CLASS IIIA DENS INVAGINATUS: A CASE REPORT

S. CAN [1], B. HELCAVIOGLU KIVANC [1], S. TÜRE [1]

[1] *Gazi University Faculty of Dentistry, Ankara, TURKEY*

AIM: Dens invaginatus is a developmental dental anomaly resulting from the folding of dentin and enamel into the dental pulp. Treating teeth with this anomaly poses challenges due to irregular canal anatomy and difficulties in accessing the invagination canal. This case report presents treatment approach for maxillary right lateral incisor with Oehlers Class IIIa dens invaginatus with periapical lesion.

Methodology: A 22-year-old male patient reported pain and vestibular swelling. Intraoral examination revealed a chronic apical abscess, with positive responses to percussion and palpation tests. Periapical radiography and CBCT-based radiographic examination revealed a large periradicular lesion with Oehlers Class IIIa tooth anatomy. During the first session, entry to both the main canal and the invaginatus canal was successfully established through the access cavity. Chemomechanical debridement was performed and the root canals were filled with calcium hydroxide medicament. In the same session, intraoral abscess drainage was executed. Despite six dressing sessions, complete healing of the apical abscess was not achieved, necessitating the need for a surgical approach. One day prior to periapical surgery, canals were irrigated with ultrasonic activation during the final irrigation. The main root canal was filled with a bioceramic sealer and gutta-percha, while the invaginatus canal was filled with MTA. Surgical treatment involved the elevation of a full-thickness mucoperiosteal flap, total enucleation of the lesion, and approximately 3 mm of root apex resection. Biopsy results identified the lesion as a radicular cyst. At the six-month follow-up, healing in the apical region was observed, with no clinical or radiographic symptoms detected. The patient's follow-up appointments are ongoing.

Results: • The management of dens invaginatus cases can be challenging.
• Alternative approaches should be utilized for filling canals that cannot be filled using conventional methods.
• Alternative approaches should be considered for teeth that have not achieved complete healing.

GE146 | AUTOTRANSPLANTATION OF IMMATURE WISDOM TEETH TO EXTRACTED FIRST MOLAR USING 3D PRINTED REPLICAS: A REPORT OF TWO CASES

V. LE [1], A. NGUYEN [2]

[1] National Hospital of Odonto- Stomatology, Hanoi, Hanoi, VIETNAM
[2] National Hospital of Odonto- Stomatology, Hanoi, Hanoi, VIETNAM

Aim: This case report evaluates the clinical and radiographic outcomes of autotransplanting immature wisdom teeth to replace extracted first molars, utilizing 3D-printed replicas to enhance surgical precision.

Introduction: Autotransplantation is a viable option for replacing missing teeth, particularly in young patients. Immature wisdom teeth serve as effective donor teeth due to their potential for continued development. Advances in 3D printing technology enable the creation of precise donor tooth replicas, improving surgical planning and execution.

Case Presentation: Two patients, both aged 16, underwent autotransplantation of immature wisdom teeth (CVEK stage 2 or 3) to replace extracted first molars. Preoperative evaluations and 3D-printed replicas were used to guide the surgical procedures. Follow-ups, including vitality tests and CBCT scans, were conducted at 6, 12 and 18 months postoperatively. At the six-month follow-up, the autotransplanted teeth responded positively to cold tests, CBCT scans at 6,12 and 18 months showed evidence of bone healing, establishment of the periodontal ligament space, and continued root development.

Discussion: The use of immature wisdom teeth for autotransplantation offers significant benefits, including the potential for continued growth and successful integration. The incorporation of 3D-printed replicas enhances surgical precision, reducing complications and improving outcomes. The cases demonstrate successful transplantation with favorable clinical and radiographic results over the follow-up period.

Clinical Relevance: These two cases underscore the potential of combining autotransplantation with 3D printing technology to enhance dental surgery outcomes, demonstrating the feasibility and effectiveness of this innovative approach.

GE147 | ROOT CANAL TREATMENT OF A MANDIBULAR SECOND MOLAR WITH TWO EXTERNAL CERVICAL RESORPTIONS

C. SANCHEZ PADILLA [1], R. PEREZ ALFAYATE [1], R. ESTEVEZ [1], A.J. CONDE [1], G. LOROÑO [1]

[1] *Universidad Europea de Madrid, Madrid, SPAIN*

AIM: External cervical resorption is a destructive process which initiates in the external zone of the root and progresses apically and circumferentially surrounding the pulp which is protected by the predentine, without affecting it, except in the most advanced cases.

Methodology: A diagnosis of normal pulp with symptomatic apical periodontitis was obtained. A CBCT was performed to confirm and plan the treatment of this external cervical resorption. According to Patel's classification of 2017, the mesial resorption was a 3bp type and the distal 2ad. After studying different options, the treatment decided was a nonsurgical conservative treatment. In the first appointment, the cavity was cleaned and the resorption cleaned until bleeding was controlled; canals were localized and after constant irrigation with sodium hypochlorite, calcium hydroxide was placed. In the second appointment, the chemicomechanical preparation and obturation with continuous wave of condensation until the middle third of the root was done. The middle and coronal third as well as the resorption were sealed with Biodentine. At 6 months the patient was assymptomatic with signs of periapical health.
At 12 months, the patient showed gingival inflammation, and a CBCT was performed, in which recurrence of the resorption was observed. Surgery was performed in order to remove the resorptive tissue, and sealed with composite. 3 years later, the tooth remains asymptomatic with signs of periapical health.

Results: -CBCT is crucial to have a correct diagnosis and plan the best treatment option with the most appropriate techniques for each case.
-It is very important to inform the patient about the prognosis of the case and the importance of doing long term controls to detect possible recurrences.
-The prognosis for this pathology may be poor, and very frequently there is recurrent resorption.

GE151 | THE EFFECT OF THE USE OF LUTING AGENTS ON THE PULP OF VITAL TEETH. A SYSTEMATIC REVIEW.

G. ANDREOU [1], M. DEDE [1], N. KEREZOUDIS [1]

[1] *Department of Endodontics, School of Dentistry, National and Kapodistrian University of Athens, Athens, GREECE*

AIM: To analyze the biocompatibility and effect of contemporary luting cements on vital pulp through a systematic literature review.

Methodology: A research of the electronic databases Pubmed, Wiley Online Library and Science Direct from 2000- 2025 was conducted using the keywords: “luting cements”/ “luting materials”/“luting agents” AND “pulp”/ “pulp response”/“pulp vitality”. This resulted in 1058 articles which were then screened based on relativity from the Title and Abstract. This way, 37 articles were selected and after the removal of duplicates, 32 articles were eligible for inclusion. The studies analyzed included in vitro research and clinical trials, examining glass-ionomer cements (GIC), resin-modified glass-ionomer cements (RMGIC), zinc phosphate cements, zinc polycarboxylate, and various resin cements.

Results: Most studies focused on the cytotoxicity of resin cements and RMGIC. Concerning the latter, their adverse effects have to do with monomer release due to saliva contamination during cementation or too much drying. Resin cements offer a wide range of options, with dual-cure cements preferred due to higher polymerization rates and fewer residual monomers. Furthermore, self-adhesive resin cements resulted in reduced sensitivity but contained more free monomers, posing greater long-term toxicity risks. While some studies indicated HEMA-free resin cements to be more harmful, others concluded that all resin cements can damage the pulp. Regarding conventional luting cements (GIC, zinc phosphate, zinc polycarboxylate), they appeared to have no adverse effects, though only two studies met inclusion criteria.

Conclusions (mandatory): There is a broad selection of different luting cements and the choice of the most suitable one depends on the specific clinical case. The different protocols for their application to dentin may interfere with their cytotoxicity. More studies with better simulating clinical conditions are needed to resolve conflicting results and enable better-informed decisions for a safer and biologically-wise luting cement use.

GE152 | INTENTIONAL REIMPLANTATION: AN UNDERAPPRECIATED ENDODONTIC SURGICAL THERAPY

R. GOLBANO GOMIZ [1], H. CORNUT [1]

[1] *UNIVERSITÉ PARIS CITÉ, PARIS, FRANCE*

Intentional replantation (IR) is an endodontic surgical treatment that involves the atraumatic extraction of a tooth to perform an apical resection, preparation and retrofilling of its roots, and ultimately replanting it in its original position.

Although it is described and perceived by practitioners as a last resort, it is often overlooked in treatment plans, which can lead to permanent tooth extraction. IR suffers from limited influence in dentistry and is frequently compared to implantology. However, in certain cases, it offers a viable alternative to implants and has advantages that implantology cannot provide. Understanding the biological mechanisms involved is crucial for proper management of the treatment. The survival of the periodontal ligament cells and the healing of the various tissues involved will determine the key steps of the protocol and the success of the treatment.

While it is mostly used as a last resort, its range of indications is actually much broader. Advances in the search for superior biomaterials and a better understanding of the tissues involved are gradually improving the success rate of this therapy and expanding its indications.

The objective of this work is to guide practitioners in their decision-making process and help them adopt this therapy with confidence in their clinical practice.

GE153 | EFFECT OF DIFFERENT CONTINUOUS CHELATING PROTOCOLS ON SEALER PENETRATION INTO ROOT DENTIN AND PUSH-OUT BOND STRENGTH

P. DUIC [1], A. IVICA [2], I. SALINOVIC [2], S. JUKIC KRMEK [2], I. MILETIC [2]

[1] *Community Health Center Zagreb East, Zagreb, CROATIA*
[2] *University of Zagreb, School of Dental Medicine, Zagreb, CROATIA*

AIM: To assess the effect of sequential versus continuous chelation in root canal irrigation on the penetration depth and push-out bond strength of a calcium silicate-based sealer.

Methodology: Eighty single-rooted teeth were selected and prepared using Reciproc R25. The teeth were randomly assigned to four groups according to the irrigation protocol used (n = 20): Root canals in the two sequential chelation groups were irrigated with sodium hypochlorite (2% NaOCl) during instrumentation. Subsequently, 17% EDTA was administered, either with a needle or with additional ultrasonic activation (Irrisafe, 30s, 35% power). In the continuous chelation groups, root canals were irrigated using a mixture NaOCl and Dual Rinse HEDP during and after instrumentation. Ten samples from each group were used for sealer penetration analysis and obturated with CeraSeal mixed with Fluo-3 dye and gutta-percha using a matched cone technique. The rest of the samples were filled without fluorescent dye and used for push-out test. Data was analysed using two-way ANOVA. The significance level was set at $p < 0.05$. Student's t-test was used to compare the groups within ultrasonic activation or within needle irrigation.

Results: No significant differences in sealer penetration were observed between sequential and continuous irrigation protocols in the apical region ($p > 0.05$). However, sealer penetration was significantly higher at the middle level ($p < 0.001$). The highest push-out bond strength values were recorded when continuous chelation was combined with ultrasound, both in the apical and middle regions of the root ($p < 0.001$).

Conclusions (mandatory): While sealer penetration in the apical region was not significantly influenced by the irrigation protocol, greater penetration was observed at the middle level. Additionally, the combination of continuous chelation and ultrasound resulted in the highest push-out bond strength values in both the apical and middle regions, suggesting that this approach may enhance the adhesive properties of the sealer.

This work was supported by the Croatian Science Foundation under the project number HRZZ-IP-2022-10-6065.

GE154 |DENS IN DENTE – conservative approach to the therapy

Marija Jurčević Grgić, DMD

Dental Clinic Zagreb, Perkovčeva 3, Zagreb, Croatia

AIM

Aim of this report is to show possibility of conservative therapy in treating dens invaginatus.

INTRODUCTION

Dens in dente (dens invaginatus) is rare developmental anomaly of the tooth. It occurs by invagination of the enamel organ into the dental papilla during odontogenesis. Lateral maxillary incisor is the most commonly affected.

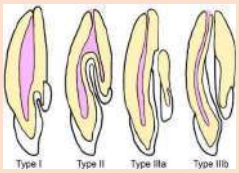

Oehler's classification of dens invaginatus

CASE REPORT

A female patient (age 17) referred to dental Clinic Zagreb due to change of color and periodically unspecific pain of upper left incisor. After the clinical and orthopantomogram examination suspicious morphology of upper left incisor was noticed. Patient was sent to make an oral x-ray of the affected tooth, and diagnosis of dens invaginatus was confirmed.







After initial access preparation three orifices were noticed. Working length was established by the apex locator (Endometer ES-04, e-lab) and the endodontic treatment was performed using hand and mechanical instrumentation canals were irrigated with 5% sodium hypochlorite and saline, and calcium hydroxide paste was placed as intermediate filling.

One week after, patient had no symptoms and endodontic treatment was finished – final irrigation with sonic activation (EndoActivator, Densply Sirona) and filing using gutta-percha and bioceramic cement (Sure-Seal Root, Sure endo).

DISCUSSION

Dens in dente is a dental anomaly that requires early diagnosis and intervention, and interferes with endodontic treatment. It can be present in various degrees of severity and it is prone to infection. The treatment options vary depending on type that is present from fissure sealants, root canal treatment to extraction.

CLINICAL RELEVANCE

Although dens invaginatus presents a challenge for clinician good diagnostic and cleaning techniques are crucial for conservative therapy prior to extraction (cone beam tomography, activated irrigation).

REFERENCES

OEHLERS FA. Dens invaginatus (dilated composite odontome). I. Variations of the invagination process and associated anterior crown forms. Oral Surg Oral Med Oral Pathol. 1957 Nov;10(11):1204-18 contd. doi: 10.1016/0030-4220(57)90077-4. PMID: 13477660.

Castelo-Baz P, Gancedo-Gancedo T, Pereira-Lores P, Mosquera-Barreiro C, Martín-Biedma B, Faus-Matoses V, Ruíz-Piñón M. Conservative management of dens in dente. Aust Endod J. 2023 Sep;49 Suppl 1:481-487. doi: 10.1111/aej.12763. Epub 2023 May 8. PMID: 37154212.

Siqueira JF Jr, Rôças IN, Hernández SR, Brisson-Suárez K, Baasch AC, Pérez AR, Alves FRF. Dens Invaginatus: Clinical Implications and Antimicrobial Endodontic Treatment Considerations. J Endod. 2022 Feb;48(2):161-170. doi: 10.1016/j.joen.2021.11.014. Epub 2021 Dec 11. PMID: 34902355.

GE 156 | ENDODONTIC TREATMENT IN PATIENTS ON BISPHOSPHONATE THERAPY-CASE REPORT

Anja Sesar, PhD, DMD, Specialist in Endodontics and Restorative Dentistry, Dental Polyclinic Zagreb, Croatia

AIM-This case report gives an overview of the factors that may play a role in the development of osteonecrosis of the jaw in patients treated with bisphosphonates and undergoing nonsurgical endodontic treatment as well as some recommendations for its prevention.

INTRODUCTION-Bisphosphonates (BPs) are nonmetabolized analogues of pyrophosphates that are often prescribed to treat patients with bone disorders, such as osteoporosis and Paget's disease. ORAL - therapy of osteoporosis, osteopenia, Paget's disease, osteogenesis imperfecta, fibrous dysplasia, chronic recurrent multifocal osteomyelitis, chronic kidney disease, kidney transplantation, rheumatoid arthritis INTRAVENOUS-therapy of various conditions associated with malignant diseases- hypercalcemia caused by cancers, treatment of bone metastases. The occasional but devastating adverse effect of these drugs has been described as bisphosphonate-related osteonecrosis of the jaw (BRONJ). PREVALENCE - oral bisphosphonates (0.1%-0.05%), intravenous (2%-10%). As this condition is debilitating and difficult to treat, all efforts should be made to prevent its occurence in patients at risk. The main triggering event is considered to be dental extraction. Even though nonsurgical endodontic treatment appears to be a relatively safe procedure, care remains essential.

CASE PRESENTATION- A 73-year-old patient was reffered to the Department of Endodontics for endodontic treatment of tooth 23. Medical history: - preparation for cardiology treatment, heart valve defects, heart arrhythmia, osteoporosis. Drugs: isoptin, martefarin, actonel - 5 years. The patient reports pressure pains in the area of the apex of the tooth 23 and sensitivity to vertical percussion. Clinical examination and X-ray analysis determined the presence of a periapical process and inadequate endodontic treatment of tooth 23. Revision with ProTaper Universal with instruments D1, D2, D3. Rinsing with 2.5% sodium hypochlorite (NaOCl). Instrumentation of root canals using ProTaper Next technique with instruments X1,X2,X3,X4, rinsing with 2.5% NaOCl. Final root canal rinsing protocol: 2.5% NaOCl 30 s, EDTA 60 s, 2.5% NaOCl 30s. Activation with EndoActivator. Root canal filling with a combination of AH Plus paste and gutta-percha using lateral condensation.



Fig. 1:Preoperative x-ray



2: Endodontic tretment



Fig 3: Irrigation



Fig 4: Root canal filling



Fig 5: Postoperative X-ray



Fig 6. X-ray after 6 months

DISCUSSION-Endodontic treatment does not presenting a significant risk for the development of BRONJ and is considered an alternative to tooth extraction. Caution is required during endodontic procedures because soft tissue injury (placing rubber dams) and damage to periapical bone tissue during mechanical canal instrumentation can trigger the development of BRONJ. Antibiotic prophylaxis is mandatory in: patients on intravenous bisphosphonates (th tumor), patients on oral bisphosphonates for more than three years, patients with chronic diseases (chronic kidney disease, uncontrolled diabetes, corticosteroid therapy). Recommendation before the endodontic procedure: disinfection of the oral cavity with 0.2% chlorhexidine solution.

CLINICAL RELEVANCE-BPs are a commonly and widely prescribed group of drugs used for the treatment of various bone patholo- gies. Nonsurgical endodontic treatment is a safe alternative to dental extraction which is the main trigger to BRONJ. However, caution is mandatory during nonsurgical endodontic treatment in these patients. More studies are needed to obtain further insight into the safety of nonsurgical endodontic treatment in patients at risk of BRONJ.

REFERENCES-

Marx RE. Osteoradionecrosis:a new concept of its pathophysiology. J Oral Maxillofac Surg. 1983;41(5):283-8

Lo JC, O'Ryan FS, Gordon NP, Yang J, Hui RL, Martin D et al. Prevalence of osteonecrosisof the jawin patientis with oral bisphosphonateexposure. J Oral Maxillofac Surg. 2010;68(2):243-53.

Segura-Egea JJ, Gould K, Hakan Sen B, Jonnasson P, Cotti E, Mazzoni A, Sunaj H, Tjaderhane L, Dummer PMH. European Society of Endodontology position statesment: the use of antibiotic in endodontics. Int Endod J 2018;51:20-5.

GE157 | Intentional Replantation of a Lesioned Upper Molar Tooth with Excessive Root Canal Filling: A Case Report

Dt. Begüm ONGUN, Doç.Dr. İsmail UZUN, Dt.Yarkın APA

Department of Endodontics, Ondokuz Mayıs University Faculty of Dentistry, Samsun, Türkiye

Aim: The aim of this case report is to discuss the application of intentional replantation in a maxillary molar tooth, where excessive filling in multiple canals resulted in radiolucent areas in the mesial root region, and when non-surgical root canal retreatment is deemed inappropriate, enabling the retention of the tooth in the oral cavity.

Introduction: The ideal root canal obturation should provide filling material that reaches the cemento-dentinal junction. The extrusion of filling materials beyond the radiographic apex is described as overfilling, which can occur owing to the lack of apical constriction, as a result of inflammatory apical root resorption or an incompletely formed root apex, and due to over-instrumentation because of errors in working length assessment .In cases where conventional root canal treatment fails or is not an option, several alternative procedures can be considered, including root canal retreatment, apical surgery (apicoectomy), and intentional replantation. Intentional replantation has been defined as the insertion of a tooth into its original alveolar socket after the tooth has been deliberately extracted for performing a quick repair/treatment, such as root-end filling or perforation repair. Because of improved operational efficiency, difficulty with surgical access, and the desire to avoid delicate anatomic structures,intentional replantation has been proposed as an additional method to resolve post-treatment endodontic disease in select cases.

Case Report: A 24-year-old systemically healthy female patient presented to our clinic for root canal retreatment of tooth number 16. Radiographic examination revealed excessive root canal filling in all three canals and the presence of radiolucent areas at the apex of the mesial root. Root canal retreatment was recommended for teeth numbers 15 and 16. Initially, the treatment for tooth number 15 was performed, but complete resolution of the patient's symptoms was not achieved. Upon the patient's second visit to our clinic, mild percussion sensitivity was observed in tooth number 16, but no severe pain complaints were reported. The patient was thoroughly informed about the condition of her tooth and the possible treatment options, and an appointment for intentional replantation was scheduled.
The procedure began with the administration of infiltrative anesthesia using 2% lidocaine. Once the adequate depth of anesthesia was confirmed, the supra-alveolar fibers were carefully dissected, and a circumferential separation was made around the tooth without damaging the surrounding tissues. During this process, the use of elevators was avoided to preserve the integrity of the periodontal ligament, and the tooth was atraumatically extracted from the socket using traditional extraction forceps. During extraction, the entire root, including the excessive gutta-percha filling, was carefully detached from the socket without any damage.
To minimize the extraoral time of the tooth, the resection procedure was initiated immediately after tooth extraction. Concurrently, ProRoot MTA, the retrograde filling material, was mixed and prepared for use. After resecting the excessive portions of the root, a cavity was created using a diamond-coated fissure bur for retrograde filling. The pre-mixed MTA was then carefully placed into the cavity using appropriate hand instruments. The socket was irrigated with saline, and the granulation tissue in the socket was atraumatically removed. Finally, the tooth was digitally placed into the socket in the axial direction, and the patient's own bite pressure was effectively utilized to seat the tooth into the socket. No splinting was required postoperatively.
Follow-up results showed that horizontal and vertical mobility, as well as the formation of pockets, decreased at the 1st and 3rd month controls, with noticeable healing in the tooth. At the 6-month and 1-year follow-ups, no symptoms were observed.

Discussion: Intentional replantation has emerged as a promising alternative with the potential to preserve the natural tooth structure in cases where surgical or non-surgical treatment options are not feasible. This method, particularly when supported by high survival rates and positive clinical outcomes, offers a cost-effective solution compared to single-tooth replacement options. It has been demonstrated that this treatment option provides both economic and functional advantages, particularly in challenging clinical cases.



Preoperative periapical radiograph



The image of the tooth after it was extracted from the socket



Size of the cleaned lesioned tissue



One-week follow-up periapical radiograph



Initial panoramic radiograph



One-year follow-up periapical radiograph

Clinical Relevance: The success of intentional replantation is based on an extraction process with minimal traumatic impact, effective irrigation, careful instrumentation, and a brief extraoral period. The patient's careful adherence to postoperative instructions also played a key role in the success of the treatment. This case demonstrates the necessity of intentional replantation, and the follow-up results obtained with this technique provide strong evidence that it is a viable and successful treatment alternative.

References:

1. Wang Y, Hofmann M, Ruf S, Zhang J, Huang Q. Intentional replantation and dental autotransplantation of mandibular posterior teeth: Two case reports. Medicine. 2023;102(46):e35822.
2. Becker BD. Intentional replantation techniques: a critical review. Journal of Endodontics.2018;44(1):14-21.
3. Stueland H, Ørstavik D, Handal T. Treatment outcome of surgical and non-surgical endodontic retreatment of teeth with apical periodontitis. International Endodontic Journal. 2023;56(6):686-96.



Intraoral one-month control photograph



Intraoral one-month occlusion control photograph

GE158 | RETREATMENT OF AN UPPER CENTRAL INCISOR WITH APEXIFICATION

C. AMUNDARAIN [1], R. ESTEVEZ [1], A. CONDE [1], G. LORONO [1], R. PEREZ-ALFAYATE [1]

[1] *Universidad Europea - Department Of Dentistry, Madrid, Spain*

AIM: The importance of good apical and coronal sealing in endodontic prognosis

Methodology: Endodontic failure remains a concern, often linked to coronal leakage and inadequate root canal sealing. Coronal microleakage is one of the primary reasons for reinfection, as bacterial ingress can compromise the periapical healing process. Poorly sealed root canals allow microbial contamination, leading to persistent periapical pathology despite initial treatment. Ensuring a proper coronal and apical seal is crucial to prevent bacterial re-entry and to promote long-term periapical health.

Managing endodontic treatment in teeth with open apices present significant challenges, particularly in achieving an adequate apical seal. Apexification has been the conventional approach for treating immature permanent teeth with necrotic pulps, involving the induction of an apical barrier to allow for subsequent obturation. Historically, calcium hydroxide has been widely used for this purpose, requiring multiple applications over an extended period. More recently, mineral trioxide aggregate (MTA) has gained prominence due to its superior biocompatibility and ability to provide a more predictable and faster apical barrier formation.

This clinical case describes the retreatment of a maxillary central incisor with an open apex, previously endodontically treated and restored with a metal post and a leaking crown. The patient was asymptomatic and referred by a general dentist for retreatment before a new prosthetic restoration. Radiographic examination revealed an apical radiolucent lesion, indicating persistent infection. The retreatment involved careful removal of the post, thorough canal disinfection, and sealing with biocompatible materials to ensure apical closure and prevent reinfection. This case underscores the importance of coronal sealing in long-term endodontic success and highlights the necessity of comprehensive assessment before prosthetic rehabilitation.

Results: -Management of apical closure in immature apices
-Importance in the selection of the adequate sealing material

BEZMIALEM VAKIF UNIVERSITY

GE160

APEXIFICATION TREATMENT OF PERMANENT TEETH WITH OPEN APICES USING MTA: A CASE SERIES

Selin Acer RA, Fuad Sadıqlı DDS, Fatma Nurefşan Gürsoy DDS, Gamze Nalcı Çalık Asst.Prof.

AIM - The aim of this case series is to present the successful apexification treatment of three permanent teeth with open apices using Mineral Trioxide Aggregate (MTA) and to evaluate their clinical and radiographic outcomes over a follow-up period of up to two years.

INTRODUCTION - Endodontic management of teeth with open apices presents a significant challenge due to the absence of an apical stop, which complicates obturation. This case series presents three cases where MTA was used successfully for apexification in non-vital teeth with open apices.

CASE PRESANTATION

CASE 1

A 28-year-old systemically healthy female patient presented with a complaint of pain upon biting in the maxillary left central incisor. Clinical examination revealed pain on percussion and slight mobility in tooth #21. Radiographic evaluation revealed an open apex and failure of initial root canal treatment.

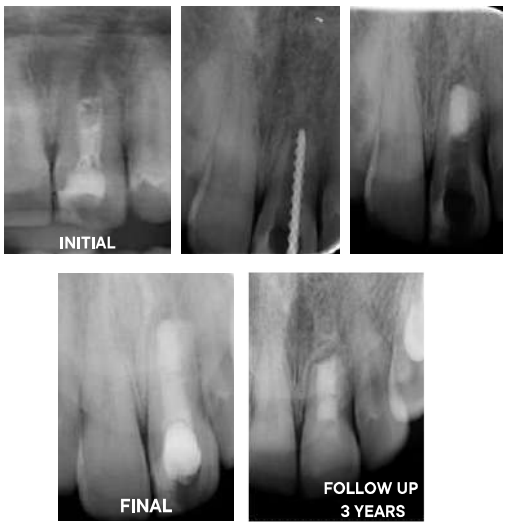

CASE 2

A 23-year-old systemically healthy female patient presented with a complaint of swelling in the maxillary anterior region. Clinical and radiographic examinations revealed tenderness on percussion in tooth #11, along with a periapical lesion and an open apex.

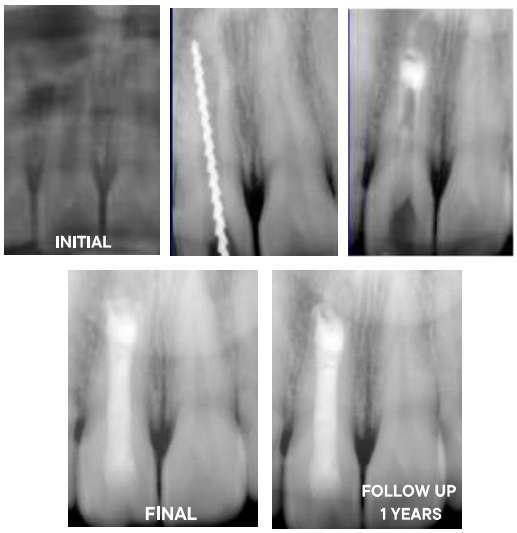

CASE 3

A 19-year-old female patient presented with a complaint of fractured tooth #21. Clinical and radiographic examination revealed a fracture involved the pulp, an open apex, and failure of initial root canal treatment. There was no tenderness on percussion.

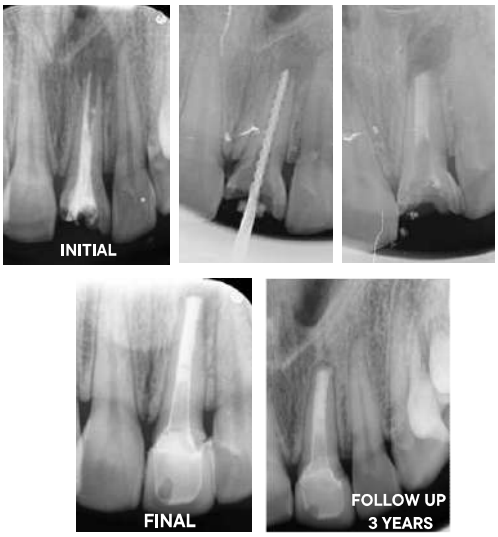

Radiographic evaluation of all cases revealed incomplete root formation and the presence of periapical lesions. In Cases 1 and 3, it was decided to perform root canal retreatment. The teeth were isolated with rubber dam after achieving local anesthesia.In the first session, following access cavity preparation, the working lengths were measured radiographically and recorded for reference.The canals were then gently cleaned with manual instruments 1 mm short of the root apex and irrigated with 3 ml of 5% sodium hypochlorite, 3 ml of 17% EDTA, and 3 ml of sterile saline. The canals were dried with sterile paper points and filled with calcium hydroxide and the access cavities were sealed with zinc phosphate cement. Two weeks later, all cases were asymptomatic.

In the second session, MTA (NeoMTA, NuSmile, USA) plug was placed in the canal with a carrier and pluggers, sized according to the apical diameter were used to condense the material against the barrier, to form apical plug with a thickness of approximately 4 mm. Correct placement of MTA was confirmed radiographically A sterile sponge pellet moistened with sterile water was placed over the canal orifice and the access cavity was sealed temporarily.

In Cases 1 and 3, the remainder of the canals were then obturated using cold lateral compaction technique with resin-based sealer (AH Plus, Dentsply Sirona, USA) and gutta-percha. In Case 2, the remainder of the canal was obturated using the warm vertical compaction technique (Elements Free, SybronEndo, USA). The final coronal restoration was completed with composite resin (Filtek Z250, 3M ESPE, USA).
Clinical and radiographic follow-ups were conducted at 6 months, 1 year, and 3 years to assess healing and the success of the procedure.

RESULTS - At each follow-up interval, all cases remained asymptomatic, with no signs of pain, swelling, or mobility. Radiographic evaluations demonstrated progressive periapical healing, with significant reduction in lesion size and evidence of root-end closure in all cases.

CONCLUSION - MTA apexification is a predictable and effective treatment approach for managing non-vital immature permanent teeth. The findings of this case series support the use of MTA as an apical barrier due to its excellent biocompatibility, superior sealing ability, and capacity to promote periapical healing.

CLINICAL RELEVANCE - Pulpal necrosis of an immature permanent tooth with an open apex poses a challenge for the clinician. The favorable clinical and radiographic outcomes in this case suggest that MTA may serve as a gold standard for apexification materials, surpassing conventional options.

REFERENCES

1. Felippe, W.T., Felippe, M.C. & Rocha, M.J. (2006) The effect of mineral trioxide aggregate on the apexification and periapical healing of teeth with incomplete root formation. *International Endodontic Journal*, 39, 2–9.
2. Simon, S., Rilliard, F., Berdal, A. & Machtou, P. (2009) The use of mineral trioxide aggregate in one-visit apexification treatment: a prospective study. *Journal of Endodontics*, 35, 570–576.
3. Andreasen, J.O., Farik, B. & Munksgaard, E.C. (2006) Long-term calcium hydroxide as a root canal dressing may increase risk of root fracture. *Dental Traumatology*, 22, 156–160.

GE162 | ENDODONTIC TREATMENT OF A TAURODONTIC PREMOLAR

Betty Dahan[12], Julien Po[123], Anne-Margaux Collignon[123],Marie Sevin[123]
[1] Université Paris Cité, Faculty of Dentistry [2] Dental Medicine Department, Hôpital Louis Mourier, Groupe GH Nord AP-HP [3] Santé Orale UMR1333

AIM OF THE CASE:

Highlight the complex anatomy of a taurodontic tooth and its implication for a root canal treatment procedure.

INTRODUCTION:

Taurodontism is defined as teeth with large pulp chambers in which the bifurcation or trifurcation is displaced apically, hence that the chamber has greater apico-occlusal height than in normal teeth and, lacks the constriction at the level of cemento-enamel junction (CEJ). Other specificity is the distance from the trifurcation or bifurcation of the root to the CEJ is greater than the occluso-cervical distance(1).



. TENNANT RD. Taurodontism. *Dental digest* 1966 ;72 :355-357.

Its prevalence is inferior to 1% of the global population and it is frequently associate to systemic malformations. Since this definition only concerned molars, it does not apply to premolars, which is the focus of this case(2)

CASE PRESENTATION :

A 13-year-old male, classified as ASA1, visited his general practitioner (GP) due to irreversible pulpitis in the second maxillary right premolar. The GP conducted an emergency pulpotomy.
Given its unique radicular anatomy, the GP entrusted us with completing the root canal treatment.

At the time of our consult:

Clinical observation: no pain on percussion test, the tooth responded positively to thermical test,
Radiographic examination: we observed the increase of the pulp chamber and the thightness of the roots witch lead us to the taurodontism diagnosis (1).
Pulp diagnosis: previous initiated treatment.
Periapical diagnosis : asymptomatic apical periodontontitis.

Treatment:

Under local anesthesia, rubber dam and dental microscope magnification (25x), a rotation continue system was used to instrument both canals (Until Protaper F2 Dentsply). After using each instrument, the canals were irrigated with sodium hypochlorite 3%. We also activated a final solution of EDTA 17% and sodium hypochlorite previously to root sealing.
Root canals were obturated with gutta-percha cones 4% (2) and bioceramic sealer Bioroot flow septodont. (3) The tooth was temporarily restored with a CVI, and the patient was readdressed to his dentist.

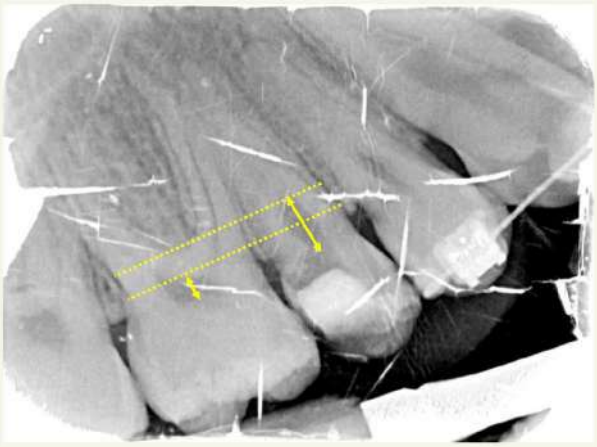

Pre operatory radiography with the dimension analisis of the pulp chamber(1)



Per operatory radiography to control gutta-percha adjustment(2)

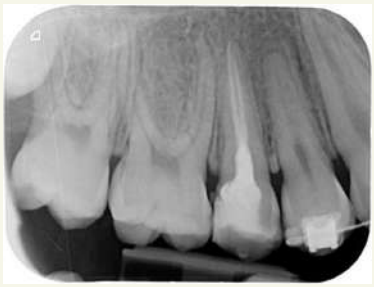

Post operatory radiography (3)

DISCUSSION:

First difficulty encountered was locating both canal orifices because of their specific anatomy. To solve this problem we use microscope magnification(3).
Second arduousness was the narrowness of both canals. The stake was to achieve an adequate shaping that would allow us proper disinfection without risking an instrumental fracture. To that we prefer an instrumental sequence permitting progressive shaping to a single instrument method.
Finaly, due to the tightness of the pulp chamber added to the apical localization of both orifice canals, we were unable to successfully insert gutta-percha with a 6% taper. So, we decided to use gutta-percha with a 4% taper sealed with bioceramic

CONCLUSION:

With the right analysis pre operatory and the good technical support, the challenge provide by the root treatment canal of a taurotondic teeth has been manage successfully.

References:
Int Endod J. 2008 May; (1) H. Jafarzadeh1, A. Azarpazhooh2 & J. T. Mayhall3 (1)
Camille Cia. Le taurodontisme : vers une nouvelle définition ?. Sciences du Vivant [q-bio]. 2018.(2)
Asian J Surg. 2024 Feb; Suqian Shen ,Le Lu , He Liu(3)

GE164 | DO DOCTORS MANAGING TRAUMATIC DENTAL INJURIES USE ACCEPTED GUIDELINES?

C. ROSE [1], A. HAMILTON [2], P. AO [3], K. HAR [4], J. KILGARIFF [5]

[1] *Dundee Dental Hospital, Dundee, UNITED KINGDOM*
[2] *Dundee Dental Hospital, Dundee, UNITED KINGDOM*
[3] *Dundee Dental Hospital, Dundee, UNITED KINGDOM*
[4] *Dundee Dental Hospital, Dundee, UNITED KINGDOM*
[5] *Dundee Dental Hospital, Dundee, UNITED KINGDOM*

AIM: In recent months, there was evidence that some patients with traumatic dental injuries (TDIs) being managed by hospital doctors in Scotland were presenting to the dental department with inappropriate treatment or delayed presentation. The aim of this research was to analyse if doctors working in an A&E department were aware of and using accepted international guidelines in the management of patients with traumatic dental injuries.

Methodology: A questionnaire was designed and disseminated via Microsoft Forms to all doctors working in a hospital A&E department. It determined the frequency of which these injuries were being seen by the doctors and their awareness of any TDI related guidance, this was further subdivided based on the doctor's grade (Junior, midgrade and consultant). Two weeks were allowed for responses.

Results: A total of 20 doctors responded to the questionnaire, out of a total of 60 working in the department. TDIs were seen frequently, with 90% of doctors seeing these injuries at least monthly. The majority (95%) of A&E doctors were unaware of any guidelines relating to the management of TDIs. Only one respondent was aware of guidance, who was currently in a midgrade position.

Conclusions (mandatory): Traumatic dental injuries are seen frequently by doctors working in A&E, though many are unaware of any accepted international guidelines related to the management of these patients. Given that A&E doctors have a significant role in the management of these patients, there is potential for inappropriate management of TDIs and possible delayed presentation to dentists if there is a lack of awareness regarding guidance, this in turn may compromise patient outcomes. In order to ensure best practice our next steps involve piloting an educational intervention to highlight TDI guidelines to medical colleagues managing these injuries.

GE165 | REGENERATIVE ENDODONTICS IN INFLAMMATORY EXTERNAL ROOT RESORPTION

M. CONTRERAS BENITO [1], R. PEREZ ALFAYATE [2], R. ESTEVEZ LUAÑA [3], A. CONDE VILLAR [4], G. LOROÑO GOICOECHEA [5]

[1] *Universidad Europea De Madrid, Madrid, Spain*
[2] *Universidad Europea De Madrid, Madrid, Spain*
[3] *Universidad Europea De Madrid, Madrid, Spain*
[4] *Universidad Europea De Madrid, Madrid, Spain*
[5] *Universidad Europea De Madrid, Madrid, Spain*

AIM: The incidence of inflammatory external root resorption after an avulsion is 23.2% according to the meta-analysis by Souza 2018. It is characterized by the presence of eroded areas of cementum and dentin, which may be associated with pulp necrosis and infection

Methodology: 18-year-old patient who came to the clinic with pain for a week in tooth 1.1. This is an incisor that suffered trauma and was avulsed. It was reimplanted after more than 24 hours, during which the tooth was kept dry. The diagnosis was pulp necrosis and symptomatic apical periodontitis. Radiographically, there was evidence of inflammatory external root resorption. A decision was made to perform regenerative endodontics. In the first session, an opening was made, disinfected with sodium hypochlorite, working length was established, and calcium hydroxide was placed. After 4 weeks, the patient showed no symptoms. Bleeding was induced, and biomaterial was placed in the coronal third. At the 6-month- follow-up, there is a tendency towards healing.

Results: Regenerative endodontics has the potential to treat avulsed teeth and inflammatory root resorptions. Saoud described a series of 3 cases with the same diagnoses resolved with regenerative endodontics. Regenerative endodontics can aid in the propagation of stem cells and thus initiate the repair process.

GE167 | COMPARATIVE IN VITRO ANALYSIS OF SHAPING CAPACITY IN CURVED ROOT CANALS: PROTAPER GOLD AND HYFLEX CM

O.A. DIACONU [1], L.M. GHEORGHITA [1], A.D. POPESCU [1], A.G. GHEORGHE [1], C. DIACONU [1], A.C. BANICA [1]

[1] *University of Medicine and Pharmacy, Faculty of Dentistry, Endodontic Departement, Craiova, ROMANIA*

AIM: The purpose of this in vitro study is to compare the ability of the rotary instruments, ProTaperGold and HyFlex CM, to shape the root canals with medium and severe curves on extracted teeth.

Methodology: This experimental study was performed on 24 extracted maxillary and mandibulary molars without root resorption. Chemo-mechanical treatment was performed only at the mesio-buccal and disto-buccal canals of the upper molars, but also at the mesio-lingual and mesio-buccal canals of the lower molars. The canals were divided into two groups (n = 28 each) and prepared with ProTaper Gold or HyFlex CM, using the VDW Gold Reciproc Endomotor. The fracture of the instruments, the reduction of the working length, and time needed for preparation were evaluated. The reduction of the working length was evaluated by making the difference between the initial working length and the final working length with pre-and post-instrumentation with rotary files on X-rays and Kodak Dental Imaging Software. The preparation time was measured in seconds using the Eurochron Timer EDT 9000 Schwarz timer.

Results: Teeth prepared with HyFlex CM rotary files showed a lower reduction in working length (average = 0.15 mm) compared to those prepared with ProTaper Gold (0.22 mm), with the differences being statistically insignificant. During the preparation of 56 canals, one ProTaper Gold instrument and one HyFlex CM file broke, with the fractures occurring after the second and third uses, respectively. Regarding preparation time, the shortest duration was achieved with the HyFlex CM system (960 seconds), compared to the ProTaper system (1123 seconds), with again, the differences being statistically insignificant.

Conclusions (mandatory): Canal preparation using the two Ni-Ti rotary systems did not result in significant alterations to the root canal anatomy or working length. We can conclude that ProTaper Gold and HyFlex CM are comparable in their efficiency for shaping medium and severe curves.

GE170 | LASER-ASSISTED ENDODONTIC SURGERY

P. SU [1]

[1] *Dentique Dental Surgery, Kuala Terengganu, MALAYSIA*

AIM: To appeal everyone that we can still perform root end surgery on posterior tooth with the help of laser technology: laser-assisted apicoectomy.

Methodology: A patient was referred for management of failed endodontically retreated posterior tooth. Most dentists upon hearing that endodontic retreatment failed, and it's a posterior tooth, will tend to pass a death sentence on that tooth even though it is still firm and the structure is still good and functional. Most probably this is because many think that it is not possible to perform root end surgery on posterior tooth. Laser-assisted apicoectomy and photobiomodulation was performed on patient. Bone healing and radiographic changes were observed in just 3 months instead of 6 months.

Results: - why root canal retreatment could still fail
- why apicoectomy is very successful and predictable
- why healing is so fast in laser-assisted treatment
- how to do laser-assisted apicoectomy

GE172 | Apexification Using Mineral Trioxide Aggregate in a Maxillary Central Incisor with an Open Apex: One-Year Clinical and Radiographic Follow-Up

Ilgenli I[1], Evren S[1]

[1]Ege University Faculty of Dentistry, Department of Endodontics, Izmir, TURKEY

AIM - To present the clinical and radiographic outcomes of apexification treatment using mineral trioxide aggregate (MTA) in a maxillary central incisor with an open apex and extensive periapical lesion, highlighting its regenerative potential and sealing efficacy.

INTRODUCTON

Apexification is a widely accepted procedure for inducing apical barrier formation in necrotic teeth with open apices. Traditional calcium hydroxide treatments, although effective, often require extended time and pose a risk of root fracture. MTA has emerged as a preferred alternative due to its superior biocompatibility, sealing ability, and potential to promote osteoconduction. Recent studies underscore MTA's success in managing teeth with open apices and large periapical lesions.

CASE PRESENTATION

A 23-year-old healthy male was referred to our clinic with a diagnosis of chronic apical periodontitis in tooth #11. Radiographic evaluation revealed an open apex with a large periapical radiolucency.

After endodontic access and working length determination, chemomechanical preparation was completed, and calcium hydroxide was placed monthly for six months until the lesion showed signs of resolution. Irrigation was performed using NaOCl, 17% EDTA, and distilled water, combined with ultrasonic activation to enhance canal disinfection.

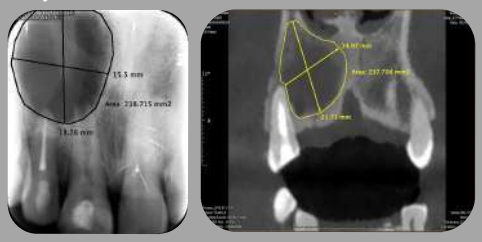

Fig 1. Preperative periapical x-ray CT views

In the final session, MTA was carefully placed into the apical third of the canal to act as an apical barrier. The remaining canal space was obturated using gutta-percha and resin-based sealer with lateral condensation, followed by a composite resin restoration.

At the 1-year follow-up, clinical symptoms had resolved, and radiographic evaluation confirmed continuing healing of the periapical lesion.



Fig 2. Postoperative periapical x-ray



Fig 3. 1 year follow-up

DISCUSSION

MTA's regenerative capacity is attributed not only to its physical sealing ability but also to its biological activity. Studies have shown that MTA induces mineralized tissue formation through osteoconduction. Additionally, ultrasonic activation of NaOCl has been demonstrated to significantly reduce microbial load and improve canal cleanliness, thus contributing to more favorable healing outcomes. In our case, the clinical protocol—combining MTA placement with calcium hydroxide therapy and ultrasonic irrigation—resulted in predictable healing, reinforcing the importance of multimodal disinfection strategies in endodontic management of immature teeth.

CLINICAL RELEVANCE

This case underscores MTA's effectiveness as a reliable apexification material in treating necrotic immature teeth with extensive periapical lesions. Its osteoconductive properties, biocompatibility, and sealing capabilities make it a superior alternative to calcium hydroxide. Incorporating ultrasonic activation during irrigation further optimizes disinfection and healing. Long-term follow-up remains essential to assess continued success and apical closure stability.

References

Guerrero, F., Mendoza, A., Ribas, D., & Aspiazu, K. (2018). Apexification: A systematic review. *Journal of Conservative Dentistry* 21(5), 462-465.

Patil, S., Hoshing, U., Kambale, S., & Gupta, R. (2017). Management of traumatised maxillary central incisor with immature open apex using mineral trioxide aggregate and tailor made gutta percha: a case report. *International Journal of Research in Medical Sciences* 5(3), 1151–1155.

Bücher, K., Meier, F., Diegritz, C., Kaaden, C., Hickel, R., & Kühnisch, J. (2016). Long-term outcome of MTA apexification in teeth with open apices. *Quintessence International* 47(6).

Simon, S., Rilliard, F., Berdal, A., & Machtou, P. (2007). The use of mineral trioxide aggregate in one-visit apexification treatment: a prospective study. *International endodontic journal* 40(3), 186-197.

Chotvorrarak, K., Danwittayakorn, S., Banomyong, D., & Suksaphar, W. (2024). Intraradicular reinforcement of traumatized immature anterior teeth after MTA apexification. *Dental Traumatology* 40(4), 389-397.

Saavedra Felipe, J. D., Watson Molina, V. A., Bologna Escalona, A., Laplana Martínez, R., Areso, A., Nagendrababu, V., & Abella Sans, F. (2024). Successful retreatment of a maxillary central incisor with a wide-open apex using MTA to fill the entire canal: 24-year follow-up. *Australian endodontic journal* 50(3), 700–708.

GE173 | DENTINE RADICULAR DEFECTS AFTER ROOT CANAL PREPARATION WITH DIFFERENT TECHNIQUES: AN IN VITRO STUDY

M. STAVILECI [1], A. KUÇI [2]

[1] *Department of Dental Pathology and Endodontics, University of Prishtina, Prishtina, KOSOVO*
[2] *Department of Dental Pathology and Endodontics, AAB College, Prishtina, KOSOVO*

AIM: The use of various root canal instruments during preparation may be associated with dentin radicular defects. So, the aim of this study was to evaluate and compare dentin radicular defects after root canal preparation with E-Flex Gold, E-Flex Blue and Wave One Gold files in human extracted molars.

Methodology: Forty extracted human molars were divided into four groups, according to root canal preparation technique: 1st group was prepared with E Flex Gold files, 2nd group with E-Flex Blue and 3rd with Wave One Gold files. Fourth group-control group was left unprepared. After preparations and root section in apical, middle and coronal sector, all samples were observed under stereomicroscope for cracks observation.

Results: There was no significant difference in dentin defects observation between the group instrumented with E-flex Gold and E-flex Blue files ($p>0.05$), and between two upper mentioned techniques compare to samples prepared with Wave One Gold files.

Conclusions (mandatory): All tested groups showed dentin defects. The samples instrumented with E-flex Gold showed more cracks than other groups in three sectors, but with no statistical significance.

GE 176 | Removing Separated Instruments with Kamand And A Hemostats

S. W. T. Al Hajaj[1], D. E. Özcan[2] and T. Y. Yalçin[3]
1: Istanbul University, Institute of Graduate Studies in Health Sciences, Istanbul, Turkey
2, 3: Istanbul University, Faculty of Dentistry, Department of Endodontics, Istanbul, Turkey

Aim: The aim of this poster is to show the efficiency of new separated instrument removal kit in retrieval of long separated instruments.

Introduction: The success of root canal treatment depends on many factors. Chemo-mechanical preparation of the canal is one of these factors. Separated instruments could be an obstacle of preparing the root canal system for obturation(1). Moreover eliminating the microorganisms from the canal system could be more difficult. That is why many different instruments and techniques are developed to remove these instruments. New removal kit by Dr. Slavi sh Moushekhian cooperated with Zumax (Suzhou, Jiangsu. China) has been developed, he claims that it can hold and remove long separated instruments without facing secondary fracture. In this case, KAMAND (Zumax, Suzhou, China) was used to remove a separated instruments with the aid of ultrasonic device.

Case Presentation: A healthy 34-year-old man was referred to Istanbul University Department of Endodontics. The patient had initiated a root canal treatment for the upper left second premolar in a private sector after breaking a rotary instrument. They tried to continue the cleaning and shaping with rotary instruments which ended up with another broken instrument (Fig.1). After application of local infiltrative anesthesia endodontic access cavity was achieved by removing the temporary filling and unsupported enamel. The two separated instruments were obvious at the level of the canal orifice (Fig.2). With the aid of magnification by ZUMAX SLH 6.0x Loupe (Zumax, Suzhou, China). The first separated instrument was removed easily by 5-inch V-Splinter Hemostats (Fig.3), the other was engaged into the dentin thus it was harder to remove it. KAMAND (Zumax, Suzhou, China) was used to remove the other seperated instrument as the loop was tieded around the file apically to broken area (Fig.4). Then the grip was controlled by lateral movement at first, while pulling the first wire was torned. The second wire was larger in diameter and it successfully pulled the separated file from the canal (Fig.5).
The working length was measured using Propex Pixi (Dentsply Sirona, Erlangen, Germany). Chemo-mechanical preparation was continued after successfully removing the instruments with VDW Rotate (VDW, Munich, Germany) up to 35.04 with continuous irrigation and activation by sonic activator EndoActivator (Dentsply Sirona, Erlangen, Germany). Master-cone periapical x-ray was taken (Fig.6). The root canal system was obturated by cold lateral condensation technique with AH+ sealer (Dentsply Sirona, Erlangen, Germany). The patient was referred to prosthodontic department in order to restore the tooth with indirect restoration.



Fig.1



Fig.2



Fig.3



Fig.4

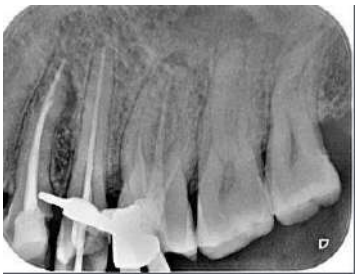

Fig.6



Fig.7



Fig.5

Discussion: In the last decade using Ni-Ti motor driven files had become a part of the standard armamentarium in endodontics (2). Unfortunately, it is theoretically impossible to create nonbreakable instruments because more flexible instruments, that are more resistant to cyclic fatigue, have been assumed to be less resistant to torsional load and vice versa(3).Thus, it is important to develop removing techniques and kits as well as to increase the awareness about the prevention of breaking the instruments. In case of facing such a complication as a health care providers we should aim to have a predictable results with minimum loses. As Dr. Theodor Lambrianidis suggests in his book(4) even no Intervention could be applicable in some cases. Moreover, Dr. Suter reported that the duration of the retrieval procedure is negatively correlated with the success rate of instrument retrieval(5). Even more the risk of perforation is increased if the intervention lasts more than 90 minutes(5). The retrieval process difficulty is affected by many factors; such as the length of the broken instrument, the type or the position in the root canal system. Bypassing the separated endodontic instrument may be the safest treatment in some cases(6,7). And it was believed that bypass is the first step to instrument retrieval(5). In the new guidelines, as it was stated by Dr. Michael Solomonov, it is preferred to try to retrieve the instrument first(1). Moreover, in this case, bypass was not an option due the length of the instruments and it was not believed that sufficient cleaning and shaping could be achieved while both instruments are in the canal. As in this case the visual of the separated instrument on the canal orifice make it easier to deal with them with less complications(8). And retrieving the instrument by griping is accepted worldwide(9). Since the loss of a longer instrument means a greater amount of dentin is removed (10), griping without complete loosening may be efficient, more conservative and this was the idea behind Kamand, as Dr. Moushekhian meantioned while presenting his new instrument.

Clinical relevance: Separated instrument is a nightmare for the practitioner as well as the patient, as the success of the root canal treatment i s affected directly. The patient was pleased that the instruments were retrieved in a short time. Moreover using KAMAND and Hemostat was considered to be the easiest way to the mentioned factors, as it is repeatable and applicable for such cases.

REFERENCES:
1:Terauchi Y, Ali WT, Abielhassan MM. Present status and future directions: Removal of fractured instruments. *International Endodontic Journal*, 55(Suppl. 3), 685–709. Available from: https://doi.org/10.1111/iej.13743
2:Averbach RE, Kleier DJ. Endodontics in the 21st century: the rotary revolution. Compend Contin Educ Dent 2001;22(1):27-34
3:Zhou HM, Shen Y, Zheng W, Li L, Zheng YF, Haapasalo M. Mechanical properties of controlled memory and superelastic nickel-titanium wires used in the manufacture of rotary endodontic instruments. Journal of endodontics. 2012 Nov 1;38(11):1535-40.
4:© Springer International Publishing AG 2018 T. Lambrianidis (ed.), Management of Fractured Endodontic Instruments, DOI 10.1007/978-3-319-60651-4_4
5:Suter, B., Lussi, A. & Sequeira, P. (2005) Probability of removing fractured instruments from root canals. International Endodontic Journal, 38.
6:Madarati AA, Hunter MJ, Dummer PMH. Management of intracanal separated instruments. J Endod, 2013;39:569-581
7:Lambrianidis T. Risk Management in Root Canal Treatment. Thessaloniki: University Studio Press; 2001.
8:Suter B. A new method for retrieving silver points and separated instruments from root canals. J Endod, 1998;24:446-448.
9:Ruddle CJ. Micro-endodontic nonsurgical retreatment. Dent Clin North Am 1997; 41:429–454.
10:Terauchi, Y., Sexton, C., Bakland, L.K. & Bogen, G. (2021) Factors affecting the removal time of separated instruments. Journal of Endodontics, 47, 1245–1252.

Consequences of neglecting the treatment protocol of the traumatized immature tooth – case report

GE177

Monika Z. Sitarz, prof. UM, PhD, DDS

Department of Conservative Dentistry with Endodontics
Medical University of Lublin, Poland

Aim

To present the consequences of traumatic injury of immature tooth, left without necessary treatment and follow-up care.

Introduction

Traumatic dental injuries during the development of permanent teeth can significantly disrupt subsequent developmental stages, affecting teeth, the supporting structures, alveolar bone and periodontium. Neglecting treatment protocols, including monitoring of vitality and radiographic assessment of the traumatized as well as timely intervention such as root canal therapy can lead to detrimental consequences. These may include developmental root disturbances, apical and/or lateral periodontitis, and external root resorption, with more severe cases resulting in tooth loss.

Case Presentation

12-year-old male patient visited the dental office due to pain complaints related to tooth 21. The patient had experienced a tooth injury four years prior, but no treatment was pursued. Clinical examination revealed chipping at the incisal edge, along with pain upon percussion and palpation in the root area. Radiographic examination showed incomplete root development with a widened root canal space, external cervical root resorption (ECR) with perforation, and apical and lateral periodontitis. Despite the uncertain prognosis and limited treatment options due to the patient's age, surgical closure of the perforation followed by antiseptic root canal treatment was performed.

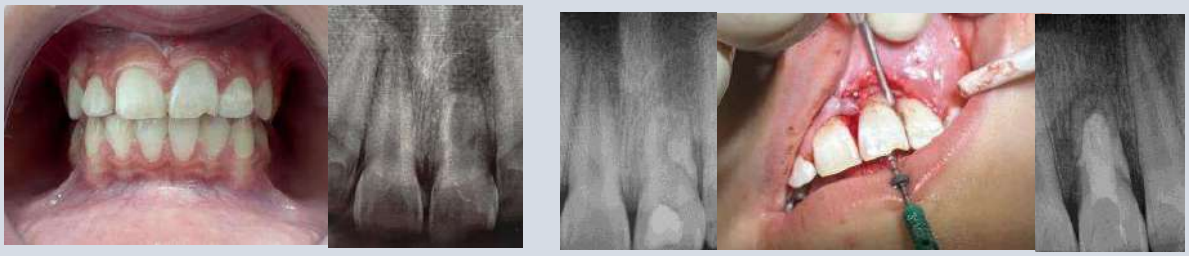

Fig. 1 Pre-operative & intra-operative



Fig. 2 After suture removal



Fig. 3 Recall 6 months &1 year respectivelly

Discussion

In this case, the traumatic injury halted proper root development, resulting in ECR, root perforation, and periodontal inflammation. However, six months and one year post-treatment, the patient remains free of complaints, clinical and radiographic examination showed periapical lesion healing.

Clinical Relevance

Preserving pulpal vitality in immature permanent teeth is paramount for continuous root development. The timing of the injury during root development is crucial for determining appropriate treatment strategies. Preservation of natural dentition is essential for the development of maxillary alveolar bone, as well as for function and aesthetics. Despite often uncertain prognoses, regular monitoring following traumatic injuries is imperative to assess and manage potential complications effectively.

References

1. Andreasen J.O., Andreasen F.M. (2007). Textbook and Color Atlas of Traumatic Injuries to the Teeth. 4th ed.
2. Gladwin L., Darcey J. (2023) The consequences of Dental trauma. *Prim Dent J.* 72-82.
3. Levin L., Day P.F., Hicks L., O'Connell A., Fouad A.F., Bourguignon C., Abbott P.V. (2020). International Association of Dental Traumatology guidelines for the management of traumatic dental injuries: General introduction. *Dent Traumatol*. 36(4):309-313.

GE178 | Innovative Strategies for Treating Non-Vital Permanent Teeth with Open Apex: Insights from a Case Series

B.DOUMARI[1], S. DHOUM[1],S. DROURI[1], M. JABRI[1]

1 Professor. Department of conservative dentistry- Endodontics, university Hassan II Faculty of Dentistry of Casablanca,Morocco.

INTRODUCTION

The endodontic treatment of teeth with open apex can be a challenge in daily practice. [1] Apexification is a treatment option that is done with the aim of apical repair by formation of hard tissue barrier through apex. Conventionally, a calcified barrier is inducted using a calcium hydroxide (CaOH2) mixture. Complete formation of the calcified apical barrier is usually lasts long, requiring 6 to 24 months of treatment time. Mineral trioxide aggregate (MTA) was described as an alternative to traditional apexification treatment[10] which incorporates the application of the material in the apical third of the canal to create an apical barrier . [2] The aim of this case report is to present endodontic treatment of a maxillary central incisor tooth with wide open apex and necrotic pulp using with MTA apical plug.

CLINICAL CASES

CASE N 1: A 19 year-old male referred by her general dental practitioner to the Department of Conservative dentistry-Endodontics CHU IBN ROCHD CCTD due to swelling related with the upper right central incisor. The patient reported that the tooth had been traumatized at 10 years old.



Preoperative clinical situation
- Mobility grade(1)
- Pain on percussion
- vitality test (-).

Pulp



Preoperative radiograph
Incomplete root development

TREATMENT PLAN

- Oral hygiene motivation and Periodontal treatment
- Endodontic treatment with Apexification (Apical plug with MTA)
- Prosthetic rehabilitation

PROTOCOL OF APEXIFICATION



Pre-endodontic restoration + Placement of the Rubber Dam



Determination of Working Length (WL)



Calcium Hydroxide



Radiograph for plugger calibration



3 mm thick of MTA® ➔ placed with a hand plugger of suitable size



Periapical radiograph showing gutta-percha cone.



Periapical radiograph showing obturation with gutta.



1 M Follow-up



3 M Follow-up



2years Follow-up



BEFORE



FINAL RESULAT

CASE N 2: A 25-year-old male presented with swelling and pain in relation with the right upper front teeth (Incisors and canine). The patient did not have any relevant medical history but reported previous trauma at a young age and previous endodontic treatment in the affected teeth by a another doctor prior without any relief.



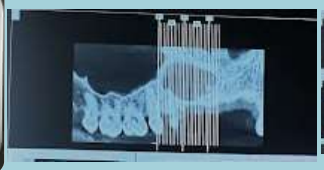



Preoperative clinical situation
-Mobility grade(1)
-Pain on percussion
-Vitality test (-).
-Large radiolucency measuring approximately 2.0 cm 1.5 cm involving upper right incisors and canine, with an open apex in central incisor and recent correct endodontic treatment for two other teeth (Treatment performed in our department).

TREATMENT PLAN

- Oral hygiene motivation and Periodontal treatment
- Endodontic treatment with Apexification (Apical plug with Biodentine)and vertical condensation.
- Enucleation of radicular cyst.

PROTOCOL OF APEXIFICATION



Placement of the Rubber Dam



Creation of access cavity



Determination of Working Length (WL)



Calcium Hydroxide



Radiograph for plugger calibration



3 mm thick of biodentine ➔ placed with a hand plugger of suitable size



Root canal obturation with vertical condensation



Periapical radiograph showing obturation with gutta.



Enucleation of radicular cyst



Sutures



anatomopathology results

DISCUSSION

Root canal development (3)

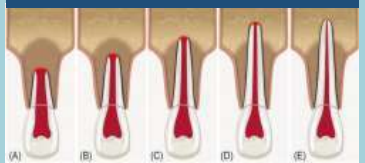

Schematic of Cvek's stages of root development. (A) *Group I*, < 1/2 root length; (B) *Group II*, 1/2 root length; (C) *Group III*, 2/3 root length; (D) *Group IV*, wide open apical foramen and nearly completed root length; (E) *Group V*, closed apical foramen and completed root development. Groups I, II and III shows wide and divergent apical openings.

CAUSES OF OPEN APICES (4,5)

1. **Incomplete root development**
   Pulpal necrosis arising as a result of caries or trauma).
2. **Both foraminal and peri-foraminal resorption of the root end**.
3. **Iatrogenic enlargement of the root end**
   Poor control of working length and subsequent enlargement with both hand and rotary files.

TYPES OF OPEN APICE (5)

Open Apice

Blunderbuss	Non-blunderbuss
The walls of the canal are divergent and flaring, the apex is funnel shaped and typically wider than the coronal aspect of the canal.	The walls of the canal may be parallel to slightly convergent. The apex, therefore can be broad shaped or convergent.

MTA Vs biodentine® (6,7)

The survival rates of 95% for trauma-related and 70% for non-trauma-related treatments in this study(Ref) fall within the range of recently published survival rates for apexification treatments with MTA.
In another study (ref), there were no statistically significant differences in the clinical and radiographic outcomes of immature mandibular first molars that received MTA or Biodentine® apical plugs. No cases showed failure of treatment.

CLINICAL RELEVANCE

The management of non-vital permanent teeth with wide open apices is challenging due to the lack of an apical stop. The apical barrier technique using MTA or Biodentine® is now the preferred approach, promoting periapical healing and providing a reliable seal. In cases with short root lengths, the entire canal can be filled with bioactive material to enhance structural support. This technique improves treatment outcomes by reinforcing the root and facilitating continued healing. The choice between MTA and

REFERENCES



PARIS

CHALLENGES, OPPORTUNITIES AND NEW PERSPECTIVES IN ENDODONTOLOGY

3-6 SEPTEMBER 2025

ese