Unilateral pulmonary agenesis associated with colloidal goiter in a newborn: a case report

Güzide Ayşe Gökhan[1], Gülay Özbilim[1], Sevgi Bozova[1], Aşkın Güra[2]
Hakan Ongun[2], Ercan Mıhcı[2], Gökhan Arslan[3]
Departments of [1]Pathology, [2]Pediatrics, and [3]Radiology, Akdeniz University Faculty of Medicine, Antalya, Turkey

SUMMARY: Gökhan GA, Özbilim G, Bozova S, Güra A, Ongun H, Mıhcı E, Arslan G. Unilateral pulmonary agenesis associated with colloidal goiter in a newborn: a case report. Turk J Pediatr 2005; 47: 295-297.

Unilateral pulmonary agenesis is a very rare developmental malformation that is often associated with other anomalies. It can be asymptomatic or present with respiratory symptoms. Our case is a female newborn infant who had been taken to the hospital suffering from difficulty in breathing at the first day of birth. The baby died at the age of three days due to respiratory failure. On autopsy examination and its histopathological evaluation, we detected right pulmonary agenesis and colloidal goiter. According to the literature, pulmonary agenesis is associated with other anomalies including esophageal atresia, tracheal stenosis, musculoskeletal anomalies, DiGeorge syndrome and cardiovascular malformations such as septal defects, patent ductus arteriosus and total anomalous pulmonary venous return. To our knowledge, this is the first case of pulmonary agenesis associated with colloidal goiter.

Key words: pulmonary agenesis, colloidal goiter.

Pulmonary agenesis implies absence of a lung and its supporting vasculature, whereas the main bronchi may be either absent or hypoplastic[1]. Bilateral pulmonary agenesis is quite rare and incompatible with life. Unilateral agenesis of the lung is a more common entity; although it is often associated with other anomalies, it may be compatible with essentially normal life[2].

According to the literature, anomalies that can be associated with unilateral pulmonary agenesis are esophageal atresia, tracheoesophageal fistula, tracheal stenosis, musculoskeletal anomalies, patent ductus arteriosus and total anomalous pulmonary venous return[1,3-8]. To our knowledge, we report the first case of a female newborn infant with right pulmonary agenesis associated with colloidal goiter.

Case Report

A 2970 g female newborn was referred on her first day of life from an outside hospital because of respiratory distress. She was born by cesarean section to a 26-year-old gravida 2, para 2 mother. The mother had no significant past or obstetric history. The parents were first-degree relatives. There was no family history of any congenital anomalies. The mother did not use any drugs during her pregnancy.

On admission, the baby was cyanotic with a respiratory rate of 66/minute with chest retractions. There was absence of breath sounds in the entire right hemithorax. She was entubated and put on mechanical ventilation. Difficulty was detected while inserting the endotracheal tube towards the trachea. Her hematologic and other blood parameters were all normal. Posterior-anterior chest X-ray showed opaque right hemithorax with slight cardiac displacement, left lung hyperinflation and minimal intercostal narrowing on the right side (Fig. 1).

The baby had severe respiratory distress and her arterial blood gas analysis showed respiratory acidosis. She was treated with one dose of surfactant but no difference was detected on

This article was presented as a poster in the 17th Asia Pacific Congress on Diseases of the Chest, Istanbul, Turkey, 2003

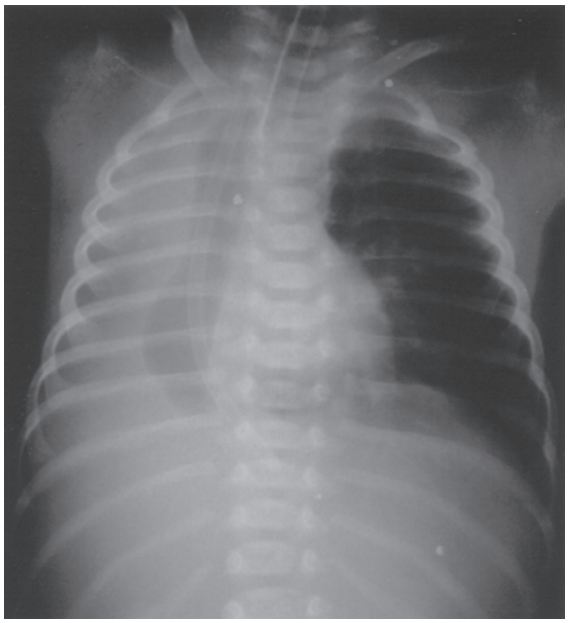

Fig. 1. Posterior-anterior chest X-ray shows opaque right hemithorax. Note the left lung. hyperinflation and slight cardiac displacement.

chest radiographs obtained after two and six hours of surfactant administration (not shown). The baby's condition deteriorated despite an increase in respiratory settings and use of vasodilators, and she died on the 38th hour of admittance.

On autopsy examination, we detected right pulmonary agenesis with its vasculature (Fig. 2). At the level of the tracheal bifurcation, there was no branching of the right main bronchus, therefore the trachea was extending directly to the left main bronchus (Fig. 3). The left lung had two lobes and was in normal range for weight. There were no other left lung, cardiac or other organ anomalies. The volume and size of the thyroid gland were increased, with a weight of 1 g and measuring 2.2 x 1.5 x 0.4 cm.

On microscopic examination, we detected histopathological findings compatible with immaturity and hypoxia, especially in the kidneys, liver and left lung. Additionally, observation of the thyroid gland showed variable size of follicles filled with colloid in incomplete nodular architecture (Fig. 4).

Our comment on the cause of death was multisystem inefficiency due to respiratory failure.

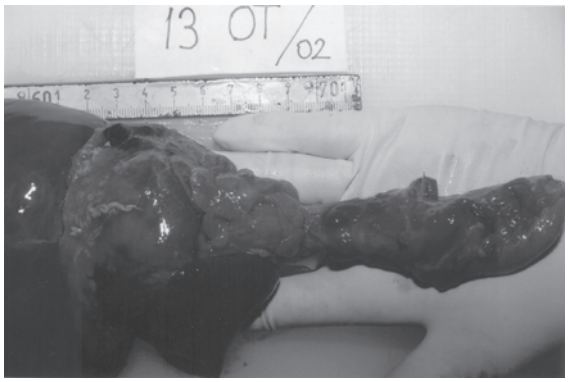

Fig. 2. Right lung agenesis, anterior aspect.



Fig. 3. On the side of the agenesis, there is no branching of main bronchus, posterior aspect.

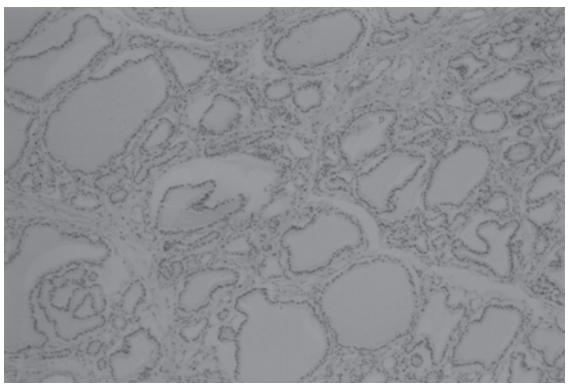

Fig. 4. Variable size of follicles filled with colloid in the thyroid gland, H&E X 100.

Discussion

The incidence of unilateral pulmonary agenesis is only one in every 10,000 to 15,000 autopsies. Congenital deficiency of the unilateral lung is believed to be caused by failure to maintain the developmental balance between the two lung buds[3].

There is a 1.3:1 female predominance with unilateral agenesis. Agenesis of the left lung appears to occur more frequently and the prognosis is generally regarded as worse for patients with agenesis on the right[2]. Our patient was female and her right lung was absent.

The larynx and upper trachea are usually normal in unilateral pulmonary agenesis. The lower trachea in unilateral pulmonary agenesis may continue directly into the existing lung as a tracheobronchus or it may bifurcate at the carina, giving rise to a rudimentary, blind-ending bronchus on the side of the agenesis.

The pulmonary artery and vein to the side of the agenesis are absent or hypoplastic[2]. In our case, there was no evidence of the vasculature and main bronchus on the side of the agenesis.

Extrapulmonary anomalies, as mentioned above, are frequently associated with pulmonary agenesis and worsen the prognosis, but even without other anomalies, children with isolated pulmonary agenesis have a shorter life expectancy than normal children, rarely surviving past their first decade.

In the newborn, colloidal goiter may result from biosynthetic defects in thyroid hormone synthesis and from maternal causes such as iodine deficiency during fetal development and antithyroid drug uptake during pregnancy. The four major biosynthetic defects in thyroid hormone synthesis are iodide transport defect, organification defect, dehalogenase defect and iodotyrosine coupling defect[9].

Our case died in her 38th hour of life because of respiratory problems. The baby had colloidal goiter in addition to right pulmonary agenesis. Her mother did not use any drugs and had no detectable endocrine organ disorders. We thus explain the etiology of the colloidal goiter as a possible biosynthetic defect in thyroid hormone synthesis.

We report the case as an incidental association. To our knowledge, it is the first such case of pulmonary agenesis associated with colloidal goiter.

REFERENCES

1 Finci V, Beghetti M, Kalangos A, Bründler MA. Unilateral total and contralateral partial pulmonary agenesis associated with total anomalous pulmonary venous drainage. J Pediatr 1999; 134: 510-512.

2 Wigglesworth JS, Singer DB. Textbook of Fetal and Perinatal Pathology, Vol. 2. London: Blackwell Scentific Publication; 1991: 649.

3 Kitagawa H, Nakada K, Fujioka T, et al. Unilateral pulmonary agenesis with tracheaoesopagheal fistula: a case report. J Pediatr Surgery 1995; 30: 1523-1525.

4 Aggarwal AN, Gupta D, Jindal SK. Unilateral pulmonary agenesis with ipsilateral musculoskeletal anomalies. J Assoc Physicians India 2002; 50: 1324-1326.

5 Chen CY, Tsao PN, Chou HC, Chen SJ, Tsou KI. Esophageal atresia associated with tracheal stenosis and right lung agenesis: report of one case. Acta Pediatr Taiwan 2002; 43: 348-350.

6 Weber TR, Connors RH, Tracy TF Jr. Congenital tracheal stenosis with unilateral pulmonary agenesis. Ann Surg 1991; 213: 70-74.

7 Steadland KM, Langham MR Jr, Greene MA, Bagwell CE, Kays DW, Talbert JL. Unilateral pulmonary agenesis, esophageal atresia, and distal tracheoesophageal fistula. Ann Thorac Surg 1995; 59: 511-513.

8 Hoffman MA, Superina R, Wesson DE. Unilateral pulmonary agenesis with esophageal atresia and distal tracheoesophageal fistula: report of two cases. J Pediatr Surg 1989; 24: 1084-1085.

9 Cotran RS, Kumar V, Robbins SL. Pathologic Basis of Disease. Pennsylvania: W.B. Saunders Company; 1994: 1131.



ISSN 0041 - 4301

THE TURKISH JOURNAL OF PEDIATRICS

CONTENTS

ORIGINAL ARTICLES

203 Overcoming Difficulties in Implementing a Universal Newborn Hearing Screening Program
S. Korres, D.G. Balatsouras, S. Vlachou I.G. Kastanioudakis, N.V. Ziavra, E. Ferekidis

213 Identification of an Ancestral Haplotype of the 35delG mutation in the GJB2 (Connexin 26) Gene Responsible for Autosomal Recessive Non-syndromic Hearing Loss in Families from the Eastern Black Sea Region in Turkey
B. Balcı, F. Özbaş-Gerçeker, S. Aksoy, G. Sennaroğlu E. Kalay, L. Sennaroğlu, P. Dinçer

222 The First Asthma Camps in Turkey for Asthmatic Children: Six Years' Experience
Ü. Öneş, N. Sapan, M. Yazıcıoğlu, N. Güler, Z. Tamay A. Somer, Y. Canıtez

227 Use of Polymerase Chain Reaction for Detection of Adenovirus in Children with or without Wheezing
C. Saçkesen, A. Pınar, B.E. Şekerel, Y. Akyön, Y. Saraçlar

232 Prenatal Echocardiographic Diagnosis of Congenital Heart Disease: Comparison of Past and Current Results
S. Özkutlu, C. Ayabakan, T. Karagöz, L. Önderoğlu Ö. Deren, M. Çağlar, Ş. Güçer

239 The Efficacy of Immunoglobulin Replacement Therapy in the Long-term Follow-up of the B-cell Deficiencies
B. Bayrakçı, F. Ersoy, Ö. Sanal, Ş. Kılıç A. Metin, İ. Tezcan

247 Spontaneous Closure of Small Apical Muscular Ventricular Septal Defects
S. Atalay, E. Tutar, F. Ekici, N. Naçar

251 Neutrophil Hypersegmentation and Thrombocytosis in Children with Iron Deficiency Anemia
S. Düzgün, Y. Yıldırmak, F. Çetinkaya

255 Familial Ureteroceles: An Evidence for Genetic Background?
S. Sözübir, D. Ewalt, W. Strand, L.A. Baker

volume 47
number 3
july - september 2005

261 The Contribution to Success of Various Methods of Treatment of Temporomandibular Joint Ankylosis
R. Tanrıkulu, B. Erol, B. Görgün, M. Söker

CASE REPORTS

266 A Very Rare Cause of Recurrent Apnea: Congenital Nasopharyngeal Teratoma
Z. Ülger, A. Egemen, B. Karapınar, A. Veral, F. Apaydın

270 Autoimmune Thrombocytopenic Purpura After Mumps Infection
Ş. Ünal, S. Yetgin, A. Kara, G. Kanra

272 *Brucella melitensis* in Blood Cultures of two Newborns due to the Exchange Transfusion
M. Akçakuş, D. Esel, N. Çetin, A. Paç-Kısaarslan, S. Kurtoğlu

275 Startle Disease: Two Sibling Cases
M. Elkay, F. İncecik, M.Ö. Hergüner, G. Leblebisatan, Ş. Altunbaşak

279 Catheter-associated Recurrent Intracardiac Thrombosis and Factor V Leiden Mutation in a Child with Non-Hodgkin's Lymphoma
F. Çorapçıoğlu, K. Mutafoğlu-Uysal, E. Silistreli, N. Ünal H. Ören, Ü. Açıkel

283 Spontaneous Rupture of Choledochal Cyst Presenting in Childhood
D. Aydoğdu-Kiresi, A. Karabacakoğlu, A. Dilsia, S. Karaköse

287 Brain Calcification due to Secondary Hyperparathyroidism in a Child with Chronic Renal Failure
I. Bilge, B. Sadıkoğlu, S. Emre, A. Şirin, B. Tatlı

291 A Case of Double Outlet Left Ventricle with Atrioventricular Discordance
C. Ayabakan, F. Akalın

295 Unilateral Pulmonary Agenesis Associated with Colloidal Goiter in a Newborn: A Case Report
G.A. Gökhan, G. Özbilim, S. Bozova, A. Güra, H. Ongun E. Mıhcı, G. Arslan

298 The Triad of Nesidioblastosis, Congenital Neuroblastoma, and Glomerulocystic Disease of the Newborn: A Case Report
A. Bulun, S.Ü. Sarıcı, Ö. Uysal-Soyer, Ö. Tekşam M. Yurdakök, M. Çağlar

303 ANNOUNCEMENTS

Printed by METEKSAN in Ankara, Turkey



THE TURKISH JOURNAL OF PEDIATRICS

HONORARY EDITOR
İhsan DOĞRAMACI

EDITOR
Turgay COŞKUN

ASSOCIATE EDITOR
Murat YURDAKÖK

MANAGING EDITORS
Turgay COŞKUN
Murat YURDAKÖK
Corinne CAN

ADMINISTRATOR
Murat TUNCER

CHIEF, DOCUMENTATION AND PUBLICATIONS
Phyllis Lepon ERDOĞAN

PUBLISHED BY
Turkish National Pediatric Society,
Hacettepe University
Institute of Child Health and
The Turkish and International
Children's Center

PRINTED IN
Meteksan Anonim Şirketi, Ankara

ISSN 0010-0161

EDITORIAL BOARD
Betül ACUNAS, Edirne
B. Tamara AJDAROVA, Ashkabad
Arif AKŞİT, Denizli
Handan ALP, Erzurum
N. Adile AVAZKIZI, Baku
Denizmen AYGÜN, Elazığ
Ayşın BAKKALOĞLU, Ankara
Münevver BERTAN, Ankara
Yavuz COŞKUN, Gaziantep
Sevinç EMRE, İstanbul
İbrahim ERKUL, Konya
Yusuf GEDİK, Trabzon
Ayşe S. GÖKALP, Kocaeli
Asım GÜLTEKİN, Sivas
Seval GÜNEŞER, Adana
Ayfer GÜR-GÜVEN, Antalya
Enver HASANOĞLU, Ankara
Akgün HİÇSÖNMEZ, Ankara
İbrahim ILDIRIM, Bursa
Gülten İNAN, Aydın
Kenan KOCABAY, Bolu
Ahmet KOÇ, Şanlıurfa
Duyshe KUDAYAROV, Bishkek
Nurdan KURAL, Eskişehir
Şükrü KÜÇÜKÖDÜK, Samsun
Nilgün KÜLTÜRSAY, İzmir
Dursun ODABAŞ, Van
Ali ONAĞ, Manisa
Olcay ORAN, Ankara
Kemal ORMANTAEV, Almaty
Ahmet R. ÖRMECİ, Isparta
İmran ÖZALP, Ankara
Şinasi ÖZSOYLU, Ankara
Ayşenur PAÇ, Malatya
Türkan PATIROĞLU, Kayseri
M. Orhan SRADJITDINOVITCH, Tashkent
Cahit TANYEL, Ankara
Mehmet A. TAŞ, Diyarbakır
Keriman TINAZTEPE, Ankara
A. Murat TUNCER, Ankara
Ergül TUNÇBİLEK, Ankara
Olcay YEĞİN, Antalya

This publication is included in the abstracting and indexing coverage of BIOSIS Previews, CAB Abstracts (Abstracts on Hygiene and Communicable Diseases, Public Health Bulletin, Tropical Diseases Bulletin), EMBASE/Excerpta Medica, IBIDS (International Bibliographic Information on Dietary Supplements), MEDLINE/Index Medicus, MICROMEDEX for Health Care Series, Research Alert Direct (ISI), Science Citation Index Expanded (ISI), SERLINE and Turkish Medical Index.

EDITORIAL OFFICE
Prof. Dr. Turgay Coşkun
Editor
The Turkish Journal of Pediatrics
P.K. 66, Samanpazarı
06240 Ankara, Turkey
Fax: 90 (312) 324 32 84

SUBSCRIPTION ADDRESS
Prof. Dr. A. Murat Tuncer
Director
Hacettepe University
Institute of Child Health
06100 Ankara, Turkey
Fax: 90 (312) 324 32 84

Master Journal List JOURNAL LIST

Search terms: *TURKISH JOURNAL OF PEDIATRICS
Total journals found: 1

1. TURKISH JOURNAL OF PEDIATRICS
Bimonthly
ISSN: 0041-4301
E-ISSN: 0041-4301
TURKISH J PEDIATRICS, P K 66 SAMANPAZARI, ANKARA, TURKEY, 06240

1. Science Citation Index Expanded

1 result from Web of Science Core Collection for:

Unilateral pulmonary agenesis associated with colloidal goiter in a newborn: a case report (All ...

Analyze Results Citation Report Create Alert

Copy query link

Publications You may also like...

Refine results

Search within topic...

Filter by Marked List

Quick Filters

None of the results contain data in this field.

Publication Years

2005 1

Document Types

Article 1

Web of Science Categories

Pediatrics 1

Authors

Arslan G 1
Bozova S 1
Gokhan GA 1
Gura A 1
Mihci E 1

See all >

Affiliations

AKDENIZ UNIVERSITY 1

Publication Titles

TURKISH JOURNAL OF PEDIATRICS 1

Publishers

0/1 Add To Marked List Export Sort by: Relevance 1 of 1

1 Unilateral pulmonary agenesis associated with colloidal goiter in a newborn: a case report

Gokhan, GA; Ozbilim, G; (...); Arslan, G

Jul-sep 2005 | TURKISH JOURNAL OF PEDIATRICS 47 (3) , pp.295-297

5 Citations

9 References

Related records

TURKISH JOURNAL OF PEDIATRICS

Journal Impact Factor ™

2021	Five Year
0.716	0.823

JCR Category	Category Rank	Category Quartile
PEDIATRICS *in SCIE edition*	124/130	Q4

Source: Journal Citation Reports ™ 2021

Page size 1 of 1

1 record match

Publishers

- [ ] Turkish J Pediatrics 1

Funding Agencies

Open Access

Editorial Notices

Editors

Group Authors

Research Areas

Countries/Regions

Languages

Conference Titles

Book Series Titles

Web of Science Index

For more options, use Analyze Results

© 2022 Clarivate
Training Portal
Product Support

Data Correction
Privacy Statement
Newsletter

Copyright Notice
Cookie Policy
Terms of Use

Tanımlama Bilgisi Ayarları

Follow Us